

Case Report

Autologous Bone Marrow Mesenchymal Stem Cells Implantation for Cartilage Defects: Two Cases Report

Channarong Kasemkijwattana MD*, Suradej Hongeng MD**,
Suraphol Kesprayura MD***, Visit Rungsinaporn MD*,
Kanda Chaipinyo PhD****, Kosum Chansiri PhD*****

* Department of Orthopedics, Faculty of Medicine, HRH Princess Maha Chakri Sirindhorn Medical Center, Srinakhrinwirot University, Nakhon Nayok, Thailand

** Department of Pediatrics, Ramathibodi Hospital, Mahidol University, Bangkok, Thailand

*** Department of Orthopedics, Police General Hospital, Bangkok, Thailand

**** Faculty of Health Science, Srinakhrinwirot University, Nakhon Nayok, Thailand

***** Department of Biochemistry, Faculty of Medicine, Srinakhrinwirot University, Nakhon Nayok, Thailand

Objective: The authors reported the results of autologous bone marrow mesenchymal stem cells (BM-MSCs) implantation in two patients with large traumatic cartilage defects of the knee.

Material and Method: Two patients with grade 3-4 according to the International Cartilage Repair Society Classification System were performed autologous bone marrow mesenchymal stem cells (BM-MSCs) implantation on December 2007 and January 2008. The bone marrow aspiration was performed in the outpatient visit under local anesthesia and sent to the laboratory for BM-MSCs isolation and expansion. The BM-MSCs were re-implanted into the defects with the three-dimensional collagen scaffold. The patients were clinical evaluated preoperatively and postoperatively with Knee and Osteoarthritis Outcome Score (KOOS), International Knee Documentation Committee Score (IKDC Score) and arthroscopic examination. The duration of follow-up was 30-31 months.

Results: There was no postoperative complication. The clinical evaluation with Knee and Osteoarthritis Outcome Score (KOOS) and International Knee Documentation Committee Score (IKDC Score) showed significant improvement. The arthroscopic assessment showed the good defect fill, stiffness and incorporation to the adjacent cartilage.

Conclusion: The autologous bone marrow mesenchymal stem cells implantation showed the potential for the treatment of large cartilage defects. The one-stage procedure is the advantage over the conventional autologous chondrocytes implantation. The long-term follow-up with long last hyaline-like cartilage is required.

Keywords: Knee injury, Bone marrow mesenchymal stem cells, Cartilage defects

J Med Assoc Thai 2011; 94 (3): 395-400

Full text. e-Journal: <http://www.mat.or.th/journal>

Articular cartilage consists of relatively few cells with low mitotic activity^(1,2). The poor self-repair of the cartilage will progress to osteoarthritis. The conventional procedures (abrasive chondroplasty, subchondral drilling, microfracture and mosaicplasty) are limited to the small defects^(3,4). The autologous chondrocytes implantation (ACI) had been developed using the expanded autologous chondrocytes to

re-transplant into the cartilage defects^(5,6). The ACI consists of two procedures. First, the cartilage is arthroscopic harvested and the chondrocytes are isolated and cultured in the laboratory. The three to four weeks is needed to have the adequate number of cells.

Second, the chondrocytes are re-implanted into the defects⁽⁷⁻¹⁰⁾. The present study showed ACI had the potential to provide the hyaline-like cartilage over the conventional procedures^(11,12). However, the disadvantages of ACI are limitation in the number of chondrocytes and the requirement of two-stage procedure.

Bone marrow (BM) mesenchymal stem cells (MSCs) are multipotent, being capable of forming

Correspondence to:

Kasemkijwattana C, Department of Orthopedics, Faculty of Medicine, HRH Princess Maha Chakri Sirindhorn Medical Center, Srinakhrinwirot University, Nakhon Nayok 26120, Thailand.

Phone: 037-395-085

E-mail: chann@swu.ac.th

bone, cartilage and other connective tissue⁽¹³⁾. The BM-MSCs have high proliferation capacity and can be differentiated to chondrocytes^(14,15). The present study showed hyaline cartilage formation in the animal model⁽¹⁶⁻¹⁸⁾ and in a clinical trial⁽¹⁹⁾. The BM-MSCs have the high potential to be the cell source for cartilage repair procedure with single-stage procedure.

The purpose of the current study was to evaluate the results of autologous BM-MSCs implantation using clinical evaluation and arthroscopic assessment.

Material and Method

Patients

Two patients were had autologous BM-MSCs implantation performed in December 2007 and January 2008; both had lateral femoral condyle lesions. The cartilage defects had grade 3-4 according to ICRS (International Cartilage Repair Society) Classification System^(12,13). The duration of follow-up was 30 and 31 months. The mal-alignment, ligament laxity, other pathology needed to be corrected before. All consented for the autologous BM-MSCs implantation under the Ethics Committee regulation.

The autologous BM-MSCs implantation consists of two-stage procedure. First, the BM was aspiration from anterior iliac crest under local anesthesia. The BM-MSCs were isolated and expanded in the laboratory. Second, the BM-MSCs were re-implanted into the cartilage defects.

BM-MSCs harvest and isolation

Heparinized bone marrow (BM) samples were obtained by aspiration from anterior iliac crest under local anesthesia and transferred to the laboratory at ambient temperature. Bone marrow mononuclear cells (BMMC) were separated by density gradient centrifugation with 1.073 g/ml Percoll solution (Sigma, MO, USA). Briefly, 10 ml of heparinized bone marrow cells were mixed in an equal volume of Dulbecco's

Modified Eagle's Medium (DMEM) (BioWhittaker, USA) and centrifuged at 900 g for 10 min at room temperature. The washed cells were re-suspended in DMEM at density of 4×10^7 cells/ml and 5 ml aliquot was layered over 1.073 g/ml Percoll solution and centrifuged at 1,000 g for 30 min at room temperature. The interface mononuclear cells were collected and washed twice with DMEM. Total cell count and viability were evaluated by 0.2% Trypan blue exclusion. A total of 12×10^6 cells/ml of BMMC were cultured in DMEM complete medium supplemented with 10% fetal bovine serum (FBS) (Gibco BRL, NY, USA) and 1% Penicillin-Streptomycin (Gibco BRL) at 37°C, 5% CO₂ in CO₂ incubator. On day 3 of cultivation, non-adherent cells were discarded and this process was repeated every 4 days. Upon 90% confluent, MSCs were trypsinized by 0.05% trypsin (Gibco BRL) and passaged for expansion (Fig. 1)⁽¹⁹⁾. The quality-control procedures consist of sterility testing and photographic recording of cell morphology. The 3-4

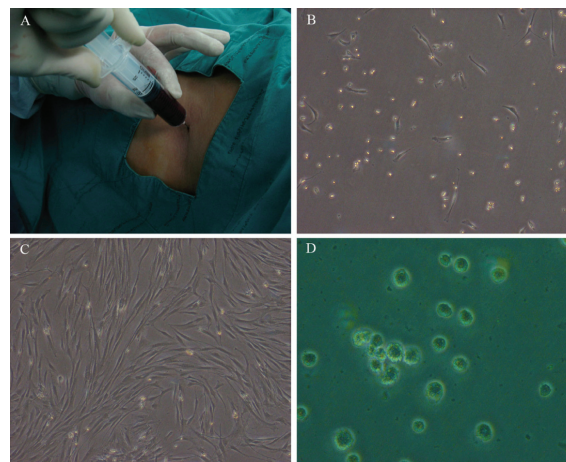


Fig. 1 Bone marrow aspiration (A), BM-MSCs isolation (B) and at 3 weeks (C), BM-MSCs in three-dimensional collagen scaffold (D)

Table 1. Demographic data on the patients

Case	Gender, age	Side	Cartilage lesion		Operation
			Site	Size (cm ²)	
1	M, 24	L	Lateral condyle	2.5	Double-bundle ACL reconstruction lateral meniscus repair, autologous BM-MSCs implantation
2	M, 25	L	Lateral condyle	2.2	ACL reconstruction, autologous BM-MSCs implantation

weeks incubation was needed to obtain an adequate number of MSCs for implantation.

BM-MSCs implantation

The BM-MSCs were seeded in the atelocollagen (type I collagen, Koken) which is the three-dimensional collagen scaffolds. The grafts were sized and shaped according to the defects. The knee arthrotomy was performed. The chondral lesion was debrided to the healthy cartilage. The subchondral bone plate must be carefully preserved. The grafts were fixed to the defect using fibrin glue. The periosteal graft was harvested from the anteromedial incision of proximal tibia. The periosteum graft was sutured with interrupt suture (Prolene 6-0) to the chondral defect facing the defect with the cambium layer. The fibrin glue was used to make to water-seal pocket. The wound was closed layer by layer and the compression dressing was applied.

Post-operative program

The pain control with intravenous analgesic and NSAIDs were performed. The isometric exercise was started immediately on the post operative day. The hinge brace at full extension and non-weight bearing were required for two weeks. The progressive weight bearing, active knee flexion and quadriceps/hamstrings strengthening exercises were encouraged as tolerate after 2 weeks. The patients had full range of motion at 3 months. The progressive weight training was encouraged. Running was restricted for 9 months.

Clinical evaluation

The duration of follow-up was 30-31 months. The patients were clinical evaluated preoperatively and postoperatively with International Knee Documentation Committee Score (IKDC Score), Knee and Osteoarthritis Outcome Score (KOOS) including pain, symptoms, function in daily living (ADL), function in sports and recreation, knee-related quality of life⁽²⁰⁾; and arthroscopic examination. The case reports were presented with preoperative and postoperative (at 30-31 months of follow-up) IKDC and KOOS respectively.

Results

The patients had no post-operative complication. The evaluation using the International Knee Documentation Committee Score (IKDC Score) and KOOS showed excellent clinical improvement at the time of 30-31 months follow-up (Table 2, 3).

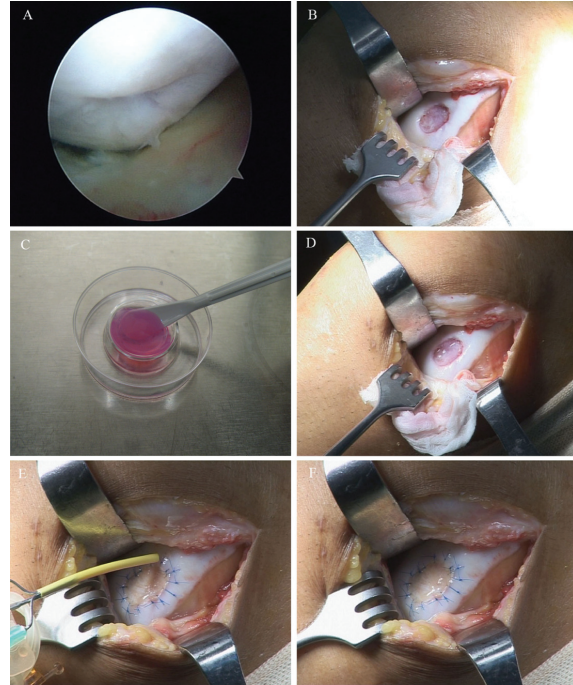


Fig. 2 Arthroscopic finding of the lesion (A), debride lesion to healthy rim (B), three-dimensional collagen scaffold seeded with BM-MSCs (C), fix into the defect with fibrin glue (D), suture periosteal graft over the lesion and seal with fibrin glue (E, F)

The arthroscopic assessment showed the good defect fill, stiffness, and incorporation to the adjacent cartilage (Fig. 3).

Discussion

The ACI using expanded chondrocytes has been shown the promising results in the treatment of large cartilage defects over the conventional procedures^(6,11). However, the expanded chondrocytes have the limited chondrogenesis to achieve hyaline-cartilage from limited cell number for implantation⁽¹⁶⁾. The BM-MSCs are capable of self-renewal and differentiation to chondrocytes in the certain micro-environment⁽¹³⁾. The injured tissues induce the BM-MSCs to deliver trophic factors and differentiate to chondrocytes with “homing effect^(14,15)”. The BM-MSCs have shown the high potential as the cell sources for implantation with the same excellent clinical results compared to chondrocytes *in vitro* and *in vivo*^(18,19,21). The histology showed hyaline-like cartilage with abundant extracellular matrices⁽¹⁹⁾. The results were even better than chondrocytes in the older patient. The aging affects chondrogenesis of

Table 2. International Knee Documentation Committee Score (IKDC Score)

Case	Preoperative	Postoperative*
1	21	74
2	37	94

* At 30-31 months follow-up

Table 3. Knee and Osteoarthritis Outcome Score (KOOS)

Case		Preoperative	Postoperative*
1	Symptoms	39	89
	Pain	39	92
	ADL	30	62
	Sports	24	75
	QOL	31	75
2	Symptoms	36	100
	Pain	36	100
	ADL	32	100
	Sports	20	100
	QOL	31	94

*At 30-31 months follow-up

ADL = function in daily living

QOL = quality of life

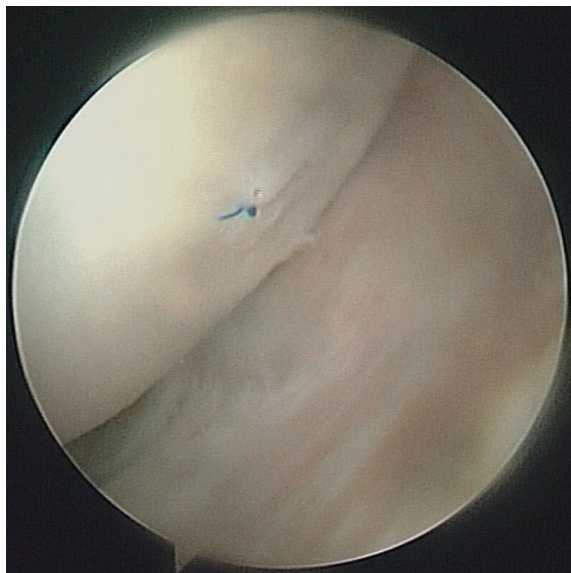


Fig. 3 The arthroscopic examination at 1 year after BM-MSCs implantation

chondrocytes, but it seems to have less effect to BM-MSCs⁽²¹⁾.

The present study showed the excellent clinical results and arthroscopic finding in the large defects at 30-31 months follow-up. The histologic study of the regenerative tissue could not be done regarding the patient's unwillingness. The other advantage of BM-MSCs is easy to obtain. The bone marrow aspiration can be done with the minimal invasive local anesthesia in the outpatient clinic. The patient satisfaction is high compared to the two-stage surgery of the conventional ACI.

However, the long term follow-up will be required. The BM-MSCs are multipotent, being capable of forming many connective tissues. The certain microenvironment which promote chondrogenesis differentiation and subsequent by maintain cartilaginous phenotype is required for further investigation. The biomaterial is another crucial factor for tissue-engineering. The BM-MSCs could be the alternative cell sources for cartilage regeneration procedure to provide superior biologic hyaline-cartilage in the large cartilage defects.

Potential conflicts of interest

This study was granted by Thailand Research Fund.

References

1. Mankin HJ. The response of articular cartilage to mechanical injury. *J Bone Joint Surg Am* 1982; 64: 460-6.
2. Shelbourne KD, Jari S, Gray T. Outcome of untreated traumatic articular cartilage defects of the knee: a natural history study. *J Bone Joint Surg Am* 2003; 85-A (Suppl 2): 8-16.
3. O'Driscoll SW. The healing and regeneration of articular cartilage. *J Bone Joint Surg Am* 1998; 80: 1795-812.
4. Nehrer S, Spector M, Minas T. Histologic analysis of tissue after failed cartilage repair procedures. *Clin Orthop Relat Res* 1999; 149-62.
5. Brittberg M, Lindahl A, Nilsson A, Ohlsson C, Isaksson O, Peterson L. Treatment of deep cartilage defects in the knee with autologous chondrocyte transplantation. *N Engl J Med* 1994; 331: 889-95.
6. Peterson L, Minas T, Brittberg M, Lindahl A. Treatment of osteochondritis dissecans of the knee with autologous chondrocyte transplantation: results at two to ten years. *J Bone Joint Surg Am*

- 2003; 85-A (Suppl 2): 17-24.
7. Chanlalit C, Kasemkijwattanamd C, Varavit V. Autologous chondrocyte implantation for traumatic large cartilage defect. *J Med Assoc Thai* 2007; 90: 1435-42.
 8. Kasemkijwattana C, Kesprayura S, Chaipinyo K, Chanlalit C, Chansiri K. Autologous chondrocytes implantation for traumatic cartilage defects of the knee. *J Med Assoc Thai* 2009; 92: 648-53.
 9. Ochi M, Uchio Y, Tobita M, Kuriwaka M. Current concepts in tissue engineering technique for repair of cartilage defect. *Artif Organs* 2001; 25: 172-9.
 10. Kasemkijwattana C, Kesprayura S, Chaipinyo K, Chanlalit C, Chansiri K. Autologous chondrocytes implantation with three-dimensional collagen scaffold. *J Med Assoc Thai* 2009; 92: 1282-6.
 11. Micheli LJ, Browne JE, Erggelet C, Fu F, Mandelbaum B, Moseley JB, et al. Autologous chondrocyte implantation of the knee: multicenter experience and minimum 3-year follow-up. *Clin J Sport Med* 2001; 11: 223-8.
 12. Henderson I, Lavigne P, Valenzuela H, Oakes B. Autologous chondrocyte implantation: superior biologic properties of hyaline cartilage repairs. *Clin Orthop Relat Res* 2007; 455: 253-61.
 13. Pittenger MF, Mackay AM, Beck SC, Jaiswal RK, Douglas R, Mosca JD, et al. Multilineage potential of adult human mesenchymal stem cells. *Science* 1999; 284: 143-7.
 14. Yoo JU, Barthel TS, Nishimura K, Solchaga L, Caplan AI, Goldberg VM, et al. The chondrogenic potential of human bone-marrow-derived mesenchymal progenitor cells. *J Bone Joint Surg Am* 1998; 80: 1745-57.
 15. Johnstone B, Hering TM, Caplan AI, Goldberg VM, Yoo JU. *In vitro* chondrogenesis of bone marrow-derived mesenchymal progenitor cells. *Exp Cell Res* 1998; 238: 265-72.
 16. Wakitani S, Goto T, Pineda SJ, Young RG, Mansour JM, Caplan AI, et al. Mesenchymal cell-based repair of large, full-thickness defects of articular cartilage. *J Bone Joint Surg Am* 1994; 76: 579-92.
 17. Yan H, Yu C. Repair of full-thickness cartilage defects with cells of different origin in a rabbit model. *Arthroscopy* 2007; 23: 178-87.
 18. Wakitani S, Imoto K, Yamamoto T, Saito M, Murata N, Yoneda M. Human autologous culture expanded bone marrow mesenchymal cell transplantation for repair of cartilage defects in osteoarthritic knees. *Osteoarthritis Cartilage* 2002; 10: 199-206.
 19. Kuroda R, Ishida K, Matsumoto T, Akisue T, Fujioka H, Mizuno K, et al. Treatment of a full-thickness articular cartilage defect in the femoral condyle of an athlete with autologous bone-marrow stromal cells. *Osteoarthritis Cartilage* 2007; 15: 226-31.
 20. Roos EM, Roos HP, Lohmander LS, Ekdahl C, Beynnon BD. Knee Injury and Osteoarthritis Outcome Score (KOOS)-development of a self-administered outcome measure. *J Orthop Sports Phys Ther* 1998; 28: 88-96.
 21. Nejadnik H, Hui JH, Feng Choong EP, Tai BC, Lee EH. Autologous bone marrow-derived mesenchymal stem cells versus autologous chondrocyte implantation: an observational cohort study. *Am J Sports Med* 2010; 38: 1110-6.

การปลูกถ่ายเซลล์ต้นกำเนิดจากไขกระดูกเพื่อรักษาการบาดเจ็บของกระดูกอ่อนข้อเข่า

ชาญณรงค์ เกษมกิจวัฒนา, สุรเดช หงส์อิ่ง, สุรพล เกษประยูร, วิศิษฎ์ รังษิณาภรณ์, กานดา ชัยภิญโญ, โกลุสม จันทรศิริ

วัตถุประสงค์: รายงานผลการรักษาการบาดเจ็บของกระดูกอ่อนด้วยวิธีการปลูกถ่ายเซลล์ต้นกำเนิดจากไขกระดูก (Autologous bone marrow mesenchymal stem cells implantation)

วัสดุและวิธีการ: ผู้ป่วยที่มีการบาดเจ็บของกระดูกอ่อนขั้นรุนแรง (grade 3-4 International Cartilage Repair Society Classification System) จำนวน 2 ราย ได้รับการผ่าตัดปลูกถ่ายเซลล์ต้นกำเนิดจากไขกระดูก (Autologous bone marrow mesenchymal stem cells implantation) ขั้นตอนแรกผู้ป่วยจะได้รับการเจาะดูดไขกระดูกจากกระดูกเชิงกราน (anterior iliac crest) ด้วยวิธีฉีดยาชาเฉพาะที่ (local anesthesia) นำไปแยกเซลล์ต้นกำเนิดจากไขกระดูกของผู้ป่วยเอง เพาะเลี้ยงใน three-dimensional collagen scaffold (atelocollagen type I collagen, Koken) ในห้องปฏิบัติการก่อนปลูกถ่ายเซลล์ต้นกำเนิดจากไขกระดูกใน three-dimensional collagen scaffold กลับไปยังผิวข้อที่ได้บาดเจ็บการติดตามผลการรักษาทางคลินิกโดยใช้ International Knee Documentation Committee Score (IKDC Score) และ Knee and Osteoarthritis Outcome Score (KOOS) ซึ่งประกอบด้วยอาการ, ความเจ็บปวด, การใช้งานในชีวิตประจำวัน, การใช้งานเล่นกีฬาคุณภาพชีวิตภายหลังการรักษาที่ระยะเวลา 30-31 เดือนร่วมกับการส่องกล้องตรวจ (arthroscopic assessment)

ผลการศึกษา: ผู้ป่วยมีอาการทางคลินิกดีขึ้นมากเทียบกับก่อนการรักษาจาก International Knee Documentation Committee Score (IKDC Score) และ Knee and Osteoarthritis Outcome Score (KOOS) การส่องกล้องตรวจพบเนื้อเยื่อกระดูกอ่อนใหม่ทดแทนรอยบาดเจ็บที่ผิวข้อ ไม่พบภาวะแทรกซ้อนตลอดผลการรักษา

สรุป: การติดตามผลการรักษาแสดงให้เห็นว่าการปลูกถ่ายเซลล์ต้นกำเนิดจากไขกระดูกในผู้ป่วยที่มีการบาดเจ็บของผิวข้อขั้นรุนแรง (autologous bone marrow mesenchymal stem cells implantation) ได้ผลเป็นที่น่าพอใจทั้งผลทางคลินิก และการติดตามผลจากการส่องกล้องตรวจ (arthroscopic assessment) นอกจากนี้ผู้ป่วยยังพึงพอใจที่ได้รับการผ่าตัดครั้งเดียวเทียบกับการผ่าตัดปลูกถ่ายเซลล์กระดูกอ่อน (autologous chondrocytes implantation) ซึ่งต้องได้รับการผ่าตัด 2 ครั้ง อย่างไรก็ตามยังต้องการติดตามผลการศึกษาระยะยาวต่อไป
