

Predictive Value of Magnetic Resonance Imaging in Cervical Spondylotic Myelopathy in Prognostic Surgical Outcome

Pipat Chiewvit MD*, Siri-on Tritrakarn MD*,
Anchalee Phawjinda MD*, Areesak Chotivichit MD**

* Division of Diagnostic Radiology, Department of Radiology, Faculty of Medicine Siriraj Hospital,
Mahidol University, Bangkok, Thailand

** Department of Orthopedics Surgery, Faculty of Medicine Siriraj Hospital, Mahidol University, Bangkok, Thailand

Objective: Establish the predictive value of magnetic resonance imaging (MRI) for cervical spondylotic myelopathy as being a good operative outcome.

Material and Method: A retrospective study of the 52 consecutive patients with cervical spondylotic myelopathy underwent both magnetic resonance imaging (MRI) cervical spines examination at Siriraj Hospital between January 2005 and June 2007. Surgery was divided into two groups: "Good" operative outcome (35 patients) and "No improvement group" (17 patients). Two neuroradiologists independently identified the MR images data that showed the maximum stenosis on sagittal and axial sections and recorded predictive MRI parameters: T2-weighted signal change of the spinal cord, cross-sectional area of the spinal cord, anteroposterior (AP) diameter of the spinal canal and the spinal cord and AP-compression ratio (AP diameter/transverse diameter of the spinal cord).

Results: There were no statistically significant differences between both groups in all parameters.

Conclusion: The AP-diameter of the spinal canal and spinal cord, AP-compression ratio and signal change of the spinal cord are not useful in predicting prognosis outcome in patients with cervical spondylotic myelopathy. In addition, cross-sectional area of the spinal cord cannot confidentially be used as predictive factor in CSM patients due to many influent factors of surgical outcome. A further prospective study without patient selective bias may offer more definite results to confirm these findings.

Keywords: Magnetic resonance imaging, Cervical spondylotic myelopathy, Predictive outcome

J Med Assoc Thai 2011; 94 (3): 346-54

Full text. e-Journal: <http://www.mat.or.th/journal>

Cervical spondylotic myelopathy (CSM) is the most common cause of acquired spastic paraparesis in the middle and later years of life^(1,2) and the most common type of spinal cord dysfunction in patients older than 55 years. CSM can cause a wide variety of signs and symptoms and no pathognomonic clinical findings. The diagnosis can usually be made on the basis of findings from the history, physical examination, and plain radiographs, but confirmation by magnetic resonance imaging or computed tomographic myelography is necessary. MRI allows for specific evaluation of the intervertebral discs,

vertebral osteophytes, and ligaments. MRI (Magnetic Resonance Imaging) can also identify an intrinsic spinal cord lesion that may also present with myelopathy⁽⁴⁾.

The treatment of CSM remains particularly subject to controversy, non-surgical treatment can be taken in the early stage or in the milder cases (conservative management such as collar immobilization and traction, physical therapy and medication). There is no evidence-based recommendation for surgical treatment. Patients with cord compression and clinical signs and symptoms of CSM, particularly those with progression, are candidates for operative intervention⁽⁵⁾. Although, early surgery is recommended^(2,6,7), especially within 1 year of symptom onset is associated with a substantial improvement in neurologic prognosis. Hence, discovery of other parameters may help us to decide the appropriate time of surgery for each patient unless clinical progression

Correspondence to:

Pipat Chiewvit, Division of Diagnostic Radiology, Department of Radiology, Faculty of Medicine, Siriraj Hospital, Mahidol University, Bangkok 10700, Thailand.

Phone: 0-2419-7089

E-mail: pipat8999@yahoo.com

is not developed. Several previous studies^(8-11,5) reported about prognostic factors of cervical spondylotic myelopathy treated surgically, but uncertainty of the results was found. Therefore, the authors attempted to establish predictive value in the role of MRI, now it is a valuable tool for accurate diagnosis and important preoperative evaluation, in cervical spondylotic myelopathy for a good operative outcome.

Material and Method

The present study was a cross sectional study approved by the authors' institutional review board committee.

Patients

Two hundred consecutive patients were diagnosed with cervical spondylotic myelopathy according to ICD 10 (M47.12 = other spondylosis with myelopathy, Cervical region and G99.2* = myelopathy in diseases classified elsewhere) and 94 of these patients underwent MR examination at our institute between January 2005 and June 2007. Those were included in the present study. The medical records of all patients were retrospectively reviewed and 73 patients who underwent surgical treatment were recruited. Follow-up time was designed at about 6 months for each patient. The exclusion criteria were 1) Patients who refused surgical treatment at our hospital. 2) Unavailable complete clinical data for assessment. 3) Patients who had co-morbid diseases that presented similar clinical symptoms and signs to CSM such as lumbar spinal stenosis, thoracic myelopathy and carpal tunnel syndrome. 4) Previous surgery of cervical spines. 5) Dead from systemic disease or unknown cause.

The present study sample consisted of 52 consecutive patients divided into two groups, the "Good" group consisted of patients with good operative outcome (35 patients) and the "No improvement" group was patients with no improvement after surgical intervention (17 patients). For clinical evaluation, Modified Japanese Orthopedic Association (mJOA) score for cervical myelopathy (Table 1)⁽¹²⁾ was utilized to quantify neurological function before surgical intervention and at the follow-up time. The range of this score is 0 to 21; 0 = maximal neurological deficits, 21 = no neurological deficits. The patients in both groups were categorized according to the effect of the treatment based on the mJOA score as follows:

"Good" group: good operative outcome defined as significantly better mJOA score (> 1 point)
 "No improvement" group: no improvement defined as unchanged or deteriorated in mJOA score.

Patients' medical records including patient age, sex, duration of symptoms, duration between MRI and operation, surgical method and follow-up time were reviewed. Duration of symptoms counted from the initial symptoms to the time of surgery.

MR imaging

MRI of the cervical spine was obtained on sagittal spin-echo (SE) T1- and T2-weighted images and axial SE T2-weighted or axial balanced gradient-echo (GRE) images using one of 1.5 or 3 Tesla Philips

Table 1. Modified Japanese Orthopedic Association score for cervical myelopathy⁽¹²⁾

I. Motor dysfunction score for the upper extremities	
0	Unable to move hands
1	Unable to eat with a spoon but able to move hands
2	Unable to button shirt but able to eat with a spoon
3	Able to button shirt with great difficulty
4	Able to button shirt with slight difficulty
5	No dysfunction
II. Motor dysfunction score for the lower extremities	
0	Complete loss of motor and sensory function
1	Sensory preservation without ability to move legs
2	Able to move legs but unable to walk
3	Able to walk on flat floor with a walking aid (cane or crutch)
4	Able to walk up or down stairs with handrail
5	Moderate to significant lack of stability but able to walk up or down stairs without handrail
6	Mild lack of stability but able to walk with smooth reciprocation unaided
7	No dysfunction
III. Sensory dysfunction score for the upper extremities	
0	Complete loss of hand sensation
1	Severe sensory loss or pain
2	Mild sensory loss
3	No sensory loss
IV. Sensory dysfunction score for the lower extremities	
0	Complete loss of foot sensation
1	Severe sensory loss or pain
2	Mild sensory loss
3	No sensory loss
V. Sphincter dysfunction score	
0	Unable to micturate voluntarily
1	Marked difficulty with micturation
2	Mild to moderate difficulty with micturation
3	Normal micturation

Table 2. MR imaging protocol used in the present study

	Sequence	TR (msec)	TE (msec)	Flip angle (°)	Section thickness (mm)
1.5T	Sagittal SE T1 W	400-450	12	90	3-4
	Sagittal SE T2 W	2,880-2,970	110-120	90	3-4
	Axial balanced GRE	9	4	45	4
3T	Sagittal SE T1 W	420-530	6.6-7.2	90	3
	Sagittal SE T2 W	2,900-3,500	100-120	90	3
	Axial SE T2 W	2,000-4,500	110-120	90	2-3
	Axial balanced GRE	5	2	45	3

1.5T = 1.5 Tesla; 3T = 3 Tesla; SE = spin-echo; GRE = gradient-echo; T1W = T1-weighted; T2 W = T2-weighted; TR = repetition time; TE = echo time

system with a sense coil. The parameters of MR imaging protocol used in the present study are shown in Table 2.

Analysis of MR images

The MR images were independently reviewed by a board-certified neuroradiologist with 15 years experience and a board-certified neuroradiologist with 2 years of neuroimaging experience who read neuroimages on a regular basis. They were blinded to clinical outcome.

The radiologists reviewed the MR images on the PACS, then recorded the complexity of involvement divided into two subgroups including single and multiple (> 2 levels) involvement.

Subsequently, they independently identified the slice that showed the maximum stenosis on sagittal and axial sections. The radiologists measured anteroposterior (AP) diameter of the spinal canal and spinal cord, and transverse diameter of the spinal cord using an electronic cursor on the PACS. The cross-sectional area of the spinal cord was also measured using an electronic cursor on the View Forum 2 (Philips). The measurement of these parameters is illustrated as in Fig. 1 and 2. After that, the measured values of AP and transverse diameters of the spinal cord were calculated to be the AP-compression ratio (the AP diameter of the spinal cord divided by the transverse diameter of the spinal cord).

T2-weighted signal changes of the spinal cord were recorded using initially sagittal SE T2-weighted images followed by axial SE T2-weighted or axial balanced GRE images if equivocal signal was presented.

In equivocal cases, a decision was made on the basis of the consensus of the two radiologists.

Statistical analysis

All continuous (quantitative) data, including the patient age, duration of symptoms, duration between MRI and operation, follow-up time, pre-operative mJOA score, cross-sectional area of the spinal cord, AP-diameter of the spinal canal and of the spinal cord, and AP-compression ratio, were reported as the mean \pm SD. Comparison of these data between groups used an Unpaired t-test. The Intraclass Correlation Coefficients was used to assess the degree of observer agreement between the two radiologists.

To analyze the qualitative data, including sex, complexity of involvement, surgical method and T2-weighted signal changes of the spinal cord, for Good and Fair groups, using a Chi-Square test. The authors used the Cohen kappa coefficient to assess the degree of interobserver agreement for signal changes of the spinal cord. The scale for the kappa coefficients was K < 0.20, poor; 0.21-0.40, fair; 0.41-0.60, moderate; 0.61-0.80, substantial and 0.81-1.00, almost perfect^(14,15).

Values for p of less than 0.05 were considered to indicate statistically significant differences. Statistical analysis was performed with a statistical software package (SPSS, version 11.5).

Results

Twenty-one of 73 CSM patients that underwent surgical treatment were excluded from the present study, one case refused treatment at our hospital, eight cases with insufficient clinical data for assessment, seven cases had co-morbid disease (3 of lumbar spinal stenosis, three of thoracic myelopathy and one of carpal tunnel syndrome), three cases who previously underwent surgical treatment of CSM and two cases had died (one from cardiac disease and another with unknown cause).

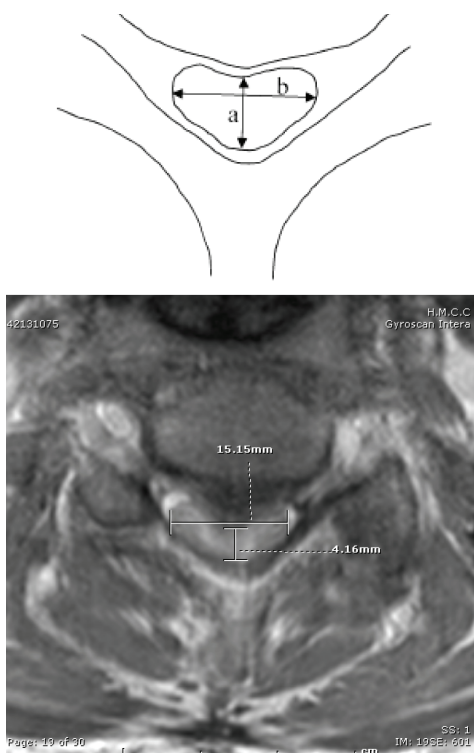


Fig. 1 Drawing and axial balanced GRE image demonstrating measurement of the AP-diameter (a) and transverse diameter (b) of the spinal cord at the most stenotic level. AP-Compression ratio = a/b

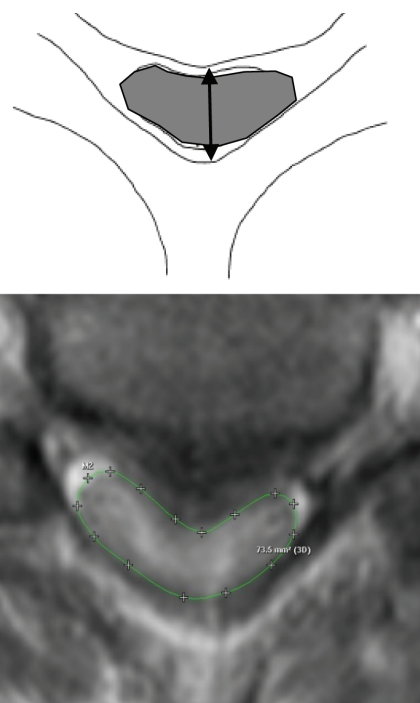


Fig. 2 Drawing and axial balanced GRE image demonstrating measurement of the cross-sectional area of the spinal cord (gray area on drawing and area within green line on balanced GRE image) and AP-diameter of spinal canal (arrow line on drawing) at the most stenotic level.

The clinical background and qualitative data of the 52 studied patients are shown in Table 3 and 4. Two surgical methods were performed in the present study including anterior cervical discectomy and fusion (ACDF) and laminoplasty. There was no significant difference between the “Good group” and the “No improvement” group in any of the parameters including clinical background (age, sex, duration of disease, duration between MRI and operation, follow-up time), pre-operative clinical severity (mJOA score), method of surgical intervention and complexity of involvement. The authors found that the duration of symptoms and duration between MRI and operation were non normal distribution data, therefore a Mann-Whitney test was instead used to analyze statistic significance, which showed no significant difference with p-value of 0.768 and 0.704, respectively. The 1.5 Tesla system was used in 17 of 35 patients in Good group and seven of 17 patients in “No improvement” group. The other patients were performed on the 3 Tesla system. Axial

balanced GRE images were obtained in all patients who performed on the 1.5 Tesla system and in eight patients who performed on the 3 Tesla system. Axial SE T2-weighted images were obtained in 20 of 28 patients who performed on the 3 Tesla system. High T2 signal-intensity areas in the spinal cord were seen in 49 of 52 patients (33 of the “Good group” and 16 of the “Fair group”). There was only one patient (in the “Good group”) that the radiologists identically interpreted no change of the intensity (reviewed by sagittal and axial SE T2-weighted images performed with 3 Tesla system). Another two cases (1 in each group; both were performed with SE sequence of 3 Tesla system in both sagittal and axial views), the two readers did not have the same results. The kappa coefficients for signal changes of the cord was 0.6804 representing substantial interobserver agreement. After decision of the consensus, signal intensity change of both two cases was considered. The scale for the correlation coefficients for interobserver agreement was $K < 0.40$,

Table 3. Comparative clinical background and pre-operative mJOA score of patients in each group

Variables	Good group			No improvement group			p
	Mean ± SD	Median	Range	Mean ± SD	Median	Range	
Age (y)	60.74 ± 10.722	63	38-82	62.00 ± 8.696	65	42-73	0.676
Duration (m)	9.629 ± 11.246	6	1-60	6.961 ± 4.851	6	0.3-18	0.768
MRI to operation (d)	48.86 ± 48.534	32	1-210	42.47 ± 62.362	33	6-280	0.704
FU time (m)	5.91 ± 1.197	6	4-8	6.06 ± 0.243	6	6-7	0.497
Pre-op mJOA	17.06 ± 2.114	17	11-20	16.71 ± 2.519	16	11-20	0.600

Duration = duration of disease; FU time = follow-up time; MRI to operation = duration between MRI and operation; y = year; m = month; d = day; Pre-op mJOA = pre-operative mJOA score (maximum 21 points); p = p-value (less than 0.05 indicating statistically significant differences)

Table 4. Comparative qualitative data of clinical background, MRI findings in each group

Variables		Good group	No improvement group	Total	p
Sex	Male	19 (54.3)	12 (70.6)	31 (59.6)	0.411
	Female	16 (45.7)	5 (29.4)	21 (40.4)	
Surgical method	ACDF	28 (80)	13 (76.5)	41 (78.8)	0.517
	Laminoplasty	7 (20)	4 (23.5)	11 (21.2)	
Complexity of involvement	Single	8 (22.9)	3 (17.6)	11 (21.2)	0.483
	Multiple	27 (77.1)	14 (82.4)	41 (78.8)	
Signal change of spinal cord	Yes	34 (97.1)	17 (100)	51 (98.1)	0.673
	No	1 (2.9)	0 (0)	1 (1.9)	

Data are numbers (%) of patients

ACDF= anterior cervical discectomy and fusion; p = p-value (less than 0.05 indicating statistically significant differences)

Table 5. Comparative measurements of patients in each group

Variables	Good group (mean ± SD)			No improvement group (mean ± SD)			p
	I	II	Average	I	II	Average	
Cord area (mm ²)	57.231±19.288	58.014±14.606	57.623±15.751	49.115±18.114	50.790±21.909	49.953±19.058	0.131
AP-Canal diameter (mm)	6.376±1.899	6.365±1.880	6.371±1.841	5.652±1.569	5.803±1.706	5.727±1.706	0.225
AP-Cord diameter (mm)	5.067±1.296	5.433±1.297	5.250±1.219	4.531±1.103	5.154±1.120	4.842±1.081	0.246
Compression ratio	0.387±0.115	0.408±0.119	0.397±0.114	0.351±0.080	0.399±0.099	0.375±0.088	0.481

I = radiologist 1; II = radiologist 2; Average = average of measured values of two radiologists; Cord area = cross-sectional area of spinal cord; AP-Canal diameter = anteroposterior diameter of spinal canal; AP-Cord diameter = anteroposterior diameter of spinal cord; p = p-value (less than 0.05 indicating statistically significant differences)

poor; 0.40-0.75, fair-good; > 0.75, excellent⁽¹³⁾. The results after the consensus are shown in Table 5.

For comparative measurement data (Table 5), the Intraclass Correlation Coefficients for the cross-

sectional area of spinal cord, AP-diameter of the spinal canal and the spinal cord and AP-compression ratio were 0.8560, 0.9520, 0.8597 and 0.9251, respectively. The measured values of each parameter by two radiologists

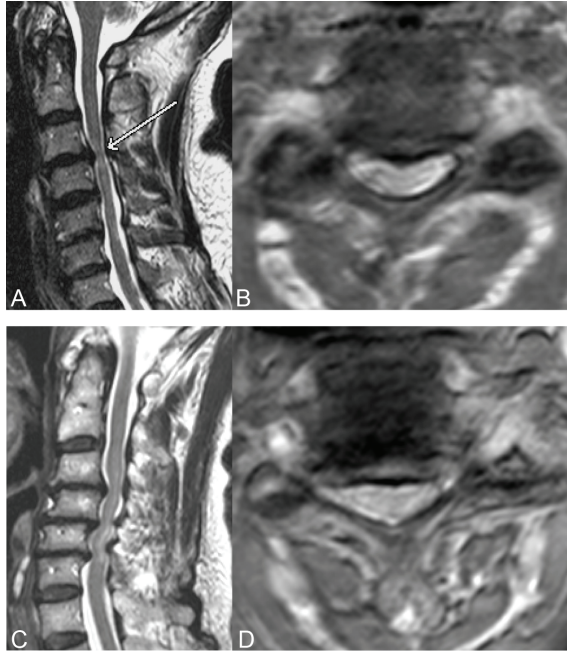


Fig. 3 A-B, A 70-year-old man presenting with tumble over 4 days ago, then developed quadriplegia. Sagittal SE T2-weighted (A) and axial balanced GRE (B) images (1.5 Tesla) show CSM with maximum stenosis at C3-4 level. The spinal cord area is about 34.90 mm², AP diameter of spinal canal and spinal cord are 5.15 and 2.93 mm, respectively. Compression ratio is 0.26. After ACDF with iliac bone graft, deteriorated mJOA score was presented at 6 months of follow-up time C-D, another 82-year-old female with 10 months of CSM symptoms had good operative outcome after underwent laminoplasty whereas the measured values showed no significant difference. At C3-4 level (maximum stenosis), spinal cord area is about 27.55 mm², AP diameter of spinal canal and spinal cord are 6.49 and 4.64 mm, respectively. Compression ratio is 0.36. Sagittal SE T2-weighted (C), axial balanced GRE (D) (3 Tesla)

were averaged for comparison between the two groups that showed no significant difference. Representative cases are shown in Fig. 3 and 4.

Discussion

Several previous studies have reported about the prognostic factors in the cervical spondylotic myelopathy treated surgically, but there are still controversies, especially in the role of MRI parameters. The heterogeneity of the patients studied, many

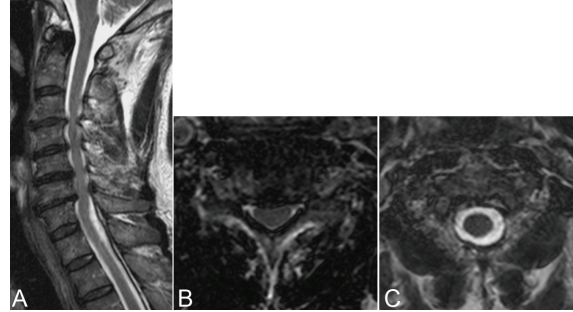


Fig. 4 A 67-year-old man with CSM. A-C, Sagittal (A) and axial (B, C) SE T2-weighted images show multiple levels of spinal stenosis from disc-osteophyte complex with maximum stenosis at C5-6 level (B). Equivocal interpretation of signal changes of spinal cord was occurred, compared with axial image of normal spinal cord signal at C1-2 level (C)

confounding factors and small sample size were influential factors.

Fujiwara K et al⁽⁸⁾ reported the transverse area of the spinal cord at the level of maximum compression assessing from computed tomographic myelography provided the most reliable parameter in prognosis. However, the compression ratio could not be used to determine the prognosis. Hamburger C et al⁽¹⁰⁾ found that the preoperative area of the spinal canal from computed tomography scans could not be used as a prognostic tool for surgical outcome. The preoperative clinical presentation of the patient was found to be the only prognostic hint for improvement after surgery.

Chung SS et al⁽¹¹⁾ reported that the preoperative JOA score, Pavlov ratio and compression ratio were useful in predicting the prognosis in patients with CSM. The greater compression ratio and larger Pavlov ratio correlated with good operative outcome. In the present study, which was a comparative study between the study group (*i.e.*, Good group) and control group (*i.e.*, No improvement group) had no statistically significant difference of clinical background in the patients of both groups including age, sex, duration of symptoms, duration between MRI and operation and follow-up time. Pre-operative clinical severity (mJOA score), complexity of involvement and method of surgical intervention showed no significant difference between the groups. These contributed to diminish the confounding factors in the present study. Although there was no statistically significant difference of sex

in the patients of both groups, the difference in proportion was easily noticeable (Male: 54.3% of the Good group and 70.6% of the No improvement group; Female: 45.7% of Good group and 29.4% of No improvement group). These might be from the small sample size resulting in inadequate power for detecting a difference. The results showed no significant statistical difference of compression ratio between the two groups, which were similar with results of Fujiwara K et al⁽⁸⁾. However, Chung SS et al⁽¹¹⁾ found that greater compression ratio correlate with good operative outcome. Nevertheless, patients in their study were only included if they had spondylotic myelopathy at more than three levels.

When there is concern about the spinal cord area, the present study found the Good group had greater spinal cord area than the No improvement group (Good group = 57.623 mm², No improvement group = 49.953 mm²), but this difference was not statistically significant. This might be the result from the sample size being too small. Kadanka Z et al⁽⁵⁾ reported that the patients with a good outcome in the surgically treated group had a more serious clinical picture and a lesser transverse area of the spinal cord (< 70 mm²). However, their study only evaluated patients with mild or moderate disease. Whereas the present study included patients with progressive or severe disease. Comparison between the Good and No improvement groups, both AP-diameters of the spinal canal and spinal cord showed no significant statistical difference. Consistent with the presented findings, Kadanka Z, et al⁽⁵⁾ reported that the AP-diameter of the spinal canal and spinal cord were not predictive in the surgically treated group.

There were several reports concerning the significance of a high signal-intensity area in the spinal cord. Kohno K et al⁽¹⁶⁾ and Nakamura M and Fujimura Y⁽¹⁷⁾ had been reported that a high signal intensity was a poor prognostic factor. Yone et al⁽¹⁸⁾, Morio et al⁽¹⁹⁾ and Chung SS et al⁽¹¹⁾ maintained that the presence or absence of a high-intensity area did not correlate with surgical results. Similar results in the present study, signal change of the spinal cord was not the influent factor of surgical outcome. The authors consider this result to be reasonably explained by increased signal intensity at the level of spinal cord damage, particularly on T2-weighted images, did not only represent irreversible cord damage, but might be presented due to inflammation, edema, ischemia, gliosis, or myelomalacia. Disagreement for interpretation of signal change of cord can occur in equivocal cases as

well as in the present study, because the interpretation of signal change was subjective, without measured data.

When concern about MRI sequences used in the present study, axial balanced GRE images were obtained in all patients performed with the 1.5 Tesla system and some patients with the 3 Tesla system. The advantages of the balanced GRE sequence are higher signal-to-noise ratio than other GRE sequences and less sensitive to motion than the SE sequence⁽²⁰⁾. Although, limitation of balanced GRE contrasts depending on the T2/T1 ratio, field inhomogeneity may lead to the formation of a spin echo rather than a gradient echo⁽²¹⁾.

The present study had some limitations. First, the outcome of the surgical treatment is dependent on many factors. Although, the authors attempted to diminish the confounding factors and found no significant difference in any parameters of both studied groups. Second, the lack of long-term follow-up period due to limited study time. Since outcomes vary so widely, with some patients remaining relatively stable and others deteriorating^(22,23). Third, the sample size in the present study was small and completely pre-operative MR examination, and insufficient clinical data for assessment due to retrospective review of the medical records. Fourth, the outcomes should to be compared with a control group managed nonsurgically. Finally, inhomogeneity of MRI sequences may be or may not be one of the confounding factors.

Conclusion

AP-diameter of spinal canal and spinal cord, AP-compression ratio and signal change of spinal cord are not useful in predicting the prognostic outcome in patients with CSM. In addition, cross-sectional area of the spinal cord cannot be confidentially used as a predictive factor in CSM patients due to many influent factors of surgical outcome. A further prospective study without patient selective bias may offer more definite results to confirm these findings.

Acknowledgements

The authors wish to thank Kullathorn Thephamongkhol, MD for research methodology; Assistant Professor Pairash Saiviroonporn, PhD for MRI protocol, and MRI parameter assessment, Chulaporn Pool-ium for analysis.

Potential conflicts of interest

None.

References

1. Small JM, Dillin WH, Watkins RG. Clinical syndromes in cervical myelopathy. In: Herkowitz H, Garfin SR, Balderson RA, editors. *The spine*. 4th ed. Philadelphia: W.B. Saunders; 1999: 465-74.
2. Montgomery DM, Brower RS. Cervical spondylotic myelopathy. Clinical syndrome and natural history. *Orthop Clin North Am* 1992; 23: 487-93.
3. Gorter K. Influence of laminectomy on the course of cervical myelopathy. *Acta Neurochir (Wien)* 1976; 33: 265-81.
4. Gross JD, Benzel EC. Dorsal surgical approach for cervical spondylotic myelopathy. In: Camins MB, editor. *Techniques in neurosurgery*. Philadelphia: Lippincott Williams & Wilkins; 1999: 162-76.
5. Kadanka Z, Mares M, Bednarik J, Smrcka V, Krbec M, Chaloupka R, et al. Predictive factors for spondylotic cervical myelopathy treated conservatively or surgically. *Eur J Neurol* 2005; 12: 55-63.
6. Phillips DG. Surgical treatment of myelopathy with cervical spondylosis. *J Neurol Neurosurg Psychiatry* 1973; 36: 879-84.
7. Ebersold MJ, Pare MC, Quast LM. Surgical treatment for cervical spondylitic myelopathy. *J Neurosurg* 1995; 82: 745-51.
8. Fujiwara K, Yonenobu K, Ebara S, Yamashita K, Ono K. The prognosis of surgery for cervical compression myelopathy. An analysis of the factors involved. *J Bone Joint Surg Br* 1989; 71: 393-8.
9. Okada Y, Ikata T, Katoh S, Yamada H. Morphologic analysis of the cervical spinal cord, dural tube, and spinal canal by magnetic resonance imaging in normal adults and patients with cervical spondylotic myelopathy. *Spine (Phila Pa 1976)* 1994; 19: 2331-5.
10. Hamburger C, Buttner A, Uhl E. The cross-sectional area of the cervical spinal canal in patients with cervical spondylotic myelopathy. Correlation of preoperative and postoperative area with clinical symptoms. *Spine (Phila Pa 1976)* 1997; 22: 1990-4.
11. Chung SS, Lee CS, Chung KH. Factors affecting the surgical results of expansive laminoplasty for cervical spondylotic myelopathy. *Int Orthop* 2002; 26: 334-8.
12. Lyu RK, Tang LM, Chen CJ, Chen CM, Chang HS, Wu YR. The use of evoked potentials for clinical correlation and surgical outcome in cervical spondylotic myelopathy with intramedullary high signal intensity on MRI. *J Neurol Neurosurg Psychiatry* 2004; 75: 256-61.
13. Rosner B. Hypothesis testing in one-way ANOVA—fixed effects model. In: Rosner B, editor. *Fundamentals of biostatistics*. 4th ed. Belmont, CA: Duxbury Press; 1995: 518-21.
14. Landis JR, Koch GG. The measurement of observer agreement for categorical data. *Biometrics* 1977; 33: 159-74.
15. Svanholm H, Starklint H, Gundersen HJ, Fabricius J, Barlebo H, Olsen S. Reproducibility of histomorphologic diagnoses with special reference to the kappa statistic. *APMIS* 1989; 97: 689-98.
16. Kohno K, Kumon Y, Oka Y, Matsui S, Ohue S, Sakaki S. Evaluation of prognostic factors following expansive laminoplasty for cervical spinal stenotic myelopathy. *Surg Neurol* 1997; 48: 237-45.
17. Nakamura M, Fujimura Y. Magnetic resonance imaging of the spinal cord in cervical ossification of the posterior longitudinal ligament. Can it predict surgical outcome? *Spine (Phila Pa 1976)* 1998; 23: 38-40.
18. Yone K, Sakou T, Yanase M, Ijiri K. Preoperative and postoperative magnetic resonance image evaluations of the spinal cord in cervical myelopathy. *Spine (Phila Pa 1976)* 1992; 17(10 Suppl): S388-92.
19. Morio Y, Yamamoto K, Kuranobu K, Murata M, Tuda K. Does increased signal intensity of the spinal cord on MR images due to cervical myelopathy predict prognosis? *Arch Orthop Trauma Surg* 1994; 113: 254-9.
20. Chavhan GB, Babyn PS, Jankharia BG, Cheng HL, Shroff MM. Steady-state MR imaging sequences: physics, classification, and clinical applications. *Radiographics* 2008; 28: 1147-60.
21. Scheffler K, Hennig J. Is TrueFISP a gradient-echo or a spin-echo sequence? *Magn Reson Med* 2003; 49: 395-7.
22. Hochman M, Tuli S. Cervical spondylotic myelopathy: a review. *The Internet Journal of Neurology*. 2005; 4 (1).
23. Orr RD, Zdeblick TA. Cervical spondylotic myelopathy. Approaches to surgical treatment. *Clin Orthop Relat Res* 1999; 58-66.

การพยากรณ์ผลการผ่าตัดในผู้ป่วยที่มีภาวะกระดูกคอเสื่อมกดทับไขสันหลัง ด้วยการตรวจเอ็มอาร์ไอกระดูกสันหลังคอ

พิพัฒน์ เขียววิทย์, สิริอร ตรีตระการ, อัญชลี เผ่าจินดา, อารีศักดิ์ โชติวิจิตร

วัตถุประสงค์: เพื่อพยากรณ์ว่าการตรวจด้วยคลื่นแม่เหล็กไฟฟ้า ในผู้ป่วยที่มีภาวะกระดูกคอเสื่อมจะช่วยตัดสินใจเลือกการรักษาแบบผ่าตัดได้หรือไม่

วัสดุและวิธีการ: ศึกษาแบบย้อนหลังในช่วงเวลาตั้งแต่เดือนมกราคม พ.ศ. 2548 ถึง มิถุนายน พ.ศ. 2550 ของผู้ป่วย 52 ราย ที่ได้รับการวินิจฉัยเป็น cervical spondylotic myelopathy และทุกรายได้รับการตรวจวินิจฉัยกระดูกสันหลังส่วนคอโดยวิธีเอ็มอาร์ไอ และผู้ป่วยทุกรายได้รับการผ่าตัด การศึกษานี้ได้แบ่งผู้ป่วย ออกเป็น 2 กลุ่ม ได้แก่ กลุ่มแรกเป็นกลุ่มที่มีผลการรักษาดี (35 ราย) กลุ่มที่สอง เป็นกลุ่มที่ผลการรักษาไม่เปลี่ยนแปลง (17 ราย) ภาพเอ็มอาร์ไอของผู้ป่วยทั้ง 2 กลุ่มจะได้รับการตรวจวัดส่วนที่แคบที่สุดของกระดูกสันหลังในแนว sagittal และ axial T2W, สัญญาณการเปลี่ยนแปลงของไขสันหลัง, การวัดพื้นที่หน้าตัดของไขสันหลัง และอัตราส่วนการถูกกดทับของไขสันหลังวัดโดยรังสีแพทย์ทางระบบประสาท 2 คน ที่เป็นอิสระกัน

ผลการศึกษา: พบว่าข้อมูลที่ได้ของผู้ป่วยทั้ง 2 กลุ่ม ไม่มีความแตกต่างอย่างมีนัยสำคัญทางสถิติในทุกตัววัดทางรังสีวิทยา

สรุป: การวัดความกว้างของช่องไขสันหลัง และตัวไขสันหลังตลอดจนการกดทับ และการเปลี่ยนแปลงในเนื้อไขสันหลังที่แสดงโดย magnetic resonance imaging (MRI) ไม่สามารถพยากรณ์ผลการผ่าตัดได้เนื่องจากมีหลายปัจจัยเกี่ยวข้องของการศึกษาแบบไปข้างหน้า และมีจำนวนผู้ป่วยที่มากเพียงพอจะทำให้สามารถได้ข้อสรุปที่ชัดเจนต่อไป
