

Case Report

Result of Esophageal Reconstruction Using Supercharged Interposition Colon in Corrosive and Boehave's Injury: Thammasat University Hospital Experience

Surajit Awsakulsutthi MD*

* Department of Surgery, Faculty of Medicine, Thammasat University, Pathumthani, Thailand

Seven esophageal reconstructions with interposition colon in severe suicide corrosive ingestion and Boehave's injury at Thammasat University Hospital were presented. Vascular enhancement (as called "supercharge") were done. Only one patient had micro-leakage at pharyngeal anastomosis with healed by conservative treatment and no late anastomotic stricture. The operation need more time and general surgeon skill but better comparison outcome.

Conclusion: Using supercharged interposition colon in adult esophageal reconstruction in corrosive and Boehave's injury was benefit in lower the incidence of anastomotic leakage and late anastomotic stricture. Just a longer operative time and vascular anatomizes skill were need.

Keywords: Esophageal reconstruction, Supercharged, Interposition colon, Thammasat University Hospital

J Med Assoc Thai 2010; 93 (Suppl. 7) : S303-S306

Full text. e-Journal: <http://www.mat.or.th/journal>

Thammasat university hospital as the trauma center, severe suicide corrosive ingestion were common. Total loss of esophagus and stomach are challenge problems for the late reconstructions. Esophageal reconstructions can be done by small and large bowl. As a choice, pedicle interposition colons were used. Anastomotic leakage and late stricture were common post-operative complications. Ischemia was believed to contribute significantly to this complication⁽¹⁾. With the advent of vascular anastomosis, vascular augmentation (as called "supercharge") were adopted as a means of avoiding this problem.

Case Report

Seven total loss of esophagus patients, who reconstructed by interposition colon in Thammasat university hospital between 2000-2005 were vascularized by augmented microvascular anastomosis. Five were male and two were female. Their mean age

was 23.3 years (rang, 18-33) (Table 1).

Six were caused by suicide corrosive ingestion and one by Boehave's syndrome. All corrosive ingestion were previous esophago-gastrectomy due to necrosis of esophageal and stomach (Fig. 1). The patient, who Boehave's syndrome, was only previous esophagectomy.

By the judgments of general surgeon depend on vascular anatomy and fibrosis severity. Five were reconstructed by left interposition colons and two by right interposition colons. Retro-sternum dissections and rail-road technique were all done. The interposition colon anastomosis were done between pharyngeal and jejunum, except who Boehave's syndrome was done between pharyngeal and stomach.

Technique

The operation was performed by two teams of general and plastic surgeons. After laparotomy, the colon and their mesocolonic vessels were selected by the general surgeon. At distal-end of colon flap, that pharyngeal anastomosis were planned, the recipient vessels should be meticulous dissected as longest as possible for the vascular anastomosis was easily done (Fig. 2, 3).

After that left side neck incision was done

Correspondence to:

Awsakulsutthi S, Department of Surgery, Faculty of Medicine, Thammasat University, Klonglaung, Pathumthani 12100, Thailand.

Phone: 0-2926-9477

E-mail: awsakul@yahoo.com

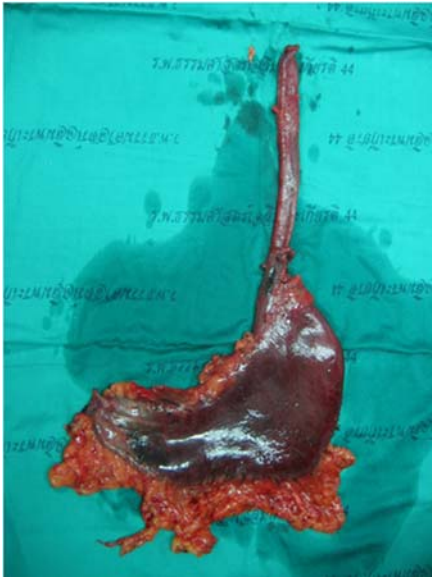

Fig. 1 Necrosis of esophagus and stomach in case of suicide corrosive ingestion

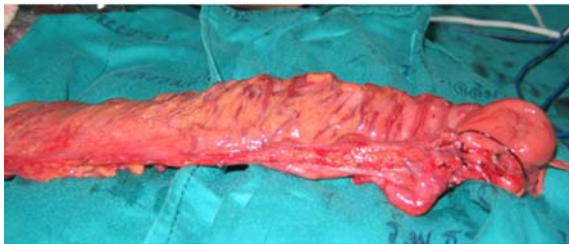

Fig. 2 Show dissected pedicle interposition colon

and the colon was pulled up rail-road pass the retro-sternum route. During the general surgeons did intra-abdominal bowel anastomosis, the plastic surgeons did the microvascular anastomosis at cervical site.

In six patients, donor artery were transverse cervicalis artery and one patient, superior thyroid artery was used. The donor vein all were external jugular veins and only one anterior jugular vein was added. The first five patients, the vascular anastomosis were done under microscope magnifications. The two later were done under loupe magnifications. The suture technique were interrupted 8/0 nylons (Fig. 4).

Before and after the microvascular anastomosis, proximal interposition colon vascularization were observed. All were better vascularized for the bright arterial bleeding and congestion of colons were diminished. Then the general surgeons did the pharyngeal anastomosis and completed the operations

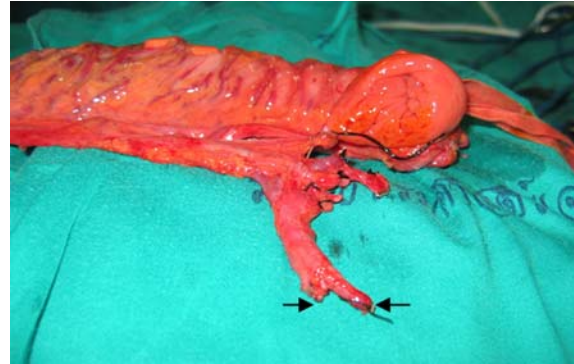


Fig. 3 Show mesocolon pedicle preparation for supercharged vascular enhancement (left arrow: artery, right arrow: vein)

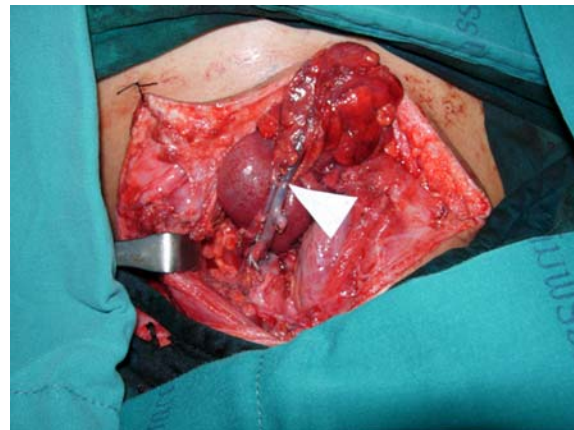


Fig. 4 Show supercharged vascular anastomosis (white marker)

as their technique.

Results

The operative time were average 6.8 hours (rang, 6-8). When comparison to previous performed pedicle interposition colon in this hospital, operative time were 40-60 minutes longer than. No immediate post-operative complications were noted. After 10th post-operative days, the contrast media swallow study was done. Only one patient had micro-leakage at pharyngeal anastomosis, that healed after 7 day conservative treatment. For the 2nd, 4th week, 3rd and 6th month follow-up, all had no late anastomosis stricture problem.

Discussion

Colonic flap or conduit is more appropriate for esophageal reconstruction for the following

Table 1. Esophageal reconstruction using supercharged interposition colon (n = 7)

No.	Sex	Age	Cause	Used colon	Anastomosis	Recipient		Operative time (hr)
						Artery	Vein	
1	M	33	Boehave's syndrome	Lt	Esophagus-stomach	Transverse cervicalis	Ext. jugular	8.0
2	M	24	Corrosive	Rt	Esophagus-jejunum	Transverse cervicalis	Ext. jugular	7.5
3	F	24	Corrosive	Lt	Esophagus-jejunum	Transverse cervicalis	Int. jugular	6.0
4	M	20	Corrosive	Lt	Esophagus-jejunum	Superior thyroid	Ext. jugular	7.5
5	M	22	Corrosive	Rt	Esophagus-jejunum	Transverse cervicalis	1. Ext. jugular 2. Ant. Jugular	6.0
6	M	18	Corrosive	Lt	Esophagus-jejunum	Transverse cervicalis	Ext. jugular	6.6
7	M	22	Corrosive	Lt	Esophagus-jejunum	Transverse cervicalis	Ext. jugular	6.0

reasons⁽²⁾: it has a straight shape, end-to-end anastomosis is possible to both the pharynx and distal anastomosis (may be stomach or jejunum site). In spite of careful selection of patients for surgery and meticulous operative technique, incidence of anastomotic leakage or late anastomotic stricture just were high (5.1-13.3%)^(3,4). Many believes that these complications were the sequelae of ischemia. Some of the factors were identified as correlating with the risk of ischemia include length of conduit, intra-abdominal fibrosis, route of passage of the conduit and tension to mesocolon.

Esophageal reconstruction after suicide corrosive ingestion or severe infection, intra-abdominal fibrosis was main problem. In spite of delayed reconstructive time, fibrotic mesocolon and surrounding area often remained. These caused tension to mobilized pedicle colon that secondary caused venous insufficiency.

Ischemic complications occurred from arterial insufficiency or secondary to venous insufficiency⁽⁵⁾. To avoiding the entire ischemic complications, enhanced both arterial and venous vascularization should be considered^(6,7). If these procedures were planned, they did not take so more time. Only selected longer distal pedicle and anatomizes to local vessels at same neck incision of pharyngeal anastomosis.

Vascular anastomosis can be done under microscopic or loupe magnifications. These vascular skills can be performed by general surgeons. Importance

successful techniques were distal vascular pedicle need meticulous dissected and longest as possible and proper donor vessels preparation for the vascular anastomosis can be easily done in the operative neck field.

Choices of donor artery were transverse cervicalis, superior thyroid, facial artery. Because of in the most case, the pulled-up colons had lots of surrounding adipose tissue. Transverse cervicalis artery was preferred because of their length and easy harvest. The artery is rather reliable fixed anatomic position. It lay on prevertebral fascia (fascial carpet), easily found on scalenus medius muscle before to feed trapezius muscle. Its diameter is proportion to colonic artery. With its enough length, the anastomosis can clearly be performed in out of colonic adipose tissue disturbance. For choices of donor vein, external jugular vein was preferred. This vein places in subcutaneous layer and mobilized and avoid for its clicking. In some cases external jugular vein were damaged from previous operations, internal jugular veins were suggested as end-to-side anastomosis. The bowl veins were rather thin, finished anastomosis were always fully checked especial about double wall suture.

Vascular anastomosis should be done before pharyngeal anastomosis. Good signs of good enhanced vascularization were dark colored arterial bleeding change to be bright colored, swelling mucosa were shrunken and diminished of mucous producing.

In these series, there were no incidence of major anastomotic leakage or late anastomotic stricture.

Comparison to previous pedicle colon interposition in the other report, more operative time but less complications⁽⁸⁾.

On the other hand, other esophageal reconstructions such as gastric pull up or extended colon interposition; if poor blood flow is suspected, augmentation of microvascular blood flow by this technique can be expected to reduce the risk of leakage and partial necrosis⁽⁹⁻¹¹⁾.

Conclusion

The report showed that using supercharged interposition colon in adult esophageal reconstruction in corrosive and Boehave's injury was benefit in lower the incidence of anastomotic leakage and late anastomotic stricture. Just a longer operative time and vascular anatomizes skill were need.

References

1. Peters JH, Kronson JW, Katz M, DeMeester TR. Arterial anatomic considerations in colon interposition for esophageal replacement. Arch Surg 1995; 130: 858-62.
2. Noguchi T, Uchida Y, Hashimoto T, Wada S, Suko T, Suzuki M. Reconstruction of the cervical esophagus by interposition of the transverse colon. Nippon Geka Gakkai Zasshi 2001; 102: 647-52.
3. Wormuth JK, Heitmiller RF. Esophageal conduit necrosis. Thorac Surg Clin 2006; 16: 11-22.
4. Gupta NM, Gupta R. Transhiatal esophageal re-

section for corrosive injury. Ann Surg 2004; 239: 359-63.

5. Patel HD, Chen YC, Chen HC. Salvage of right colon interposition by microsurgical venous anastomosis. Ann Thorac Surg 2002; 74: 921-3.
6. Ueda K, Kajikawa A, Suzuki Y, Okazaki M, Nakagawa M, Iida S. Blood gas analysis of the jejunum in the supercharge technique: to what degree does circulation improve? Plast Reconstr Surg 2007; 119: 1745-50.
7. Shirakawa Y, Naomoto Y, Noma K, Sakurama K, Nishikawa T, Nobuhisa T, et al. Colonic interposition and supercharge for esophageal reconstruction. Langenbecks Arch Surg 2006; 391: 19-23.
8. Cerfolio RJ, Allen MS, Deschamps C, Trastek VF, Pairolero PC. Esophageal replacement by colon interposition. Ann Thorac Surg 1995; 59: 1382-4.
9. Sekido M, Yamamoto Y, Minakawa H, Sasaki S, Furukawa H, Sugihara T, et al. Variation of microvascular blood flow augmentation—supercharge in esophageal and pharyngeal reconstruction. Rozhl Chir 2006; 85: 9-13.
10. Lu HI, Kuo YR, Chien CY. Extended left colon interposition for pharyngoesophageal reconstruction using distal-end arterial enhancement. Microsurgery 2008; 28: 424-8.
11. Wain JC, Wright CD, Kuo EY, Moncure AC, Wilkins EW Jr, Grillo HC, et al. Long-segment colon interposition for acquired esophageal disease. Ann Thorac Surg 1999; 67: 313-7.

ผลการผ่าตัดสร้างทดแทนหลอดอาหารด้วยลำไส้ใหญ่แบบต่อเส้นเลือดเลี้ยงเพิ่มในผู้ป่วยวัย กลืนสารกัดกร่อน และการบาดเจ็บชนิด Boehave ประสบการณ์ในโรงพยาบาลธรรมศาสตร์ เฉลิมพระเกียรติ

สรุจิต อวสกุลสุทธิ

เป็นการรายงานผลการรักษาผู้ป่วยจำนวน 7 คน ที่สูญเสียหลอดอาหารจากการกลืนสารกัดกร่อน และการบาดเจ็บชนิด Boehave ในโรงพยาบาลธรรมศาสตร์เฉลิมพระเกียรติด้วยการผ่าตัดสร้างทดแทน หลอดอาหารด้วยลำไส้ใหญ่ แบบมีการผ่าตัดต่อเส้นเลือดเลี้ยงเพิ่ม (Supercharge) ผลการรักษาดีมีรอยรั่วขนาดเล็กของรอยต่อบริเวณคอหอยในผู้ป่วยหนึ่งคนซึ่งสามารถหายได้เอง และจากการติดตามผลการรักษา ไม่พบการตีบตันของรอยต่อส่วนทดแทนหลอดอาหาร แม้ศัลยแพทย์จำเป็นต้องมีทักษะทางด้านการต่อเส้นเลือด และใช้เวลาผ่าตัดเพิ่มขึ้น แต่มีประโยชน์หลังการผ่าตัดในการลดอุบัติการณ์การรั่วและการตีบตันของรอยต่อส่วน ทดแทนหลอดอาหาร