

# Case Report

## Left Sided Inferior Vena Cava: A Case Report

Kimaporn Khamanarong MD\*,  
Worawut Woraputtaporn MSc\*, Supawadee Teerakul MSc\*,  
Parichat Prachaney PhD\*, Pattama Amarttayakong MSc\*

\* Department of Anatomy, Faculty of Medicine, Khon Kaen University, Khon Kaen, Thailand

---

**Objective:** To report a case of left sided inferior vena cava (IVC).

**Material and Method:** The authors carried out the standard dissection survey of 939 embalmed cadavers between 1974 and 2008.

**Results:** The authors encountered a case of left sided IVC in a male donated cadaver aged 65 years at decease. The IVC formed behind the left common iliac artery at the L5 vertebra and coursed proximally on the left of the aorta until it reached the left renal vein and then crossed anterior to the abdominal aorta to assume the normal right side. At the point of crossing, it received the left renal vein. The right renal vein emptied into the IVC on the right side.

**Conclusion:** In the era of laparoscopic urological surgery, preoperative diagnosis of this uncommon but important entity is essential to prevent unwarranted surgical mishaps.

**Keywords:** Left sided inferior vena cava, Common iliac vein

*J Med Assoc Thai* 2010; 93 (8): 998-1000

**Full text. e-Journal:** <http://www.mat.or.th/journal>

---

Normally, the inferior vena cava (IVC) arises by the junction of right and left common iliac veins, slightly below the level of the bifurcation of the aorta and between the right common iliac artery anteriorly and the fifth lumbar vertebra posteriorly. Congenital anomalies of the IVC are rare and occur in approximately 3% of the population<sup>(1)</sup>. Transposition of the IVC, in which it lies to the left of the aorta, occurs in 0.2-0.5% of the population<sup>(2,3)</sup>. The vascular malformation is of immense surgical importance, especially during surgery of abdominal aorta and great concerns in candidates for kidney donation.

### Material and Method

The authors carried out 939 embalmed Thai cadavers between 1974 and 2008. The standard dissection techniques were carefully employed. The student dissections were clearly supervised by the experienced anatomists.

---

### Correspondence to:

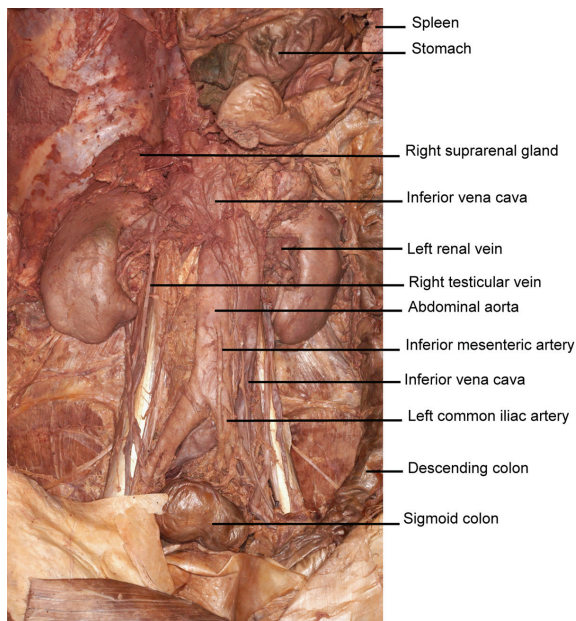
Khamanarong K, Department of Anatomy, Faculty of Medicine, Khon Kaen University, Khon Kaen 40002, Thailand.  
Phone: 043-348-381, Fax: 043-348-381  
E-mail: [kkipap@kku.ac.th](mailto:kkipap@kku.ac.th) or [kkipap@yahoo.com](mailto:kkipap@yahoo.com)

### Results

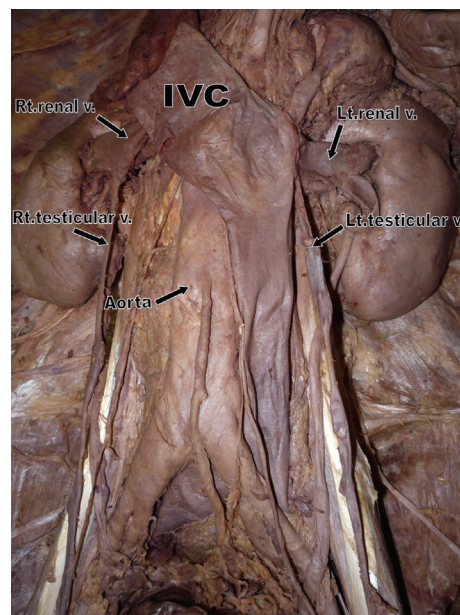
The left sided IVC was found (Fig. 1, 2). After removing the loose connective tissue and fat, the authors could see clearly that the common iliac veins from both sides joined behind the left common iliac artery on L5 vertebra to form the distalmost segment of the IVC. The left IVC, so formed, ran superiorly along the left side of the abdominal aorta to the point of entrance to the IVC of the left renal vein. From this point, the IVC crossed the midline obliquely upward to the right side, assuming its normal relationship to the aorta. The left suprarenal vein emptied into the IVC. The right renal and suprarenal veins emptied into the right side of IVC. The superior and inferior mesenteric arteries are above and below the crossing segment of the IVC, respectively. Because of the variation, the right testicular vein emptied into the right renal vein; the left testicular vein into the left sided IVC. The remainder of the caval pathway was normal and after receiving the hepatic vein, it entered into the right atrium as its normal site.

### Discussion & Conclusion

The left sided IVC is proposed to be compatible with life. Becker<sup>(5)</sup> found a case of the left sided IVC from autopsy. Nasser et al<sup>(4)</sup> found three



**Fig. 1** Photograph of the posterior abdominal wall showing the great vessels and certain organs. The inferior vena cava (IVC) lies to the left of the left common iliac artery, then ascends along the left side of the aorta, and finally curves to the right at the level of the entrance of the left renal vein into the IVC



**Fig. 2** A clearer picture of the left sided inferior vena cava (IVC) after removal of some fibrous connective tissue. Note that the left renal and testicular veins drain into the left sided IVC and the right testicular vein into the right renal vein which finally empties into the right side of IVC

cases of the left sided IVC in 750 kidney donors for transplantation. The incidence in the present series is 0.4% by way of laparoscopic donor nephrectomy. Honma et al<sup>(6)</sup> also found one in 456 cases (0.22%). This report of Khon Kaen University, Faculty of Medicine, Department of Anatomy is even smaller, only 1 in 939 cases (0.1%), but comparable though secured by different method. The caval pathway as reported by Becker, Nasser et al, Honma et al and the present study was not different.

In the normal development of the IVC of about 4-7 week embryo, the right subcardinal vein and the iliac anastomosis of subcardinal veins developed to be the distal segment of the IVC<sup>(2)</sup>. However, in the present case the left subcardinal vein persisted, instead of obliterated, and developed into the left sided IVC. The cross segment of this case, IVC persisted from the intersubcardinal anastomosis, which became renal segment of IVC, to connect with the hepatic segment of IVC. Now, the IVC was in the normal position, connecting with the cardiac segment, which was the remainder of the right vitelline vein to become the

uppermost segment of IVC, which was emptying into the inferior part of the right atrium.

The major clinical significance of this anomaly is a potential for misdiagnosis as a left sided paraaortic adenopathy. Surgical procedures involving the retroperitoneum are more complex with a left sided IVC, the possibility of confusion of the anomaly with lymphadenopathy, tumor, or a dilated gonadal vein may lead to severe iatrogenic hemorrhage<sup>(7-9)</sup>.

Furthermore, in the process of laparoscopic donor nephrectomy, the practicing physicians and surgeons should be well aware of this mal-positioned variation of the left sided IVC for the management of aneurysm of the abdominal aorta and common iliac arteries and other relating organs in the abdomen and pelvis to achieve a successful operation.

In conclusion, the authors have reported a case of left sided IVC with the incidence of one out of 939 cadavers (0.1%) in the male cadaver. The surgeons performing kidney transplants or working in the full-of-surprise abdomen must keep this left sided IVC in mind.

## Acknowledgements

The authors thank Emeritus Professor Dr. Somboon SrungBoonmee who patiently prepared this manuscript. Thanks are also due to the dead teachers who have taught us.

## References

1. Alexander ES, Clark RA, Gross BH, Colley DP. CT of congenital anomalies of the inferior vena cava. *Comput Radiol* 1982; 6: 219-26.
2. Mayo J, Gray R, St Louis E, Grosman H, McLoughlin M, Wise D. Anomalies of the inferior vena cava. *AJR Am J Roentgenol* 1983; 140: 339-45.
3. Agran MR, Kratzman EA. Inferior vena cava on the left side: its relationship to the right ureter. Report of a case. *J Urol* 1969; 101: 149-51.
4. Simforoosh N, Beigi FM, Aminsharifi A, Shayaninasab H, Mehrabi S. Left-sided inferior vena cava found incidentally during laparoscopic donor nephrectomy: report of three cases. *J Endourol* 2007; 21: 542-4.
5. Becker FF. A singular left sided inferior vena cava. *Anat Rec* 1962; 143: 117-20.
6. Honma S, Tokiyoshi A, Kawai K, Koizumi M, Kodama K. Left inferior vena cava with regressed right inferior vena cava. *Anat Sci Int* 2008; 83: 173-8.
7. Rispoli P, Raso AM, Trogolo M, Maggio D, Bellan A. Left-sided inferior vena cava. Report of a case occasionally encountered while performing an aorto bifemoral bypass and review of the literature. *J Cardiovasc Surg (Torino)* 1997; 38: 489-93.
8. Knudtson J, Svane S. Left-sided inferior vena cava. A peroperatively demonstrated case. *Acta Chir Scand* 1986; 152: 547-9.
9. Forster J, Biyani CS, Weston PM. A gentle reminder in the laparoscopic era left-sided inferior vena cava. *Int Urol Nephrol* 2006; 38: 439-42.

---

## หลอดเลือดดำอินฟีเรียร์วีนา คาวา ด้านซ้าย: รายงาน 1 ร้าง

กิมพร ชมะณะรงค์, วรวิฒิ วรพุทธพร, สุภาวดี ธีระกุล, ปาริฉัตร ประจจะเนย์, ปัทมา อมาตยคง

**วัตถุประสงค์:** เพื่อรายงานหลอดเลือดดำอินฟีเรียร์วีนา คาวา ด้านซ้ายในอาจารย์ใหญ่ 1 ร้าง

**วัสดุและวิธีการ:** ซ้ำแหล่งศพปริภาค จำนวน 939 ร้าง ระหว่าง พ.ศ. 2517-2551

**ผลการศึกษา:** พบหลอดเลือดดำอินฟีเรียร์วีนา คาวา ด้านซ้ายในศพเพศชาย อายุ 65 ปี เมื่อเสียชีวิต หลอดเลือดดำอินฟีเรียร์วีนา คาวา เริ่มที่ระดับกระดูกสันหลังส่วนเอวชั้นที่ 5 หลังหลอดเลือดแดงคอมมอน อิลลิแอ็ก ข้างซ้าย จากนั้นจึงทอดตัวขึ้นข้างบนโดยอยู่ทางด้านซ้ายของเอออร์ตา เมื่อถึงระดับหลอดเลือดดำไตข้างซ้าย หลอดเลือดดำอินฟีเรียร์วีนา คาวา พาดข้ามเอออร์ตาไปอยู่ทางด้านขวา หลอดเลือดดำไตข้างซ้ายสิ้นสุดที่หลอดเลือดดำอินฟีเรียร์วีนา คาวา ตรงบริเวณที่ข้ามเอออร์ตา หลอดเลือดดำไตข้างขวาสิ้นสุดที่ด้านขวาของหลอดเลือดดำอินฟีเรียร์วีนา คาวา

**สรุป:** ในยุคของศัลยศาสตร์ระบบทางเดินปัสสาวะที่มีการตรวจช่องท้องด้วยกล้องส่อง การคำนึงถึงความผิดปกติที่ผู้ป่วยอาจมีอย่างเช่นกรณีนี้จะช่วยป้องกันความผิดพลาดในระหว่างการทำหัตถการ