

Identification of the External Laryngeal Nerve: Its Anatomical Relations to Inferior Constrictor Muscle, Superior Thyroid Artery, and Superior Pole of the Thyroid Gland in Thais

Pongpeera Taytawat MD*,
Yadaridee Viravud DDS, MS*, Vasana Plakornkul DVM, MS*,
Jantima Roongruangchai DDS, PhD*, Chayanit Manoonpol MS*

* Department of Anatomy, Faculty of Medicine, Siriraj Hospital, Mahidol University, Bangkok, Thailand

Background: The external laryngeal nerve (ELN) is not routinely identified during thyroid surgery despite clear benefits from doing so. One reason is its anatomical variations, which differ from papers to papers. There were also very few studies of ELN in Thais, especially its relation to inferior constrictor muscle and tip of superior pole of the thyroid gland, which serve as important landmarks when identifying the ELN intraoperatively.

Objective: To describe the course of ELN and its relations to the inferior constrictor muscle, superior thyroid artery (STA), and tip of superior pole of the thyroid gland in Thais in order to serve as a guide for identification and preservation of the nerve.

Material and Method: One hundred thirty four ELNs from 68 cadavers with normal-sized thyroid glands and no signs of neck abnormality were studied. Three areas were studied, (1) its relation to inferior constrictor muscle, (2) the nearest distance from the nerve to tip of the superior pole of the thyroid gland, and (3) the crossing point of the ELN and STA in relation to the tip of the superior pole of the thyroid gland. All distances were measured in mm using a vernier caliper.

Results: The three areas of the study were reported separately using established classifications and compared to the previous published papers. All ELNs run superficially, at the least on the upper portion of the inferior constrictor muscle, rendering it more vulnerable to injury in Thais.

Conclusion: The course of the ELN and its relations to nearby structures can vary considerably and are influenced by many factors. Nevertheless, these findings should encourage the surgeons to identify the ELN intraoperatively with meticulous dissection to minimize the risk of ELN injury.

Keywords: External laryngeal nerve, Inferior constrictor muscle, Superior thyroid artery, Thyroid surgery

J Med Assoc Thai 2010; 93 (8): 961-8

Full text. e-Journal: <http://www.mat.or.th/journal>

Thyroid surgery is one of the most commonly performed operative procedures in head and neck surgery worldwide⁽¹⁾. Voice change, a common complication after thyroid surgery, can be caused by injury to either the external laryngeal nerve (ELN) or recurrent laryngeal nerve (RLN), which is routinely identified in the operative field⁽²⁾. Despite this fact, surgeons still try to avoid ELN rather than identify and preserve it. Evidence shows that by identifying it,

the incidence of post-operative permanent voice change decreased from 25% to 5%⁽²⁻⁵⁾. One reason why surgeons failed to identify it is that the anatomical variations differ from paper to paper⁽⁵⁻¹³⁾. Damage to the ELN affects the cricothyroid muscle with a resulting inability to lengthen the vocal cord. This can lead to a weak, hoarse^(14,15), easily fatigued^(16,17) voice and loss of high-pitch phonation^(2,16,18-20). Even though injury to the ELN may not cause devastating outcomes compared to the RLN, in some occupations such as singers, speakers, or teachers can suffer tremendously from these avoidable complications.

The superior laryngeal nerve gives rise to two branches *i.e.*, internal and external branches at the

Correspondence to:

Viravud Y, Department of Anatomy, Faculty of Medicine Siriraj Hospital, Mahidol University, Bangkok 10700, Thailand.
Phone: 0-2419-7035, Fax: 0-2419-8523
E-mail: siyvv@mahidol.ac.th

level of superior cornu of the hyoid bone⁽²¹⁾. The internal laryngeal nerve is larger than and is situated superiorly to the ELN. Hence, the chance of injury to this nerve is less likely^(2,21,22). On the other hand, the ELN, also known as “high note nerve”, is vulnerable during thyroid surgery because of its intimate relationship to the superior thyroid artery (STA), which is the only artery on the superior pole of the thyroid gland. The ELN runs posteromedially parallel to the artery and crosses over inferior constrictor muscle along the lower border of the oblique line of thyroid cartilage⁽²²⁾. In most cases, it would then pierce this muscle before innervating cricothyroid muscle. In up to 22% of cases, the nerve lies superficially along the whole length of the inferior constrictor muscle without piercing it^(19,23,24).

While reaching the superior pole of thyroid gland, the STA and ELN cross each other. The STA runs deep to pretracheal fascia (also called thyroid sheath or false capsule of the thyroid gland) and the ELN runs superficial to it^(18,25).

The objective of the present study was to describe the anatomical relations of the ELN, STA, and tip of the superior pole of the thyroid gland, particularly the distance between the crossing point of the ELN and STA, which is considered the “dangerous” area while ligating the vessels during thyroid surgery. Furthermore, this study will show the anatomical variations of the ELN as it crosses the inferior constrictor muscle in Thais.

Material and Method

Sixty-eight embalmed cadavers with normal-sized thyroid glands and no signs of neck abnormality from the Department of Anatomy, Faculty of Medicine Siriraj Hospital were meticulously dissected using anatomical approach. The present study consisted of 34 male cadavers (range: 32-96 years old) with 68 ELNs (n = 68) and 34 female cadavers (range: 38-100 years old) with 66 ELNs (n = 66). Despite extensive search, right ELNs in two of the female cadavers were not seen. The present study was conducted in three separate parts, based on the relations of ELN to the nearby structures.

Part 1 focuses on three possible variations of the ELN in relation to the inferior constrictor muscle using classification described by Friedman et al⁽²⁶⁾ for the purpose of identification of the nerve in the operative field.

Type 1: ELN runs the whole course superficially to the muscle thus, the nerve is most vulnerable to injury during thyroid surgery.

Type 2: ELN penetrates the lower portion of the inferior constrictor muscle thus, the nerve is partially protected by the muscle.

Type 3: ELN runs the whole course deeply in the muscle thus, the nerve is fully protected until it reaches the cricothyroid muscle.

Part 2 measures the shortest (perpendicular) distance from the tip of the superior pole of the thyroid gland to the ipsilateral ELN in mm [SDTN] using a vernier caliper (Fig. 1).

Part 3 studies the crossing point of the ELN and STA in relation to the tip of the superior pole of the thyroid gland. This part is subdivided into two categories.

1) Using Cernea et al classification⁽¹³⁾, this category focuses on three variations of the ELN (Fig. 2).

Type 1: ELN crosses STA ≥ 10 mm superior to the tip of the superior pole of the thyroid gland.

Type 2: ELN crosses STA < 10 mm the superior or inferior to the tip of the superior pole of the thyroid gland, type 2a: the crossing point is < 10 mm superior to the tip of the superior pole of the thyroid gland, and type 2b: the crossing point is inferior to the tip of the superior pole of the thyroid gland.

2) Measuring the shortest distance from the crossing point of the ELN and STA and tip of the superior pole of the thyroid gland in mm [SDTC] using a vernier caliper (Fig. 1).

Statistical analysis

Descriptive statistics was used for analysis of the data. Chi-square test or Fisher’s exact test were used to compare categorical data, unpaired t-test was used to compared between mean \pm SD of male and female, and Paired t-test was used to compare mean \pm SD within the same sex. P-value of less than 0.05 was considered statistical significant.

Results

Part 1. Applying Friedman et al classification, the ELNs were consistent with type 1 in 94.8%, type 2 in 5.2%, and type 3 in 0% (Table 1). Using Chi-square independence test, the authors found that different types were not affected by genders on both sides (p = 0.519 on the right and p = 1.000 on the left).

Part 2. The mean shortest distance from the tip of the superior pole of the thyroid gland to the ipsilateral ELN is 6.65 ± 3.05 mm (range: 3.00-18.00 mm) on the right and 7.26 ± 2.96 mm (range: 3.00-19.00 mm) on the left (Table 2). There were no ELNs running over

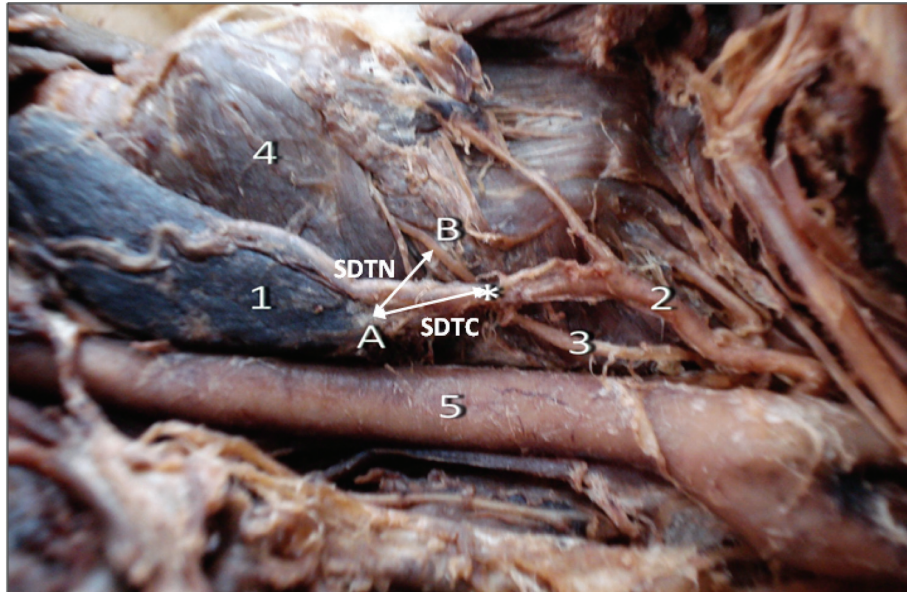


Fig. 1 Dissection of the left lobe of the thyroid gland (1) showing SDTN, the shortest distance from tip of superior pole of the thyroid gland (A) to the ipsilateral ELN (B) and SDTC, the shortest distance from (A) to the crossing point of the ELN and STA (asterisk); 2, STA; 3, ELN; 4, cricothyroid muscle; 5, common carotid artery

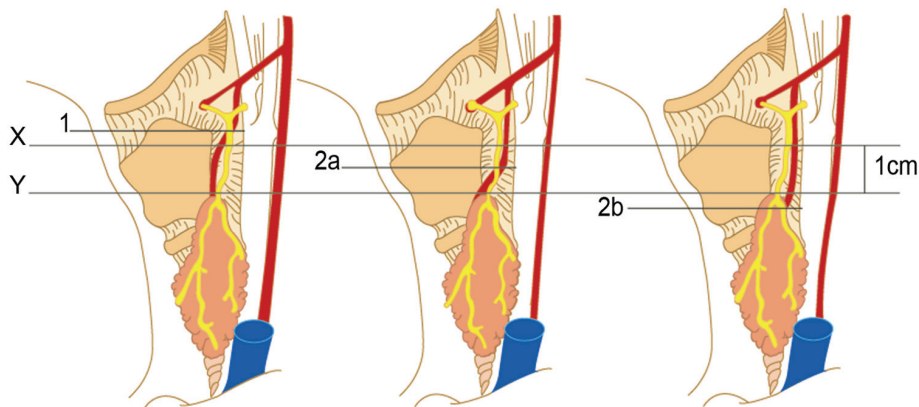


Fig. 2 Simplified diagram showing different types of ELN according to Cernea et al. classification⁽¹³⁾, X plane 1 cm. superior to the tip of superior pole of the thyroid gland, Y plane at level of the tip of superior pole of the thyroid gland. Type 1, ELN crosses the STA superiorly to X; Type 2a, ELN crosses STA between X and Y; Type 2b, ELN crosses STA inferiorly to Y

or below the tip of the superior pole of the thyroid gland. When using a 90% coverage of the sample size, a range from 3.00 mm (5th percentile) to 13.65 mm (95th percentile) on the right and 4.00 mm (5th percentile) to 13.10 mm (95th percentile) on the left (Table 3). Using unpaired t-test, no statistical significance between genders was found on the right ($p = 0.681$) and left ($p = 0.685$). As for the same gender using paired

t-test, there was also no statistical significance found between both sides in males ($p = 0.115$) and females ($p = 0.775$).

Part 3. Applying Cernea et al classification, the ELNs were consistent with type 1 in 91.8% and type 2 in 8.2%; all of which were type 2a and no type 2b (Table 4). Using Chi-square independence test, the authors found that different types were not affected

Table 1. Percentages of different types of ELN based on Friedman et al classification⁽²⁷⁾

Right (n = 66)	Type 1	Type 2	Type 3	Left (n = 68)	Type 1	Type 2	Type 3
Males	33	1	0	Male	32	2	0
Females	30	2	0	Female	32	2	0
Total (%)	63 (95.5%)	3 (4.5%)	0 (0%)	Total (%)	64 (94.1%)	4 (5.9%)	0 (0%)

Table 2. Descriptive statistics of the ELN in this study (all measurements are in mm)

	SDTN-Rt*	SDTN-Lt*	SDTC-Rt**	SDTC-Lt**
Count	66	68	66	68
Mean \pm SD	6.65 \pm 3.05	7.26 \pm 2.96	16.12 \pm 4.91	16.69 \pm 6.10
Male	6.50 \pm 2.43	7.41 \pm 2.26	15.91 \pm 4.85	16.79 \pm 5.87
Female	6.81 \pm 3.63	7.12 \pm 3.56	16.34 \pm 5.05	16.59 \pm 6.41
Median	6.00	7.00	16.00	16.00
Minimum	3.00	3.00	8.00	6.00
Maximum	18.00	19.00	33.00	31.00
Percentiles 5 th	3.00	4.00	9.00	8.00
25 th	4.00	5.00	13.00	12.00
50 th	6.00	7.00	16.00	16.00
75 th	8.00	8.75	18.25	22.00
95 th	13.65	13.10	25.95	29.00

* SDTN-Rt and SDTN-Lt indicate the shortest distance from tip of superior pole of the thyroid gland to the ipsilateral ELN on the right and left, respectively

** SDTC-Rt and SDTC-Lt indicate the shortest distance from tip of superior pole of the thyroid gland to the crossing point of ELN and STA on the right and left, respectively

Table 3. Frequency distribution of SDTN* categorized by percentiles

Ranges of percentiles	Right (n = 66)	Ranges of percentiles	Left (n = 68)
\leq 5 th percentile (\leq 3.00 mm)	5	\leq 5 th percentile (\leq 4.00 mm)	10
5 th -25 th percentile ($>$ 3.00- \leq 4.00 mm)	13	5 th -25 th percentile ($>$ 4.00- \leq 5.00 mm)	11
25 th -50 th percentile ($>$ 4.00- \leq 6.00 mm)	22	25 th -50 th percentile ($>$ 5.00- \leq 7.00 mm)	18
50 th -75 th percentile ($>$ 6.00- \leq 8.00 mm)	12	50 th -75 th percentile ($>$ 7.00- \leq 8.75 mm)	12
75 th -95 th percentile ($>$ 8.00- \leq 13.65 mm)	11	75 th -95 th percentile ($>$ 8.75- \leq 13.10 mm)	14
$>$ 95 th percentile ($>$ 13.65 mm)	3	$>$ 95 th percentile ($>$ 13.10 mm)	3

* SDTN indicates the shortest distance from tip of superior pole of the thyroid gland to the ipsilateral ELN

Table 4. Percentages of different types of ELN based on Cernea et al classification⁽¹³⁾

Right (n = 66)	Type 1	Type 2a	Type 2b	Left (n = 68)*	Type 1	Type 2a	Type 2b
Male	32	2	0	Male	31	2	0
Female	29	3	0	Female	30	4	0
Total (%)	61 (92.4%)	5 (7.6%)	0 (0%)	Total (%)	61 (89.7%)	6 (8.8%)	0 (0%)

* One of the ELNs ran parallel to STA

by genders on both sides ($p = 0.592$ on the right and $p = 0.414$ on the left).

The mean shortest distance from the tip of the superior pole of the thyroid gland to the crossing point of ELN and STA is 16.12 ± 4.91 mm (range: 8.00-33.00 mm) on the right and 16.69 ± 6.10 mm (range: 6.00-31.00 mm) on the left (Table 2). Using unpaired t-test, no statistical significance between genders was found on the right ($p = 0.724$) and left ($p = 0.895$). As for the same gender using paired t-test, there was also no statistical significance found between both sides in males ($p = 0.253$) and females ($p = 0.882$).

Discussion

The course of ELN and its associations with nearby structures, specifically the inferior constrictor muscle, STA, and tip of the superior pole of the thyroid gland, which are considered clinically important landmarks, are poorly studied in Thais. The data obtained from the present study were compared to previous published papers using various established classifications in order to subgroup the populations and possibly serve as guidance for preservation of ELN during thyroid surgery.

Based on the results from part 1 using Friedman el at classification, there were no type 3 nerves found. This points to the fact that most, if not all, of the ELN are identifiable, at the least, on the upper portion of the inferior constrictor muscle. In other words, the lack of type 3 nerves in Thais indicates the absence of protection from the inferior constrictor muscle rendering it vulnerable to injury.

By measuring the SDTN, the authors found that the distance could vary considerably from 3.00-18.00 mm on the right and 3.00-19.00 mm on the left. The risk of injuring the ELN may be even greater in cases with enlarged thyroid glands in which these lower limits can become much smaller. In Thais, this close proximity is even more noticeable on the left when comparing the results from Naidoo et al⁽²⁴⁾ (The SDTN that is the 5th percentile or less on the right [< 2.78 mm] and left [< 3.49 mm] were 7.32% and 6.98%, respectively) to the present study (The SDTN that is the 5th percentile or less on the right [< 3.00 mm] and left [< 4.00 mm] were 7.58% and 14.71%, respectively). Even though there was no statistical significance between both sides in both genders, caution should be taken when ligating the superior thyroid vessels especially on the left to avoid ELN injury.

Based on the presented knowledge, it is prudent to stay as close to the substance of the

thyroid gland as possible when ligating the superior thyroid vessels during thyroid surgery⁽²⁷⁾. It is even recommended to leave the capsule covering the superior pole of the thyroid gland intact when removing the gland in order to minimize the risk of ELN injury⁽²⁴⁾.

According to Cernea et al. classification, type 2a and 2b nerves are classically described as "high-risk nerves" of iatrogenic origin during thyroid surgery due to their low-lying course^(10,13,28). The present study shows apparently fewer of these high-risk nerves in Thais compared to the results from Seven et al⁽²⁹⁾. The ethnicities, body sizes, diets, and climate temperatures may play some roles in these differences. Nevertheless, there was clear evidence from the studies of Cernea et al⁽¹⁰⁾ that the ELN are in greater danger if the size of the thyroid was taken into account (Table 5). To further emphasize the concept, Aina and Hisham also reported the type 2 nerves in 92.3% and 66.6% of goiters weighing more than 100 gm and less than 100 gm, respectively⁽²⁸⁾.

When using 90% coverage of the sample size in the measurements of SDTC, a range from 9.00 mm (5th percentile) to 25.95 mm (95th percentile) on the right and 8.00 mm (5th percentile) to 29.00 mm (95th percentile) on the left were found. The lower ranges of these distances are considerably large compared to the SDTN. This and the fact that there were no type 2b nerves confirm that the concept of staying on the substance of the thyroid gland still applies.

Conclusion

The course of the ELN and its relations to nearby structures can vary considerably and are influenced by many factors, which must be taken into

Table 5. Comparison of different types of ELN based on Cernea et al. classification following this study (Taytawat et al 2009) and the previous studies (Cernea et al 1992⁽³⁰⁾ and Seven et al 2003⁽³²⁾)

Types	Cernea et al 1992*		Seven et al 2003**	Taytawat et al 2009**
	SG	LG		
Type 1	68%	23%	51.8%	91.8%
Type 2a	11%	15%	37.1%	8.2%
Type 2b	14%	54%	11.1%	0%

* Clinical study

** Cadaver studies of normal-sized thyroid glands

SG = small goiters; LG = large goiters

account when performing a thyroid surgery. These findings should encourage the surgeons to identify the ELN intraoperatively. Meticulous dissection is of utmost importance to minimize the risk of ELN injury. The present study urges the surgeons to stay as close to the substance of the thyroid gland as possible when ligating the superior thyroid vessels and even leave the capsule covering the superior pole of the thyroid gland intact when removing the gland.

The present study should enhance the authors overall understanding about variations of the ELN in Thais in order to minimize this preventable complication.

Acknowledgements

The authors want to thank the Department of Anatomy, Faculty of Medicine, Siriraj Hospital, Mahidol University, Bangkok, Thailand for the cadavers used in the present study.

References

1. Foster RS Jr. Morbidity and mortality after thyroidectomy. *Surg Gynecol Obstet* 1978; 146: 423-9.
2. Kark AE, Kissin MW, Auerbach R, Meikle M. Voice changes after thyroidectomy: role of the external laryngeal nerve. *Br Med J (Clin Res Ed)* 1984; 289: 1412-5.
3. Jonas J, Bahr R. Neuromonitoring of the external branch of the superior laryngeal nerve during thyroid surgery. *Am J Surg* 2000; 179: 234-6.
4. Lore JM Jr, Kokocharov SI, Kaufman S, Richmond A, Sundquist N. Thirty-eight-year evaluation of a surgical technique to protect the external branch of the superior laryngeal nerve during thyroidectomy. *Ann Otol Rhinol Laryngol* 1998; 107: 1015-22.
5. Lennquist S, Cahlin C, Smeds S. The superior laryngeal nerve in thyroid surgery. *Surgery* 1987; 102: 999-1008.
6. Kierner AC, Aigner M, Burian M. The external branch of the superior laryngeal nerve: its topographical anatomy as related to surgery of the neck. *Arch Otolaryngol Head Neck Surg* 1998; 124: 301-3.
7. Cernea CR, Nishio S, Hojaij FC. Identification of the external branch of the superior laryngeal nerve (EBSLN) in large goiters. *Am J Otolaryngol* 1995; 16: 307-11.
8. Wu BL, Sanders I, Mu L, Biller HF. The human communicating nerve. An extension of the external superior laryngeal nerve that innervates the vocal cord. *Arch Otolaryngol Head Neck Surg* 1994; 120: 1321-8.
9. Sanders I, Wu BL, Mu L, Li Y, Biller HF. The innervation of the human larynx. *Arch Otolaryngol Head Neck Surg* 1993; 119: 934-9.
10. Cernea CR, Ferraz AR, Furlani J, Monteiro S, Nishio S, Hojaij FC, et al. Identification of the external branch of the superior laryngeal nerve during thyroidectomy. *Am J Surg* 1992; 164: 634-9.
11. Moosman DA, DeWeese MS. The external laryngeal nerve as related to thyroidectomy. *Surg Gynecol Obstet* 1968; 127: 1011-6.
12. Durham CF, Harrison TS. The surgical anatomy of the superior laryngeal nerve. *Surg Gynecol Obstet* 1964; 118: 38-44.
13. Cernea CR, Ferraz AR, Nishio S, Dutra A Jr, Hojaij FC, dos Santos LR. Surgical anatomy of the external branch of the superior laryngeal nerve. *Head Neck* 1992; 14: 380-3.
14. Lore JM Jr. Surgery of the thyroid gland. *Otolaryngol Clin North Am* 1980; 13: 69-83.
15. Moran RE, Castro AF. The superior laryngeal nerve in thyroid surgery. *Ann Surg* 1951; 134: 1018-21.
16. Lekacos NL, Miligos ND, Tzardis PJ, Majiatis S, Patoulis J. The superior laryngeal nerve in thyroidectomy. *Am Surg* 1987; 53: 610-2.
17. Aluffi P, Policarpo M, Cherovac C, Olina M, Dosdegani R, Pia F. Post-thyroidectomy superior laryngeal nerve injury. *Eur Arch Otorhinolaryngol* 2001; 258: 451-4.
18. Monfared A, Gorti G, Kim D. Microsurgical anatomy of the laryngeal nerves as related to thyroid surgery. *Laryngoscope* 2002; 112: 386-92.
19. Bellantone R, Boscherini M, Lombardi CP, Bossola M, Rubino F, De Crea C, et al. Is the identification of the external branch of the superior laryngeal nerve mandatory in thyroid operation? Results of a prospective randomized study. *Surgery* 2001; 130: 1055-9.
20. Poyraz M, Calguner E. Bilateral investigation of the anatomical relationships of the external branch of the superior laryngeal nerve and superior thyroid artery, and also the recurrent laryngeal nerve and inferior thyroid artery. *Okajimas Folia Anat Jpn* 2001; 78: 65-74.
21. Monfared A, Kim D, Jaikumar S, Gorti G, Kam A. Microsurgical anatomy of the superior and recurrent laryngeal nerves. *Neurosurgery* 2001; 49: 925-32.
22. Moore KL. The neck. In: Moore KL, editor.

- Clinically oriented anatomy. 3rd ed. Baltimore: Williams and Wilkins; 1992: 783-875.
23. Friedman M, LoSavio P, Ibrahim H. Superior laryngeal nerve identification and preservation in thyroidectomy. *Arch Otolaryngol Head Neck Surg* 2002; 128: 296-303.
 24. Kambic V, Zargi M, Radsel Z. Topographic anatomy of the external branch of the superior laryngeal nerve. Its importance in head and neck surgery. *J Laryngol Otol* 1984; 98: 1121-4.
 25. Karlan MS, Catz B, Dunkelman D, Uyeda RY, Gleischman S. A safe technique for thyroidectomy with complete nerve dissection and parathyroid preservation. *Head Neck Surg* 1984; 6: 1014-9.
 26. Naidoo D, Boon JM, Miény CJ, Becker PJ, van Schoor AN. Relation of the external branch of the superior laryngeal nerve to the superior pole of the thyroid gland: an anatomical study. *Clin Anat* 2007; 20: 516-20.
 27. Aina EN, Hisham AN. External laryngeal nerve in thyroid surgery: is the nerve stimulator necessary? *Eur J Surg* 2001; 167: 662-5.
 28. Aina EN, Hisham AN. External laryngeal nerve in thyroid surgery: recognition and surgical implications. *ANZ J Surg* 2001; 71: 212-4.
 29. Seven H, Alkan Z, Cakir BO, Sam B, Uslu B, Turgut S. The topographical anatomy of the external branch of the superior laryngeal nerve and its importance in thyroid surgery: a cadaver study. *Kulak Burun Bogaz Ihtis Derg* 2003; 11: 161-5.

เส้นประสาทเอกซเทอร်นอลลาริงเจียล: ความสัมพันธ์ทางกายวิภาค กับกล้ามเนื้ออินฟีเรียคอนสตริกเตอร์, หลอดเลือดแดงสูฟีเรียไทรอยด์ และขั้วบนของต่อมไทรอยด์ในคนไทย

พงศ์พีระ เตธวัช, ยาดาฤดี วิรุฒิ, วาสนา ผลากรกุล, จันทิมา รุ่งเรืองชัย, ชญาณิชฐ์ มนูญผล

ภูมิหลัง: ศัลยแพทย์มักไม่ได้ค้นหาเส้นประสาทเอกซเทอร်นอลลาริงเจียลระหว่างการผ่าตัดต่อมไทรอยด์ ทั้ง ๆ ที่เป็นสาเหตุสำคัญของการเกิดเสียงแหบหลังการผ่าตัด สาเหตุหนึ่งคือ ความผันแปรของทางเดินเส้นประสาทนี้ ซึ่งแตกต่างกันได้มากในแต่ละการศึกษา นอกจากนี้การศึกษาเกี่ยวกับเส้นประสาทดังกล่าวในคนไทยยังมีค่อนข้างน้อย โดยเฉพาะอย่างยิ่งความสัมพันธ์ทางกายวิภาคกับกล้ามเนื้ออินฟีเรียคอนสตริกเตอร์ และขั้วบนของต่อมไทรอยด์ ซึ่งเป็นหลักเขตสำคัญในการค้นหาเส้นประสาทดังกล่าวในระหว่างการผ่าตัด

วัตถุประสงค์: อธิบายทางเดินของเส้นประสาทเอกซเทอร်นอลลาริงเจียล และความสัมพันธ์ทางกายวิภาค กับกล้ามเนื้ออินฟีเรียคอนสตริกเตอร์, หลอดเลือดแดงสูฟีเรียไทรอยด์ และขั้วบนของต่อมไทรอยด์ในคนไทย เพื่อเป็นแนวทางในการค้นหา และเก็บรักษาเส้นประสาทดังกล่าวในระหว่างการผ่าตัด

วัสดุและวิธีการ: ทำการศึกษาเส้นประสาทเอกซเทอร်นอลลาริงเจียลจำนวน 134 เส้น จากอาจารย์ใหญ่ 68 ร่าง ซึ่งมีขนาดของต่อมไทรอยด์ปกติ และไม่มีลักษณะที่ผิดปกติใด ๆ บริเวณคอ โดยการศึกษาแบ่งออกเป็น 3 ส่วน (1) ความสัมพันธ์ทางกายวิภาคของเส้นประสาทกับกล้ามเนื้ออินฟีเรียคอนสตริกเตอร์ (2) ระยะทางที่สั้นที่สุดจากเส้นประสาทถึงขั้วบนของต่อมไทรอยด์ (3) ระยะทางระหว่างจุดตัดของเส้นประสาท และหลอดเลือดแดงสูฟีเรียไทรอยด์กับขั้วบนของต่อมไทรอยด์โดยที่ระยะต่าง ๆ ถูกวัดในหน่วยมิลลิเมตร ด้วยเวอร์เนียร์คาลิเปอร์

ผลการศึกษา: รายงานผลการศึกษาทั้ง 3 ส่วน โดยใช้การแบ่งประเภทที่ได้รับการยอมรับอย่างแพร่หลาย และทำการเปรียบเทียบผลการศึกษากับงานวิจัยในต่างประเทศ พบว่าเส้นประสาทเอกซเทอร်นอลลาริงเจียลทุกเส้นวางอยู่บนกล้ามเนื้ออินฟีเรียคอนสตริกเตอร์ หรือ อย่างน้อยส่วนบนของกล้ามเนื้อดังกล่าวทำให้เส้นประสาทเส้นนี้มีโอกาสได้รับอันตรายมากขึ้นในคนไทย

สรุป: ทางเดินของเส้นประสาทเอกซเทอร်นอลลาริงเจียล และความสัมพันธ์ทางกายวิภาคกับอวัยวะข้างเคียง อาจมีความผันแปรได้มาก และมีหลายปัจจัยที่ส่งผลต่อลักษณะทางกายวิภาคดังกล่าว อย่างไรก็ตามการศึกษานี้ น่าจะช่วยให้ส่งเสริมให้ศัลยแพทย์ค้นหาเส้นประสาทเส้นนี้ด้วยความพิถีพิถัน เพื่อลดความเสี่ยงที่จะเกิดอันตรายต่อเส้นประสาทดังกล่าว