

The Role of Liquid Simethicone in Enhancing Endoscopic Visibility Prior to Esophagogastroduodenoscopy (EGD): A Prospective, Randomized, Double-Blinded, Placebo-Controlled Trial

Suriya Keeratichananont MD*,
Abhasnee Sobhonslidsuk MD*, Taya Kitiyakara MD*,
Narin Achalanan MD*, Supamai Soonthornpun MD**

* Division of Gastroenterology, Department of Medicine, Faculty of Medicine, Ramathibodi Hospital, Mahidol University, Bangkok, Thailand

** Division of Endocrinology and Metabolism, Department of Medicine, Faculty of Medicine, Songklanakarind Hospital, Prince of Songkla University, Songkhla, Thailand

Background: Simethicone improves endoscopic visibility and diagnostic accuracy during colonoscopy and capsule endoscopy. Nevertheless, there have been limited data on its usefulness in esophagogastroduodenoscopy (EGD).

Objective: To evaluate the effectiveness of simethicone on enhancing endoscopic visibility in patients undergoing EGD.

Material and Method: 121 patients were randomized to take 2 ml of either liquid simethicone or placebo in 60 ml of water at 15-30 minutes before EGD. The severity scores of foam and bubbles at the esophagus, stomach and duodenum were compared.

Results: Simethicone improved endoscopic visibility by diminishing mean cumulative (6.83 ± 2.4 vs. 11.05 ± 2.6, $p < 0.001$) and local scores of foam and bubbles at all areas, and decreased the number and timing of adjunctive simethicone washing (17.5% vs. 74.1%, $p < 0.001$ and 0 vs. 19 seconds, $p < 0.001$). Simethicone increased endoscopist and patient satisfaction significantly without having adverse effects.

Conclusion: Using simethicone before EGD enhances endoscopic visibility, reduces adjunctive simethicone washing and increases endoscopist and patient satisfaction.

Keywords: Endoscopic visibility, Esophagogastroduodenoscopy, Simethicone

J Med Assoc Thai 2010; 93 (8): 892-7

Full text. e-Journal: <http://www.mat.or.th/journal>

Esophagogastroduodenoscopy (EGD) has been a reliable investigation for upper gastrointestinal tract diseases. However, intraluminal foam and bubbles can impair endoscopic visibility, potentially missing important subtle lesions and extending the time of EGD. Simethicone is a defoaming agent which decreases surface tension, leading to coalescing of foam and bubbles⁽¹⁾. Simethicone, which is not absorbed from gastrointestinal tract and is not attached to other drugs, rarely has adverse effects. Previous

studies reported that the addition of simethicone with bowel preparation before performing colonoscopy and small bowel capsule endoscopy is useful by increasing endoscopic visibility, diagnostic accuracy and endoscopist satisfaction⁽²⁻⁷⁾. In 1954, simethicone was introduced for use before EGD by Gasster M, et al⁽⁸⁾. Subsequently, Mc Donald GB, et al reported that liquid simethicone could decrease obscuring foam and bubbles⁽⁹⁾. In 1992, a randomized double-blinded placebo-controlled trial revealed that liquid simethicone 65 or 195 mg in 90 ml of water taken prior to EGD enhanced endoscopic visibility by diminishing obscuring foam and bubbles in the stomach and duodenum, demonstrated by the reduction of cumulative scores of foam and bubbles. The investigators showed that simethicone reduced

Correspondence to:

Sobhonslidsuk A, Division of Gastroenterology, Department of Medicine, Faculty of Medicine, Ramathibodi Hospital, 270 Rama 6 Rd, Rajathevee, Bangkok 10400, Thailand.
Phone: 0-2201-1304, Fax: 0-2210-1304
E-mail: teasb@hotmail.com

the number of patients who needed adjunctive simethicone washing and decreased adjunctive washing time significantly⁽¹⁰⁾. A smaller dose of simethicone and lesser volume of water (50 mg of simethicone in 10-30 ml of water) was proved to be effective in diminishing bubbles⁽¹¹⁾. However, the usefulness of simethicone in EGD in other aspects has not been explored. Therefore, the present study was conducted to evaluate the effectiveness of liquid simethicone solution on enhancing endoscopic visibility, the requirement of adjunctive simethicone washing and satisfaction.

Material and Method

A prospective, randomized, double-blinded, placebo-controlled trial was carried out between August 1st, 2007 and October 31st, 2008. Inclusion criteria included adults aged 18-80 years old who underwent elective diagnostic EGD at the division of Gastroenterology, Ramathibodi Hospital. Exclusion criteria were having nasogastric tube insertion, stenosis of upper digestive tract, retention of food content in the stomach, history of gastric surgery, cardiac and coronary artery diseases within 6 weeks, uncontrolled pulmonary diseases, pregnancy, thrombocytopenia (platelet less than 20,000/mm³), coagulopathy (INR over 2.5)⁽¹³⁾ and history of simethicone use within 2 weeks. The present study was approved by the hospital ethics committee. All patients gave written informed consent before enrolment to the study. They were randomized (with blocks of forty) to take 60 ml of water with either 2 ml of liquid simethicone (133.3 mg) or placebo in opaque bottles at 15-30 minutes before EGD. The rationale of using 133.3 mg of simethicone derived from the authors' experience that 133.3 mg dose decreased foam and bubbles more than 66.6 mg dose without any difference from 200 mg dose. Also for dilution, 60 ml of water, similar to 90 ml, was able to decrease foam and bubbles more than 30 ml of water. EGD was performed by 8 endoscopists who were blinded to the treatment arm. The findings of EGD were recorded on CDs. Every video image was assessed by a single investigator who was blinded to the treatment arm. The severity of foam and bubbles was scored by the grading system of Mc Nally, et al⁽¹⁴⁾ as the following: grade 1 (no foam, bubbles), 2 (minimal, must actively look for them), 3 (moderate) or 4 (abundant, obscuring of mucosal surface, need adjunctive simethicone washing) at four areas of esophagus, stomach (: fundus and body, antrum and angulus) and duodenum. The cumulative scores of the maximum grading of foam and bubbles

at all areas and each area of the two groups were compared. Furthermore, the frequency of patients who needed adjunctive simethicone washing, the duration of washing, the total EGD examination time which included the withdrawal time of endoscopy and biopsy if performed endoscopist and patient satisfaction, and the adverse effects of study drugs were also recorded at the end of EGD.

The primary endpoint of the present study was to evaluate the effectiveness of liquid simethicone on enhancing endoscopic visibility. The secondary endpoints were to compare the differences between the two groups for the local score of foam and bubbles, the number of patients who needed adjunctive simethicone washing, the duration needed for adjunctive simethicone washing, total EGD examination time, endoscopist and patient satisfaction, and the adverse effects of medications.

Statistical analysis

The sample size calculation was estimated based on the results of the authors' preliminary study. The mean and standard deviation (SD) of cumulative score of foam and bubbles in simethicone and placebo groups were 8.00 (2.16) and 9.70 (2.98), respectively. Thereby, the calculated sample size of each group was 50 patients.

Mean (SD) or median (range) was used to describe continuous data. Proportion (%) was used to

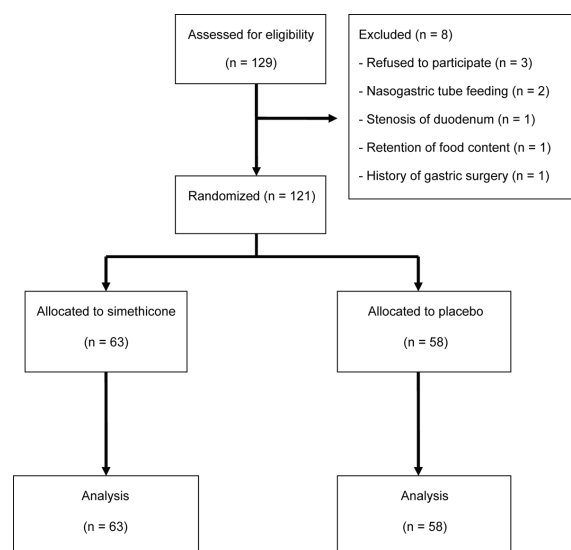


Fig. 1 Patient disposition

Table 1. Baseline characteristics of the study groups

Characteristics	Simethicone (n = 63)	Placebo (n = 58)
Mean age, yr (SD)	59.0 (12.7)	55.7 (13.6)
Gender, n (%)		
Male	31 (49.2)	24 (41.4)
Female	32 (50.8)	34 (58.6)
Indication for EGD, n (%)		
Dyspepsia	19 (30.2)	26 (44.8)
Heart burn or regurgitation	5 (7.9)	4 (6.9)
Variceal screening	12 (19)	14 (24.1)
Anemia	18 (28.6)	9 (15.5)
Weight loss	2 (3.2)	1 (1.7)
PEG*	2 (3.2)	2 (3.4)
Others**	5 (7.9)	2 (3.4)
Underlying diseases, n (%)		
Diabetes	5 (7.9)	6 (10.3)
Hypertension	7 (11.1)	5 (8.6)
Coronary artery disease	4 (6.3)	5 (8.6)
Liver cirrhosis	16 (25.4)	12 (20.7)
Head and neck cancer	2 (3.2)	2 (3.4)
Stroke	1 (1.6)	1 (1.7)
Multiple underlying diseases	2 (3.2)	2 (3.4)
Miscellaneous***	9 (14.2)	1 (1.7)
Current smoking, n (%)	3 (4.8)	11 (19)
Alcohol drinking [#] , n (%)	5 (7.9)	7 (12.1)
NSAIDS use [#] , n (%)	14 (22.2)	18 (31)

* Percutaneous endoscopic gastrostomy

** Simethicone (globus sensation 1, GI bleeding 4), placebo (1 GI bleeding, 1 vomiting)

*** Simethicone group (1 COPD, 1 scleroderma, 1 rheumatoid arthritis, 1 osteoarthritis, 1 hemangioma, 1 chronic HBV, 1 chronic HCV, 1 Parkinson's disease, 1 Von-Willebrand disease; placebo group (1 COPD)

[#] Within 3 months

describe categorical data. Independent t-test (or Mann-Whitney test) and Chi-square test (or Fisher's exact test) were used to analyze the continuous and categorical characteristics and the outcomes of interest, respectively. All analyses were performed with SPSS version 15 software. Results were considered as statistical significance if p-value was less than 0.05.

Results

A total of 129 patients were prospectively enrolled to the present study. Eight patients were excluded due to refusal to participate with the study (n = 3), retention of nasogastric tube (n = 2), duodenal stenosis (n = 1), history of previous gastric surgery (n = 1) and the retention of food content (n = 1). Finally,

Table 2. Endoscopic diagnosis and rapid urease test (RUT)

Endoscopic diagnosis and RUT	Simethicone (n = 63)	Placebo (n = 58)
Endoscopic diagnosis, n (%)		
Gastritis	16 (25.4)	19 (32.8)
Gastric ulcer	9 (14.3)	10 (17.2)
Duodenal ulcer	2 (3.2)	0
Esophageal varices	7 (11.1)	5 (8.6)
GERD*	3 (4.8)	3 (5.2)
PHG**	1 (1.6)	0
Others [#]	5 (7.9)	3 (5.2)
Multiple diseases ^{##}	10 (15.9)	12 (20.7)
Normal finding	10 (15.9)	6 (10.3)
Rapid urease test, n (%)		
Positive	18 (28.5)	14 (24.1)
Negative	30 (47.6)	24 (41.4)
Not done	15 (23.8)	20 (34.5)

* Gastroesophageal reflux disease

** Portal hypertensive gastropathy

[#] Simethicone (1 duodenal cancer, 1 gastric angiodysplasia, 2 gastric antral vascular ectasia, 1 fundic gland polyp), placebo (1 gastric polyp, 1 duodenitis, esophageal polyp)

^{##} At least two diseases of above were found in the same patients or one disease of above plus any of these e.g., esophagitis, esophageal ulcer, hiatal hernia, duodenal polyp

121 participants were randomized into two groups; 63 patients were allocated to receive liquid simethicone and 58 patients received placebo (Fig. 1). There were no significant differences between the two groups on baseline data (: age, sex, indications for EGD, underlying diseases, history of alcohol drinking and NSAIDS use) except for the history of current smoking that was more prevalent in the placebo group (19.0% vs. 4.8%, p = 0.02) (Table 1). The final endoscopic diagnosis and the result of rapid urease test are summarized in Table 2. The primary end point was the effectiveness of liquid simethicone on enhancing endoscopic visibility, which was evaluated by comparing the mean cumulative scores of foam and bubbles between the two groups. The results showed that liquid simethicone enhanced endoscopic visibility greater than placebo, which was demonstrated by the reduction of mean cumulative scores of foam and bubbles (6.83 ± 2.4 vs. 11.05 ± 2.6, p < 0.001). Furthermore, simethicone, compared to placebo, significantly improved endoscopic visibility at all areas, with the lower mean local scores of foam and bubbles at esophagus (1.62 ± 0.6 vs. 2.10 ± 0.7), fundus and body (2.43 ± 1.0 vs. 3.47 ± 0.8), antrum and

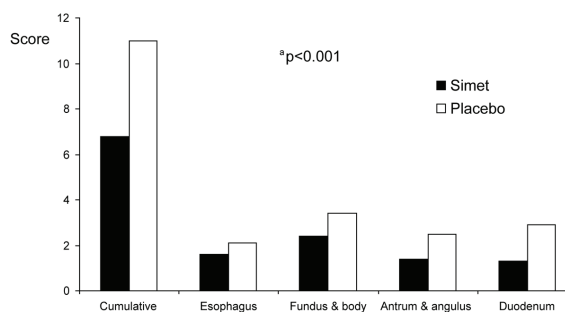
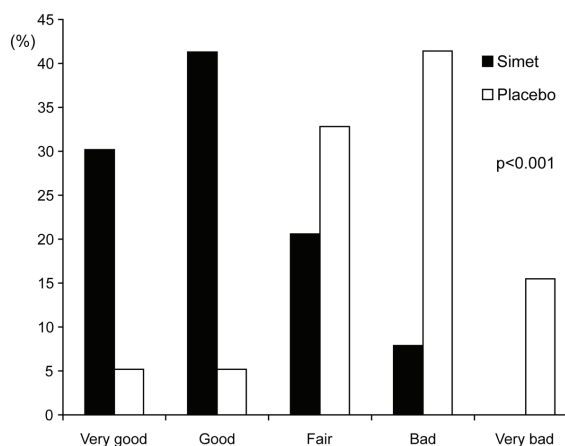
Table 3. Open-label adjunctive simethicone washing data

Open label adjunctive simethicone washing	Simethicone (n = 63)	Placebo (n = 58)	p-value
Patients required washing, n (%)	11 (17.5)	43 (74.1)	<0.001
Timing of washing, seconds			<0.001
Mean (SD)	0 (17)	19 (44)	
Min-Max	0-70	0-240	
EGD examination time, minutes			NS
Mean (SD)	9.9 (4.9)	9.8 (4.0)	
Min-Max	4-30	3-21	

Table 4. Adverse effects of study drugs

	Simethicone (n = 63)	Placebo (n = 58)	p-value
Adverse effects, n (%)	7 (11.1)	14 (24.1)	NS
Nausea	3 (4.8)	5 (8.6)	
Vomiting	2 (3.2)	4 (6.9)	
Abdominal pain	2 (3.2)	7 (12.1)	
Flatulence	2 (3.2)	6 (10.3)	

angulus (1.44 ± 0.8 vs. 2.53 ± 1.1), duodenum (1.35 ± 0.7 vs. 2.95 ± 0.9) (Fig. 2). Moreover, the number of adjunctive simethicone washing for residual obscuring foam was lower in the simethicone group (17.5% vs. 74.1%, $p < 0.001$). The median adjunctive simethicone washing time was shorter in the simethicone group (0 vs. 19 seconds, $p < 0.001$). However, there was no significant difference for the mean total EGD time between two groups (9.9 ± 4.9 vs. 9.8 ± 4.0 minutes, $p = 0.895$) (Table 3). Endoscopist satisfaction was graded by using endoscopic visibility scale as very good, good, fair, bad, very bad. Patient satisfaction was self-rated by visual analogue scale (VAS). The severity of abdominal pain, abdominal discomfort flatulence, nausea and vomiting within 30 minutes after EGD was self-rated by using visual analogue scale (VAS) with the score from 0 to 10. The results revealed that simethicone enhanced endoscopist satisfaction significantly by showing higher proportion of very good and good endoscopic visibility scale in this group compared to placebo (70.0% vs. 15.4%, $p < 0.001$) (Fig. 3). From self-rating assessment by VAS, patient satisfaction was higher in the simethicone group than in the placebo group (0.38 ± 1.02 vs. 1.12 ± 2.17 , $p = 0.017$). In addition, the adverse effects occurred in both groups without significant difference (Table 4).

**Fig. 2** Mean local and cumulative scores of foam and bubbles**Fig. 3** Endoscopist satisfaction by endoscopic visibility scale

Discussion

EGD is the procedure of choice for making diagnosis of upper GI tract diseases. However, the diagnostic yield may be reduced when visibility of the mucosal surface is impaired. The intraluminal foam and bubbles, which originates from air swallowed during

EGD, admixed with gastric and bile contents are the main cause of impaired visibility. Enhanced visibility could be obtained by different methods, such as prolonged fasting, pre-endoscopic prokinetic drugs use (: intravenous erythromycin)⁽¹⁵⁾, pre-endoscopic and/or intra-procedural simethicone washing. In 1950, liquid simethicone was used as a defoaming agent before semi-rigid gastroscopy in the uncontrolled trials^(8,16-18). Subsequently, there were two small, double-blind randomized studies that confirmed the usefulness of simethicone in decreasing intraluminal foam and bubbles^(9,19). However, in these studies, the parameter that was assessed was the cumulative data of the entire UGI tract^(9,19). Since then, the effectiveness of numerous formula of liquid simethicone solution in enhancing endoscopic visibility and decreasing the frequency and time for adjunctive simethicone washing has been reported. However, only a small number of well-conducted studies have reported the benefit of pre-procedural liquid simethicone.

The present study showed that liquid simethicone solution was more effective than placebo in reducing obscuring foam and bubbles at all areas of upper gastrointestinal tract, enhancing endoscopic visibility (by diminishing mean cumulative score of foam and bubbles, 6.83 ± 2.4 vs. 11.05 ± 2.6 , $p < 0.001$), reducing the number (17.5% vs. 74.1%, $p < 0.001$) and timing of adjunctive simethicone washing. Furthermore, the improvement of endoscopist satisfaction (with a higher proportion of very good and good endoscopic visibility grades, 90.0% vs. 15.4%, $p < 0.001$) and patient satisfaction was found. Importantly, adverse effects were not increased in simethicone group. However, the mean total EGD time was not shortened in the simethicone group as initially expected, which may be explained from numerous confounding factors such as the inclusion of time for mucosal biopsy in the total EGD time. When compared with previous studies, the present study has many advantages including calculation of the required sample size; evaluation of endoscopist and patient satisfaction, and analysis of adverse effects of medications. The authors decided to use the smallest required dosage of simethicone and the lowest volume of solution for safety concerns and cost saving. Despite these advantages, the present study was limited and was not designed to answer the questions of optimum dose and volume of the simethicone solution.

In conclusion, using liquid simethicone before EGD enhances endoscopic visibility reduces number and timing of adjunctive simethicone washing,

increases endoscopist and patient satisfaction during EGD without any significant adverse effects. Taking liquid simethicone before EGD may be more convenient than using simethicone washing during the examination. However, further studies are warranted to answer whether or not improving endoscopic visibility will lead to increased detection of small but important lesions of the upper digestive tract.

Acknowledgments

The authors would like to thank the staff of division of Gastroenterology for helping in the entire study, Dr. Sasinee Tongprasert for her comments and R.X. Company, Limited, Bangkok, Thailand for providing the study drug and placebo upon request.

Conflict of interest: none

Declaration of funding: The study was funded by The Gastroenterological Association of Thailand.

References

1. Parikh VA, Khanduja KS. Use of simethicone during colonoscopy. *Dis Colon Rectum* 1995; 38: 1007-8.
2. McNally PR, Maydonovitch CL, Wong RK. The effect of simethicone on colonic visibility after night-prior colonic lavage. A double-blind randomized study. *J Clin Gastroenterol* 1989; 11: 650-2.
3. Sudduth RH, DeAngelis S, Sherman KE, McNally PR. The effectiveness of simethicone in improving visibility during colonoscopy when given with a sodium phosphate solution: a double-blind randomized study. *Gastrointest Endosc* 1995; 42: 413-5.
4. Albert J, Gobel CM, Lesske J, Lotterer E, Nietsch H, Fleig WE. Simethicone for small bowel preparation for capsule endoscopy: a systematic, single-blinded, controlled study. *Gastrointest Endosc* 2004; 59: 487-91.
5. Wei W, Ge ZZ, Lu H, Gao YJ, Hu YB, Xiao SD. Purgative bowel cleansing combined with simethicone improves capsule endoscopy imaging. *Am J Gastroenterol* 2008; 103: 77-82.
6. Tongprasert S, Sobhonslidsuk A, Rattanasiri S. Improving quality of colonoscopy by adding simethicone to sodium phosphate bowel preparation. *World J Gastroenterol* 2009; 15: 3032-7.
7. Poddubny B, Kashin SV, Shubin L, Goncharov V, Mazurov S, Agamov A. Comparison of the efficacy, tolerability and safety of PEG solution (Fortrans^R) with simethicone vs. conventional method of preparation before colonoscopy: a

- multicentre study. *Gastrointest Endosc* 2008; 67: AB324.
8. Gasster M, Weswater JO, Molle WE. Use of a defoaming agent in gastroscopy. *Gastroenterology* 1954; 27: 652-5.
 9. McDonald GB, O'Leary R, Stratton C. Pre-endoscopic use of oral simethicone. *Gastrointest Endosc* 1978; 24: 283.
 10. Bertoni G, Gumina C, Conigliaro R, Ricci E, Staffetti J, Mortilla MG, et al. Randomized placebo-controlled trial of oral liquid simethicone prior to upper gastrointestinal endoscopy. *Endoscopy* 1992; 24: 268-70.
 11. Chen WN, Chen GH, Poon KK. Effectiveness of simethicone solution in upper gastrointestinal endoscopy: a double-blind randomized study. *Chinese J Gastroenterol* 1995; 11: 1-6.
 12. Ng FH, Wong SY, Kng C, Chow SL, Lai KC, Ng WF. Effect of simethicone on the accuracy of the rapid urease test. *Eur J Gastroenterol Hepatol* 1998; 10: 851-4.
 13. Eisen GM, Baron TH, Dominitz JA, Faigel DO, Goldstein JL, Johanson JF, et al. Complications of upper GI endoscopy. *Gastrointest Endosc* 2002; 55: 784-93.
 14. McNally PR, Maydonovitch CL, Wong RK. The effectiveness of simethicone in improving visibility during colonoscopy: a double-blind randomized study. *Gastrointest Endosc* 1988; 34: 255-8.
 15. Coffin B, Pocard M, Panis Y, Riche F, Laine MJ, Bitoun A, et al. Erythromycin improves the quality of EGD in patients with acute upper GI bleeding: a randomized controlled study. *Gastrointest Endosc* 2002; 56: 174-9.
 16. Hirschwitz BI, Bolt RJ, Pollard HM. Defoaming in gastroscopy with silicone. *Gastroenterology* 1954; 27: 649-51.
 17. Dailey ME, Rider JA. Silicone antifoam tablet in gastroscopy. *JAMA* 1954; 155: 859.
 18. Garry MW. Use of silicone antifoam in gastroscopy. *Am J Gastroenterol* 1956; 26: 733-4.
 19. Waye JD, Pitman E, Weiss A, Krueger K. The bubble problem in endoscopy. An evaluation of a new aid in endoscopy. A double blind study. *Gastrointest Endosc* 1967; 14: 34-5.

บทบาทของยาไซเมติโคนชนิดน้ำที่ให้ก่อนส่องกล้องกระเพาะอาหารและลำไส้เล็กในการเพิ่มความชัดเจนของการส่องกล้อง: การศึกษาไปข้างหน้าแบบสุ่มและปกปิดโดยมีตัวควบคุม

สุรียา กิรติชนานนท์, อาภัสณี ไสภณสฤษฏ์สุข, นรินทร์ อจละนันท์, ทยา กิตติยากร, ศุภมัย สุนทรพันธ์

ภูมิหลัง: ยาไซเมติโคนช่วยให้การส่องกล้องทางเดินอาหารมีความชัดเจน และวินิจฉัยถูกต้องในระหว่างส่องกล้องลำไส้ใหญ่ และการตรวจแคปซูลในลำไส้ แต่ยังคงขาดข้อมูลนี้ในการส่องกล้องกระเพาะอาหารและลำไส้เล็กส่วนต้น

วัตถุประสงค์: เพื่อประเมินประสิทธิภาพของยาไซเมติโคนในการเพิ่มความชัดเจนของการส่องกล้องในผู้ป่วยที่มารับการตรวจส่องกล้องกระเพาะอาหารและลำไส้เล็กส่วนต้น

วัสดุและวิธีการ: ผู้ป่วยจำนวน 121 รายถูกสุ่มให้รับประทานยาไซเมติโคนชนิดน้ำ 2 มิลลิลิตร หรือยาหลอกผสมในน้ำ 60 มิลลิลิตร 15-30 นาทีก่อนส่องกล้องกระเพาะอาหารและลำไส้เล็กส่วนต้น ปริมาณของฟองขนาดใหญ่และฟองขนาดเล็ก ที่หลุดออกอาหาร กระเพาะอาหาร และลำไส้เล็กส่วนต้นได้รับการเปรียบเทียบ

ผลการศึกษา: ยาไซเมติโคนเพิ่มความชัดเจนของการส่องกล้องกระเพาะอาหารและลำไส้เล็กส่วนต้น โดยพบว่ามีการลดลงของคะแนนเฉลี่ยรวมของฟองขนาดใหญ่และฟองขนาดเล็ก (6.83 ± 2.4 vs. 11.05 ± 2.6 , $p < 0.001$) คะแนนของฟองขนาดใหญ่และฟองขนาดเล็กทุกตำแหน่ง รวมถึงจำนวนครั้ง และระยะเวลาของการล้างเพิ่มด้วยยาไซเมติโคน (17.5% vs. 74.1%, $p < 0.001$ และ 0 vs. 19 วินาที, $p < 0.001$) ยาไซเมติโคนเพิ่มความพึงพอใจของผู้ส่องกล้อง และผู้ป่วยอย่างมีนัยสำคัญทางสถิติ โดยไม่มีภาวะแทรกซ้อน

สรุป: การใช้ยาไซเมติโคนก่อนส่องกล้องกระเพาะอาหารและลำไส้เล็กช่วยเพิ่มความชัดเจนของการส่องกล้องลดการล้างเพิ่มด้วยยาไซเมติโคนและเพิ่มความพึงพอใจของผู้ส่องกล้องและผู้ป่วย