

Case Report

Identification of Sandhoff Disease in a Thai Family: Clinical and Biochemical Characterization

Kullasate Sakpichaisakul MD*, Pairat Taeranawich MD*,
Achara Nitiapinyasakul MD**, Todsaporn Sirisopikun MD*

* Department of Pediatrics, Maharat Nakhon Ratchasima Hospital, Nakhon Ratchasima, Thailand

** Department of Ophthalmology, Maharat Nakhon Ratchasima Hospital, Nakhon Ratchasima, Thailand

Sandhoff disease is a GM2 gangliosidosis that is rare in Thailand. The authors report a Thai family with two children known to have infantile form of Sandhoff disease. The index case exhibited mitral valve prolapse with mitral regurgitation as an early sign, which is a rare presentation in Sandhoff disease. Thereafter, the patient had developmental regression, startle reaction, and cherry red spots. The diagnosis was confirmed by biochemical analysis.

Keywords: Infantile sandhoff disease, Cherry red spot, Mitral valve prolapse

J Med Assoc Thai 2010; 93 (9): 1088-92

Full text. e-Journal: <http://www.mat.or.th/journal>

Gangliosides are components of plasma membranes, which comprise sphingosine, fatty acids, hexose, hexosamine, and neuraminic acid. Gangliosides degraded in cellular lysosomal compartment⁽¹⁾. Normally, the hydrolysis of gangliosides is accomplished by the action of two structurally related lysosomal enzymes, hexosaminidase A (Hex A) and hexosaminidase B (Hex B), and the GM2 activator protein⁽²⁾. Hex A is composed of two subunits, α and β ($\alpha\beta$), whereas Hex B has only β subunits ($\beta\beta$). In the degradation of GM2 gangliosides mediated by Hex A, GM2 activator protein is crucial for the phenomenon. The subunits of hexosaminidase, α and β are encoded by two main genes, *HEXA* (15q23-q24) and *HEXB* (5q13) respectively⁽²⁻⁴⁾. Particularly, mutation of any one of these genes can result in autosomal recessive GM2 gangliosidosis which then results in intralysosomal accumulation of GM2 gangliosides and a few related glycolipids in neurons of the brain, and to a much lesser extent in other organs⁽²⁾. Theoretically, there are three diseases sharing similar clinical phenotypes, *i.e.*, Tay-Sachs (α -defects), Sandhoff (β -defects), the

AB-variant (activator defects), most of them cannot be distinguished by clinical manifestations⁽³⁾.

Sandhoff disease has three subtypes, which are infantile, juvenile, and adult onset^(4,5). The infantile form is characterized by early onset of symptoms, which usually occur in the first 6 to 18 months of life. An abnormal acousticomotor reaction, psychomotor deterioration, together with axial hypotonia and bilateral pyramidal signs, and cortical blindness with macular cherry red spots are clinical hallmarks of this disease. This form usually presents as a stereotypical progression of disease, leading to death before the age of 4^(4,5).

In the juvenile form with mid-childhood onset, initial manifestations include clumsiness due to ataxia, subsequent spasticity, athetosis, loss of languages and seizures⁽⁶⁾. The adult patients with Sandhoff disease present later in adulthood and the disease progresses more slowly. The juvenile and adult forms differ from each other primarily by the impact of disease on intelligence, which is minimal through much of the course of adulthood^(4,6). The cherry red spot in the macula is less frequently detected in this form.

In the present report, the authors present a Thai family with two children affected by Sandhoff disease and a healthy carrier child. Relevant physical findings and biochemical analysis of hexosaminidase assay are described.

Correspondence to:

Sakpichaisakul K, Department of Pediatrics, Maharat Nakhon Ratchasima Hospital, Chang Phuak Road, Muang, Nakhon Ratchasima 30000, Thailand.

Phone: 044-246-389, Fax: 044-235-166

E-mail: kullasait@hotmail.com

Case Report

A 1-year-5-month Thai boy, previously diagnosed with cerebral palsy, was hospitalized due to uncontrolled generalized tonic clonic and myoclonic seizures aggravated by loud noises. He was born full-term by vaginal delivery with normal birth weight. At 9 months of age, he was incidentally found to have asymptomatic heart murmur from which echocardiogram revealed mitral valve prolapse with moderate mitral regurgitation of unclear etiology. Coincidentally, at that time, his mother also mentioned a developmental regression of her child as being unable to sit without support. Thereafter, the generalized tonic clonic and myoclonic seizures following the exposure to loud noise began to develop most notably from 15 months of age. Neurologic examination revealed generalized hypotonia with hyperreflexia, while other physical findings appeared to be normal. Brain ultrasound at 10 months showed no significant abnormalities. Brain CT/MRI was not performed.

The patient was the third child of a healthy, non-consanguineous couple who came from the same district in Northeastern Thailand. As for the other two sons, the oldest died at 3 years of age and was described to have similar progressive neurological disorder as the patient, while the second child, now 6 years old, has normal development.

Physical examination at 1 year and 5 months of age showed that he could not follow objects and had neither visual attention nor eye contact. Ophthalmological examination revealed inability to fixate his eyes on objects and not follow moving targets. Pale optic discs and cherry red spots in the macula were detected (Fig. 1).

As a result, Tay-Sachs disease was suspected and peripheral blood samples were taken from the patient and his living brother for biochemical analysis at Genetic Laboratory, Department of Pediatrics, Faculty of Medicine, Ramathibodi Hospital, Mahidol University. Plasma hexosaminidase A and B activity

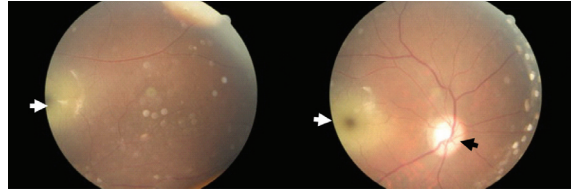


Fig. 1 Ocular fundus photographs. Left eye shows a cherry red spot in the macula (white arrow). Right eye shows a cherry red spot in the macula (white arrow) and a pale optic disc (black arrow)

was assayed by using spectrophotometric method and 4-methylumbelliferyl-2-acetamido-2-deoxy- β -D-glucopyranoside as tested substrate. The analysis showed a marked reduction of both total Hex A and B (5-6% of normal control), and Hex B (9% of normal control) activities in the patient's specimen, whereas Hex A activity was normal (70% of normal control). These results were consistent with Sandhoff disease (Table 1). In his brother's specimen, the result showed moderately reduced activities of total Hex A and B, and Hex B, suggesting carrier status of the disease. Genetic counseling was provided to the parents. Due to the lack of effective treatment for Sandhoff disease, the patient's condition deteriorated and eventually died of respiratory complication at 2 years of age.

Discussion

In the present report, a Thai boy who suffered from the infantile form of Sandhoff disease is described. The important clues pointing to the diagnosis in the present case are degenerative brain disorder, startle reaction, and macula cherry red spots. With all clinical evidences, GM2 gangliosidosis, *i.e.* Sandhoff and Tay-Sachs disease was suspected. Nevertheless, these two disorders cannot be distinguished by clinical phenotypes alone since both share almost identical clinical pictures. Only a few evidences are helpful in clinical diagnosis; organomegaly and occasional bone

Table 1. Enzyme activities of total hexosaminidase A and B, hexosaminidase A and hexosaminidase B

Individual	Total Hex A and B activity (nmol/ml/hr)	Hex B activity (nmol/ml/hr)	Hex A activity (% total activity)
Normal control	1,038.72	343.74	57.92
Normal control	1,190.64	327.84	71.90
Living brother	735.36	118.02	51.45
Patient	57.96	31.92	44.93

deformity can be found in some Sandhoff-affected individuals, but not in Tay-Sachs disease^(3,4,7). The present patient did not have organomegaly or bone involvement but showed cardiac abnormality. It follows therefore that the laboratory analysis of Hex profiles are necessary for definite diagnosis⁽⁷⁾.

A lysosomal enzyme assay from peripheral blood of the presented patient showed a marked reduction of both total Hex A and B isoenzymes in the serum, being a hallmark for Sandhoff disease⁽⁸⁾. The relatively higher percentage of Hex A activity compared to that of Hex B activity in Sandhoff disease can be explained by the excess α subunits due to the fact that fewer β subunits are produced^(3,5). The patient's brother had moderate reduction of total Hex A and B, and Hex B isoenzymes, which characterized him as a carrier of Sandhoff disease^(5,7-9). Unfortunately, parental specimens were not available for biochemical analysis.

In general, Tay-Sachs disease is rare, but with a higher prevalence than Sandhoff disease. The prevalence of Tay-Sachs disease is estimated 1 in 201,000 live births, while Sandhoff disease is described at 1 in 384,000 live births⁽⁴⁾. Tay-Sachs disease is more prevalent in Jewish populations with an incidence of 1 in 3,900 live births, whereas the incidence of Sandhoff disease is 1 in 1,000,000^(1,7). The Tay-Sachs carrier frequency is much higher in the Ashkenazi Jews (1 in 30) and eastern Quebec French Canadian (1 in 14) populations compared to that in the general population (1 in 300)^(1,4,7). The Sandhoff carrier frequency in non-Jewish populations (36 in 10,000) is slightly higher than Jewish populations (20 in 10,000)⁽¹⁰⁾. In Thailand, only one single case of Sandhoff disease (infantile form) was previously reported⁽¹¹⁾. The case was confirmed by enzyme analysis in skin fibroblast culture⁽¹¹⁾.

Macular cherry-red spot is an ophthalmic sign of lysosomal storage disease and can be used as a diagnostic clue even though it is not pathognomonic⁽¹²⁾. This fundus appearance also accompanies other neuronal lipid-storage disorders including Sandhoff disease (GM2 type II), gangliosidosis GM2 type III and GM1 type I, Niemann-Pick disease, sialidosis types I and II, Farber disease, mucopolipidosis III, and metachromatic leukodystrophy^(13,14). The cherry red spot in the macula is due to the accumulation of sphingolipid in retinal ganglion cells. As the disease progresses, optic atrophy can be present⁽¹³⁾.

Mitral valve prolapse (MVP) has been described a common disorder, with prevalence

estimates generally ranging from 5 to 15 percent in previously reports⁽¹⁵⁾. The larger study of the prevalence of MVP in the general population from the Framingham investigators, they reported overall prevalence of 2.4% the same as the Theal et al study reporting a prevalence of MVP was 2.7%^(15,16). The prevalence did not differ significantly between ethnic groups. To date, the largest study of the echocardiographic prevalence of MVP was 0.6%, which was substantially lower than that previously reported. The knowledge pertaining to MVP is mainly based on that studied in adults. However, MVP is not an uncommon finding in children younger than 13 years of age. Most of the children with MVP are asymptomatic⁽¹⁷⁾. MVP has been documented to be more prevalent in patients with Marfan syndrome, Ehlers-Danlos syndrome, osteogenesis imperfecta and other collagen related disorders⁽¹⁸⁾. The patient described had MVP with moderate mitral regurgitation, which in fact, could represent an extremely rare manifestation of Sandhoff disease. Similar cardiac findings have been previously reported in a single patient with infantile Sandhoff disease⁽¹⁹⁾. To the authors knowledge, there is no correlation of MVP and hexosaminidase, thus MVP may be an incidental finding.

Neuroimaging of GM2 gangliosidosis have already been published in a few reports⁽²⁰⁾. The abnormal lesions on bilateral thalamic and basal ganglia region on CT/MRI were associated with GM2 gangliosidosis, which could be a clue for specific diagnosis⁽²⁰⁾. In the presented patient, CT/MRI scans were not performed because the diagnosis was confirmed by plasma enzyme assay.

Treatment for Sandhoff disease generally involves symptomatic and supportive care, *i.e.* management of the seizures and interventional programs for motor and mental retardation. Genetic counseling and prenatal diagnosis for future pregnancy should be offered to the affected families.

In conclusion, the authors described a patient with classic infantile form of Sandhoff disease who had a rare cardiac manifestation as an early sign. Although uncommon association, this is an important sign to recognize. Further studies are needed to determine the correlation between hexosaminidase and MVP.

Acknowledgements

The authors thank for Dr. Daungrudee Wattanasirichaigoon for help with the biochemical

analysis, critical advice and editing the manuscript, and to Dr. Objoon Trachoo and Dr. Mahippathorn Chinnapa for revision of the manuscript and English editing.

References

1. Menkes JH, Wilcox WR. Inherited metabolic diseases of the nervous system. In: Menkes JH, Sarnat HB, Maria BL, editors. *Child neurology*. 7th ed. Philadelphia: Lippincott Williams & Wilkins; 2006: 82-6.
2. Lyon G, Kolodny EH, Pastores GM. Early infantile progressive genetic encephalopathies: clinical problems and diagnostic considerations. In: Lyon G, Kolodny EH, Pastores GM, editors. *Neurology of hereditary metabolic diseases of children*. 3rd ed. New York: McGraw-Hill; 2006: 78-85.
3. Mahuran DJ. Biochemical consequences of mutations causing the GM2 gangliosidosis. *Biochim Biophys Acta* 1999; 1455: 105-38.
4. Maegawa GH, Stockley T, Tropak M, Banwell B, Blaser S, Kok F, et al. The natural history of juvenile or subacute GM2 gangliosidosis: 21 new cases and literature review of 134 previously reported. *Pediatrics* 2006; 118: e1550-62.
5. Yun YM, Lee SN. A case report of Sandhoff disease. *Korean J Ophthalmol* 2005; 19: 68-72.
6. Hendriksz CJ, Corry PC, Wraith JE, Besley GT, Cooper A, Ferrie CD. Juvenile Sandhoff disease—nine new cases and a review of the literature. *J Inher Metab Dis* 2004; 27: 241-9.
7. Ozkara HA, Topcu M, Renda Y. Sandhoff disease in the Turkish population. *Brain Dev* 1997; 19: 469-72.
8. Wendeler M, Sandhoff K. Hexosaminidase assays. *Glycoconj J* 2009; 26: 945-52.
9. Lowden JA, Ives EJ, Keene DL, Burton AL, Skomorowski MA, Howard F. Carrier detection in Sandhoff disease. *Am J Hum Genet* 1978; 30: 38-45.
10. Cantor RM, Roy C, Lim JS, Kaback MM. Sandhoff disease heterozygote detection: a component of population screening for Tay-Sachs disease carriers. II. Sandhoff disease gene frequencies in American Jewish and non-Jewish populations. *Am J Hum Genet* 1987; 41: 16-26.
11. Wasant P, Wattanaweeradej S, Raksadawan N, Kolodny EH. Lysosomal storage disorders in Thailand: the Siriraj experience. *Southeast Asian J Trop Med Public Health* 1995; 26(Suppl 1): 54-8.
12. Sango K, Yamanaka S, Ajiki K, Arai N, Takano M. Involvement of retinal neurons and pigment epithelial cells in a murine model of sandhoff disease. *Ophthalmic Res* 2008; 40: 241-8.
13. Fenichel GM. Psychomotor retardation and regression. In: Fenichel GM, editor. *Clinical pediatric neurology: a signs and symptoms approach*. 5th ed. Philadelphia: Elsevier; 2005: 117-47.
14. Ospina LH, Lyons CJ, McCormick AQ. “Cherry-red spot” or “perifoveal white patch”? *Can J Ophthalmol* 2005; 40: 609-10.
15. Freed LA, Levy D, Levine RA, Larson MG, Evans JC, Fuller DL, et al. Prevalence and clinical outcome of mitral-valve prolapse. *N Engl J Med* 1999; 341: 1-7.
16. Theal M, Sleik K, Anand S, Yi Q, Yusuf S, Lonn E. Prevalence of mitral valve prolapse in ethnic groups. *Can J Cardiol* 2004; 20: 511-5.
17. Van Der Ham DP, De Vries JK, Van Der Merwe PL. Mitral valve prolapse: a study of 45 children. *Cardiovasc J S Afr* 2003; 14: 191-4.
18. Grau JB, Pirelli L, Yu PJ, Galloway AC, Ostrer H. The genetics of mitral valve prolapse. *Clin Genet* 2007; 72: 288-95.
19. Venugopalan P, Joshi SN. Cardiac involvement in infantile Sandhoff disease. *J Paediatr Child Health* 2002; 38: 98-100.
20. Yuksel A, Yalcinkaya C, Islak C, Gunduz E, Seven M. Neuroimaging findings of four patients with Sandhoff disease. *Pediatr Neurol* 1999; 21: 562-5.

Sandhoff disease รายงานผู้ป่วยในครอบครัวไทย: อาการแสดงทางคลินิก และผลปฏิบัติการทางชีวเคมี

กุลเสฏฐ์ ศักดิ์พิชัยสกุล, ไพรัตน์ เตรนาวินท์, อัจฉรา นิธิอภิญาสกุล, ทศพร ศิริโสภิตกุล

Sandhoff disease เป็นโรคในกลุ่ม GM2 gangliosidosis ซึ่งพบน้อยมากในประเทศไทย ผู้นิพนธ์ รายงานผู้ป่วย 2 รายเป็นพี่น้องกันเป็นโรค *Sandhoff disease* ที่มีอาการแรกเริ่ม ในช่วงทารก ผู้ป่วย 1 ราย มาพบแพทย์ด้วยอาการทางหัวใจ ได้แก่ mitral valve prolapse และ mitral regurgitation โดยเป็นอาการนำที่พบน้อยมากใน *Sandhoff disease* หลังจากนั้นผู้ป่วยเริ่มมีพัฒนาการถดถอย ร่วมกับ startle reaction และ ตรวจพบ cherry red spots การวินิจฉัยผู้ป่วยรายนี้ยืนยันโดยผลปฏิบัติการทางชีวเคมี
