

Supernumerary Subclavius Muscle in Thais: Predisposing Cause of Thoracic Outlet Syndrome

Sitha Piyawinijwong PhD*,
Nopparatn Sirisathira PhD*

* Department of Anatomy, Faculty of Medicine, Siriraj Hospital, Mahidol University, Bangkok, Thailand

Objective: To demonstrate and classify the variation of the subclavius muscle according to its insertion in the Thais.

Material and Method: One hundred and twenty eight upper limbs were dissected out to expose the scapular region. The attachments of subclavius muscles were examined and recorded.

Results: The subclavius muscle was categorized into 4 types according to its insertion. There are 64.06% of type I, 17.96% of type II, 15.62% of type III and 2.34% of type IV. The insertion of subclavius muscle is gradually extended from the shallow groove on the inferior surface of the clavicle towards the conoid ligament and corocoid process, to the superior transverse scapular ligament and to the superior border of the scapula adjacent to the insertion of inferior belly of omohyoid muscle.

Conclusion: The present study prevailed 64% normal subclavius muscle and other 36% of varied supernumerary subclavius muscle. The presence of supernumerary subclavius muscle could be a predisposing causative factor of thoracic outlet syndrome.

Keywords: Subclavius muscle, Subclavius posticus, Supernumerary, Thoracic outlet syndrome

J Med Assoc Thai 2010; 93 (9): 1065-9

Full text. e-Journal: <http://www.mat.or.th/journal>

General anatomy textbooks pay curiously scant attention to a small subclavius muscle, this muscle is a relatively minor muscle which lies inferiorly to the clavicle, superficial to the costoclavicular ligament and deep to pectoralis major muscle. Its tendon originates from the junction of the first rib with its costal cartilage. The fleshy fibers passes oblique laterally and superior to insert into the shallow groove on inferior surface of the clavicle⁽¹⁾. Its posterior surface is separated from the first rib by the subclavian vessels and brachial plexus, its anterior surface from the pectoralis major muscle by the clavicular fascia. Variation of this muscle has been mentioned in a few anatomy books as it inserts to the coracoid process or to the upper border of the scapula⁽²⁾, even though the absence of the subclavius muscle was also reported⁽³⁾. The precise action of subclavius muscle is not totally clear. Gray's⁽¹⁾ describes it as probably pulling the point of the shoulder downwards and forwards and

steadying the clavicle, during movements of the shoulder, by bracing it against the articular disc of the sternoclavicular joint. Since the costoclavicular space where the muscle resided is rather narrow, the predisposing compression of passing through subclavian vessels and nerves was documented⁽⁴⁾. Recently, imaging studies of the subclavius muscle and related structures in the costoclavicular space were increasingly reported⁽⁵⁻⁹⁾ due to the rising incidence of thoracic outlet syndrome⁽¹⁰⁻¹²⁾. There are numerous factors inducing the thoracic outlet syndrome, one of those is the hypertrophy of subclavius muscle or reducing the costoclavicular space. Meanwhile the study of subclavius muscle has been reported as an anatomical variation and defined as a subclavius posticus muscle⁽¹³⁻¹⁹⁾ which is rarely found in the routine academic dissection. The present study was aimed to scrutinize this muscle particularly its attachments and further classify the subclavius muscle according to its distal attachment.

Correspondence to:

Piyawinijwong S, Department of Anatomy, Faculty of Medicine, Siriraj Hospital, Mahidol University, 2 Prannok road, Bangkoknoi, Bangkok 10700, Thailand.
Phone: 0-2419-8596, Fax: 0-2419-8523
E-mail: sispw@mahidol.ac.th

Material and Method

Sixty four cadavers bequeathed to the Department of Anatomy, Faculty of Medicine Siriraj Hospital with average age at the time of death was

Table 1. Classification of the subclavius muscle according to its insertion

Type	Site of insertion
I	Shallow groove on inferior surface of clavicle
II	Conoid ligament and root of coracoid process
III	Conoid ligament, coracoid process and the superior transverse ligament
IV	Conoid ligament and coracoid process, superior transverse ligament and the superior border of the scapula overlapping to the insertion of the inferior belly of omohyoid muscle

Table 2. Number and percentage of various type of the subclavius muscles (n = 128)

Subclavius muscle	Number	Percentage
Type I	82	64.06%
Type II	23	17.97%
Type III	20	15.62%
Type IV	3	2.34%

71 (range 39-96) years were used. There were 32 males and 32 females. One hundred and twenty eight upper limbs were dissected to expose the scapular region. In routine dissection course of the 2nd year medical students the upper limb had to be removed from the trunk, the tendinous origin was examined and recorded before the removal. The detailed dissection of the subclavius muscle was later done towards its insertion. Pattern of the muscular insertion was examined, recorded and photographed.

Results

Every subclavius muscle took its origin from the junction between the first rib and its costal cartilage as a tendinous structure. The size and insertion of this muscle were varied. The fleshy fiber extended inferolaterally beneath the clavicle, situated on the inferior surface of clavicle. Mostly, it inserted into the shallow groove on inferior surface of the clavicle but quite a few extended further to attach gradually to the conoid ligament and root of coracoid process to the superior border of the scapula. The muscle was then categorized into 4 types according to its insertion (Table 1). The type I muscle was most commonly found in 82 (64.06%) limbs which inserted to the shallow groove on the inferior surface of the clavicle (Fig. 1). Type II, 23 (17.97%), inserted to the groove and extended to the conoid ligament and root of coracoid process (Fig. 2). Type III, 20 (15.62%), inserted as type II and

further extended to the superior transverse ligament (Fig. 3). Type IV, 3 (2.34%), had its insertion similar to type III and extended over the superior transverse scapular ligament to the superior border of the scapula overlapping to the insertion of the inferior belly of the omohyoid muscle (Fig. 4, Table 2). The type I subclavius muscle was simply cylindrical shaped and looked like lumbricus. Type II-IV, the muscle was flattened, its fleshy insertion gradually expanded to adjacent areas.

Discussion

Recently, studies of the subclavius muscle has been carried out in two aspects, one was the muscular variation or supernumerary muscle and designated as the subclavius posticus muscle⁽¹³⁻¹⁹⁾, another was its clinical relevance on the thoracic outlet syndrome as a possible causative factor especially in imaging techniques^(5-12,22). The variation of this muscle was described as a supernumerary muscle which arose from the superior surface of the sternal end of the first rib, run laterally and dorsocaudally to insert on superior border of the scapula. It was completely independent from the subclavius muscle and inferior belly of the omohyoid muscle^(17,19). According to the insertion site, the type IV muscle in the present study corresponded to the subclavius posticus of the previous works. Incidence of subclavius posticus muscle was reported 4.8% in 248 limbs by Akita⁽¹⁷⁾ while the present work was 2.3% from 124 limbs. There was no obvious separation between subclavius and subclavius posticus muscles in the present study, by contrast, it revealed a gradually extended muscular insertion from the groove for subclavius towards the conoid ligament, coracoid process, the superior transverse scapular ligament and the superior border of the scapula adjacent to the insertion of inferior belly of omohyoid muscle. Therefore, classification of this muscle was assigned into four types. The muscles in type II-IV expanded laterally and dorsally over the subclavius vessels and

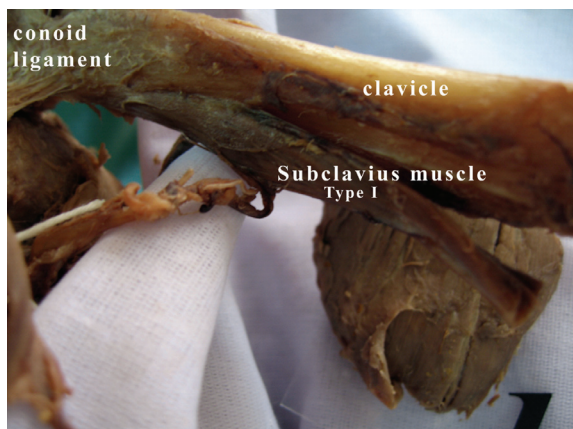


Fig. 1 The subclavius muscle type I inserted to the shallow groove on the inferior surface of clavicle

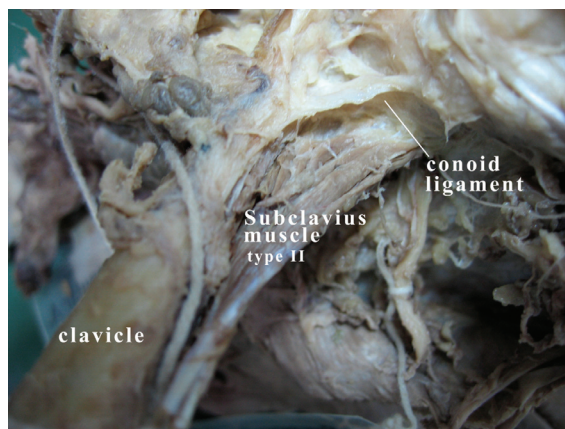


Fig. 2 The subclavius muscle type II inserted to the shallow groove on inferior surface of clavicle and conoid ligament

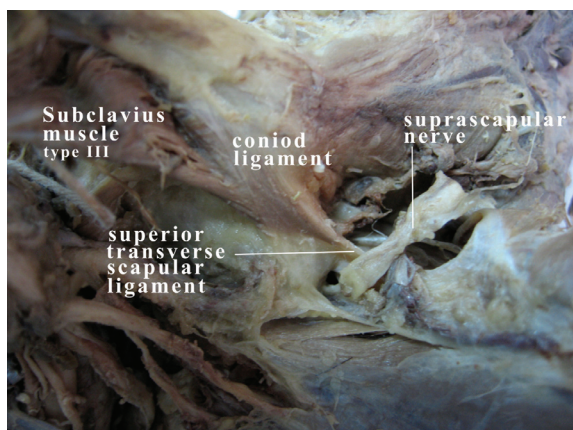


Fig. 3 The subclavius muscle type III inserted to groove for the subclavius muscle, conoid ligament and superior transverse scapular ligament

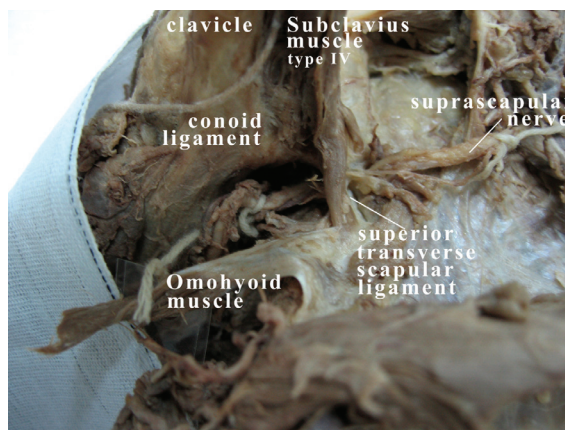


Fig. 4 The subclavius muscle type IV inserted to the groove of the subclavius muscle, conoid ligament, superior transverse scapular ligament and to superior surface of the scapula overlapping with the insertion of omohyoid muscle

brachial plexus. As far as the authors' awareness, this is the first report that demonstrates a gradual extending of the muscle attachment. The type IV muscle which had farthest insertion to the superior border of scapula could cause compression to the structures underneath. Akita's work in 2000 was done in parallel with MR imaging examination of the supraclavicular region of a living normal subject⁽¹⁷⁾. In neutral position, the subclavius vein ran anterior to the apex of the lung and was situated between the clavicle with the subclavius muscle anteriorly, scalenus anterior muscle posteriorly and the first rib inferiorly. In abduction, the medial portion of the subclavius vein was compressed between the clavicle and scalenus anterior muscle

while the lateral portion of the vein was expanded. Furthermore, the MR imaging study of the thoracic outlet during hyperabduction of the arm showed that the clavicle moved backwards, narrowing the costoclavicular space more than 50%⁽⁷⁾. It has been documented that manifestation of compression at the thoracic outlet was related to progressive enlargement of the subclavius muscle system with repetitive compressive trauma to the subclavius vein^(3,20). Ozcakar L et al⁽²¹⁾ recently reported a case of thoracic outlet syndrome after a tractional injury. Physical examination disclosed the significant atrophy of shoulder muscles and generalized hypoesthesia, diminished deep tendon reflexes and also strength in

various muscles. Roos and hyperabduction tests were positive. Electrodiagnostic studies indicated consistent brachial plexopathy. Magnetic resonance imaging showed an aberrant muscle and surgical procedure was performed to remove the subclavius posticus. Thus, the supernumerary subclavius muscle, particular type IV which structurally was converted to a larger muscle could be a possible causative factor in the thoracic outlet syndrome. Even though the present study was carried out on an anatomical setting, it provides the incidence of various types of supernumerary subclavius muscle in Thais which surgeons and radiologists should bear in mind in the clinical significance of this muscle.

Conclusion

The present study prevailed 64% normal subclavius muscle and other 36% of varied supernumerary subclavius muscle. The presence of supernumerary subclavius muscle could be a predisposing causative factor of thoracic outlet syndrome.

References

1. Willium PL, Warwick R, Dyson M, Banniser LH. Gray's anatomy. 38th ed. London: Churchill Livingstons; 1995: 840.
2. Bergman RA, Thompson SA, Afifi AK, Saadeh FA. Compendium of human anatomic variation: text, atlas, and world literature. Baltimore: Urban and Schwarzenberg; 1988: 8.
3. Crerar JW. Note on the absence of the subclavius muscle. *J Anat Physiol* 1892; 26: 554.
4. McCleery RS, Kesterson JE, Kirtley JA, Love RB. Subclavius and anterior scalene muscle compression as a cause of intermittent obstruction of the subclavian vein. *Ann Surg* 1951; 133: 588-602.
5. Demondion X, Herbinet P, Van Sint JS, Boutry N, Chantelot C, Cotten A. Imaging assessment of thoracic outlet syndrome. *Radiographics* 2006; 26: 1735-50.
6. Demondion X, Bacqueville E, Paul C, Duquesnoy B, Hachulla E, Cotten A. Thoracic outlet: assessment with MR imaging in asymptomatic and symptomatic populations. *Radiology* 2003; 227: 461-8.
7. Demondion X, Boutry N, Drizenko A, Paul C, Francke JP, Cotten A. Thoracic outlet: anatomic correlation with MR imaging. *AJR Am J Roentgenol* 2000; 175: 417-22.
8. Remy-Jardin M, Doyen J, Remy J, Artaud D, Fribourg M, Duhamel A. Functional anatomy of the thoracic outlet: evaluation with spiral CT. *Radiology* 1997; 205: 843-51.
9. Matsumura JS, Rilling WS, Pearce WH, Nemcek AA Jr, Vogelzang RL, Yao JS. Helical computed tomography of the normal thoracic outlet. *J Vasc Surg* 1997; 26: 776-83.
10. Sanders RJ, Hammond SL, Rao NM. Diagnosis of thoracic outlet syndrome. *J Vasc Surg* 2007; 46: 601-4.
11. Sanders RJ, Haug C. Subclavian vein obstruction and thoracic outlet syndrome: a review of etiology and management. *Ann Vasc Surg* 1990; 4: 397-410.
12. Davidovic LB, Kostic DM, Jakovljevic NS, Kuzmanovic IL, Simic TM. Vascular thoracic outlet syndrome. *World J Surg* 2003; 27: 545-50.
13. Martin RM, Vyas NM, Sedlmayr JC, Wisco JJ. Bilateral variation of subclavius muscle resembling subclavius posticus. *Surg Radiol Anat* 2008; 30: 171-4.
14. Forcada P, Rodriguez-Niedenfuhr M, Llusca M, Carrera A. Subclavius posticus muscle: supernumerary muscle as a potential cause for thoracic outlet syndrome. *Clin Anat* 2001; 14: 55-7.
15. Shetty P, Pai MM, Prabhu LV, Vadgaonkar R, Nayak SR, Shivanandan R. The subclavius posticus muscle: its phylogenetic retention and clinical relevance. *Int J Morphol* 2006; 24: 599-600.
16. Kutoglu T, Ulucam E, Gurbuz H. A case of the subclavius posticus muscle. *Trakia J Sci* 2005; 3: 77-8.
17. Akita K, Ibukuro K, Yamaguchi K, Heima S, Sato T. The subclavius posticus muscle: a factor in arterial, venous or brachial plexus compression? *Surg Radiol Anat* 2000; 22: 111-5.
18. Sarikcioglu L, Sindel M. A case with subclavius posticus muscle. *Folia Morphol (Warsz)* 2001; 60: 229-31.
19. Akita K, Tsuboi Y, Sakamoto H, Sato T. A case of muscle subclavius posticus with special reference to its innervation. *Surg Radiol Anat* 1996; 18: 335-7.
20. Makhoul RG, Machleder HI. Developmental anomalies at the thoracic outlet: an analysis of 200 consecutive cases. *J Vasc Surg* 1992; 16: 534-42.
21. Ozcakar L, Guney MS, Ozdag F, Alay S, Kiralp MZ, Gorur R, et al. A sledgehammer on the brachial plexus: thoracic outlet syndrome, subclavius posticus muscle, and traction in aggregate. *Arch Phys Med Rehabil* 2010; 91: 656-8.
22. Kolpattil S, Harland R, Temperley D. Case report: a case of subclavius posticus muscle mimicking a mass on mammogram. *Clin Radiol* 2009; 64: 738-40.

กล้ามเนื้อ subclavius ส่วนเกินในคนไทย: ความโน้มเอียงของการเกิด thoracic outlet syndrome

สิทธา ปิยะวิจิวงษ์, นพรัตน์ สิริสภีระ

วัตถุประสงค์: ศึกษาความแปรผันของกล้ามเนื้อ subclavius ในคนไทย และจำแนกตามทีเกาะปลายของกล้ามเนื้อ

วัสดุและวิธีการ: ซ้ำแหละแขนอาจารย์ใหญ่จำนวน 128 แขน เพื่อศึกษาทีเกาะของกล้ามเนื้อ subclavius

ผลการศึกษา: กล้ามเนื้อที่มีทีเกาะต้นที่แน่นอนบนรอยต่อระหว่างซี่โครงคู่ที่หนึ่งและกระดูกอ่อนมีลักษณะเป็นเอ็น ส่วนที่เกาะปลายจะแปรผันโดยเกาะที่แอ่งต้น ๆ ที่ผิวด้านล่างของกระดูกไหปลาร้า บางส่วนยื่นไปติดที่ conoid ligament และส่วนฐานของ coracoid process บางส่วนยื่นเลยไปเกาะที่ superior transverse scapular ligament และบางส่วนยื่นเลยไปเกาะที่ขอบบนของกระดูก scapula ใกล้กับทีเกาะของ inferior belly ของกล้ามเนื้อ omohyoid สามารถแบ่งกล้ามเนื้อออกเป็น 4 แบบตามทีเกาะปลายตามลำดับดังนี้ ชนิดที่ 1 พบ 64.06% ชนิดที่ 2 พบ 17.96% ชนิดที่ 3 พบ 15.62% และชนิดที่ 4 พบ 2.34%

สรุป: การศึกษานี้พบว่ากล้ามเนื้อ subclavius ปกติที่มีทีเกาะที่ผิวล่างของกระดูกไหปลาร้ามี 64% ส่วนที่เหลืออีก 36% เป็นกล้ามเนื้อ subclavius ที่มีทีเกาะปลายที่แผ่เกินไป ซึ่งอาจเป็นสาเหตุของการเกิด thoracic outlet syndrome
