

## Case Report

# Surgical Management of Brunner's Gland Hamartoma causing Upper GI Hemorrhage: Report of Two Cases and Literature Review

Chakrapan Euanorasetr MD\*,  
Pattana Sornmayura MD\*\*

\* Department of Surgery, Faculty of Medicine, Ramathibodi Hospital, Mahidol University, Bangkok, Thailand

\*\* Department of Pathology, Faculty of Medicine, Ramathibodi Hospital, Mahidol University, Bangkok, Thailand

---

*Brunner's gland hamartomas are uncommon benign tumor of the duodenum. Most lesions are small and asymptomatic. Occasionally, those lesions may be large and manifest as a rare cause of upper GI hemorrhage or duodenal obstruction.*

*The authors report here two cases of Brunner's gland hamartoma presenting with upper GI hemorrhage that were not amenable to endoscopic polypectomy thus requiring surgical resection.*

*The literature on Brunner's gland hamartoma was reviewed.*

**Keywords:** Upper GI hemorrhage, Brunner's gland hamartoma, Surgical resection, Gastroduodenoscopy

**J Med Assoc Thai 2010; 93 (10): 1232-7**

**Full text. e-Journal:** <http://www.mat.or.th/journal>

---

Brunner's gland was first described by the Renaissance anatomist, Brunner in 1688, is a gland in the deep mucosa and submucosa of the duodenum<sup>(1-5)</sup>. These glands are lined with large cells that empty into the crypts of Liberkuhn in the duodenum<sup>(6)</sup>. It has a main physiological function of secreting an alkaline-base mucous to protect the duodenal lining from the acid chyme from the stomach<sup>(2,5,7,8)</sup>.

Although the small intestine constitutes 75% of the GI tract, tumors arising from it are rare<sup>(9)</sup>. Small intestine tumors account for about 5% of all GI tract tumors<sup>(9)</sup>. Duodenum constituting only 4% of the small intestine but it has a higher proportion of these tumors than the jejunum and ileum<sup>(9-11)</sup>.

The nomenclature on Brunner's gland lesions is not well established. Feyrter F in 1934 classified three types of Brunner's gland hyperplasia after examining 2,800 duodenums<sup>(12-14)</sup>. Type 1 has diffuse nodular hyperplasia, type 2, the most common type, is circumscribed nodular hyperplasia, and type 3

is adenoma with a single polypoid lesion usually larger than 1 cm in size. Later, it has been suggested that what Feyrter called the Brunner's gland adenoma is better described as hamartoma or Brunneroma<sup>(2,13)</sup>. These names have been used with a substantial degree of interchangeability in the literature<sup>(8,11,12,15)</sup>. These lesions were usually designated a hamartoma based on the lack of cellular atypia. They demonstrated the admixture of normal tissue including Brunner's gland and adipose tissue<sup>(2,15)</sup> and the term Brunner's gland adenoma has fallen out of favor<sup>(8)</sup>.

The distinction between Brunner's gland hyperplasia and hamartoma is arbitrary. At the Armed Forces Institute of Pathology, USA, the following guidelines are used: if the lesion is less than 5 mm, it is called hyperplasia; if greater than 5 mm, it is called hamartoma<sup>(8,16)</sup>. The similar histology of these three groups suggested that each might have the same pathological process<sup>(4)</sup>.

The pathogenesis of Brunner's gland hamartoma remains unclear. It is a rare tumor, accounting for less than 1% of small intestine tumors, 5% of all duodenal tumors, and 11% of benign tumor of the duodenum<sup>(1,2,9,17-21)</sup>.

Brunner's gland hamartoma was firstly described by Cruveilheir in 1835<sup>(6,8,11,12)</sup> and Salvioli

---

**Correspondence to:**

Euanorasetr C, Department of Surgery, Faculty of Medicine, Ramathibodi Hospital, Mahidol University, Bangkok, 10400, Thailand.

Phone: 0-2201-1527-8, Fax: 0-2201-1316

E-mail: [racen@mahidol.ac.th](mailto:racen@mahidol.ac.th)

in 1876<sup>(11,19)</sup>. Since then, this condition has rarely been described in the literature. Until the year 2009, less than 200 cases of Brunner's gland hamartoma have been reported in the English literature<sup>(1,9,12,17,22)</sup>.

Herein, the authors report two cases of Brunner's gland hamartoma of the duodenum causing upper GI hemorrhage that were successfully managed by surgical resection.

## Case Report

### Case 1

A 46-year-old man presented with the chief complaint of passage of black tarry stool for about one month. He denied any recent intake of alcohol or NSAIDs. He had no complaints of nausea, vomiting or abdominal pain. Physical examination revealed no abnormality except pale conjunctiva. Laboratory evaluation showed anemia with the hematocrit of 28%. Other laboratory values were within normal limits. He received two units of pack red cell over the next 24 hours.

Gastroduodenoscopy showed normal stomach with a large submucosal mass in the bulbar part of the duodenum.

Surgery was performed with the presumptive diagnosis of leiomyoma of the duodenum. At operation, a duodenal mass was easily palpated occupying the whole first part of the duodenum. Truncal vagotomy + antrectomy + partial duodenectomy (distal to the lesion) with Bilroth II anastomosis was performed.

Grossly, the resected duodenal specimen showed an elevated submucosal -like- sessile mass measuring 4 x 4.5 x 3 cm in size, with central erosion. Histopathology revealed Brunner's gland hamartoma (Fig. 1). No dysplasia or malignancy was seen within the specimen.

The patient had an uneventful postoperative recovery. He is now symptom-free with no episodes of recurrent melena, nine years after the operation.

### Case 2

A 79-year-old man complained of multiple episodes of melena for one month and one episode of hematemesis four days ago. He denied weight loss or use of NSAIDs or alcohol. He was pale. Other examination revealed no abnormality. His initial hematocrit value was 30%. Other laboratory tests were unremarkable.

Gastroduodenoscopy revealed normal stomach with a large pedunculated polyp in the proximity of the ampulla of Vater.

At laparotomy, the mass was easily palpated. A longitudinal duodenotomy permitted removal of the pedunculated polypoid mass with a base at the posterior wall of the second portion of the duodenum (Fig. 2). The tumor was excised with its base, and the duodenotomy was closed. The ampulla was uninvolved.

The resected specimen showed a pedunculated polyp, measuring 8 cm long and 0.8 cm in diameter (Fig. 3).

The polyp had a lobulated surface with a small area of mucosal erosion. Pathologic examination demonstrated a Brunner's gland hamartoma (Fig. 4). No sign of malignancy was found. The postoperative course was uneventful. During the 6-month follow-up period, the patient remained symptom-free and no further episodes of melena occurred.

## Discussion

In clinical practice, the common causes of upper GI hemorrhage are peptic ulcer disease, gastritis, and esophageal varices<sup>(12)</sup>. In rare instances, duodenal tumors can also be sources of bleeding. These include Brunner's gland hamartomas.

Brunner's gland hamartomas are rare duodenal tumors. Only two cases of these lesions have been in the file of the surgical pathology unit of Ramathibodi Hospital between 1992 and 2005<sup>(23)</sup>.

It is usually found incidentally during gastroscopy or imaging studies because it is small and asymptomatic<sup>(1,2,4,11,19,24)</sup>. In symptomatic patients, clinical manifestation can include upper GI hemorrhage and duodenal obstruction<sup>(1,17,19,20,24)</sup>. Upper GI hemorrhage can occasionally be massive and rarely

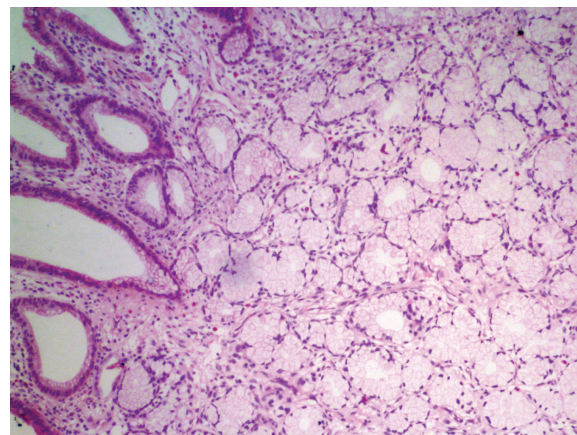
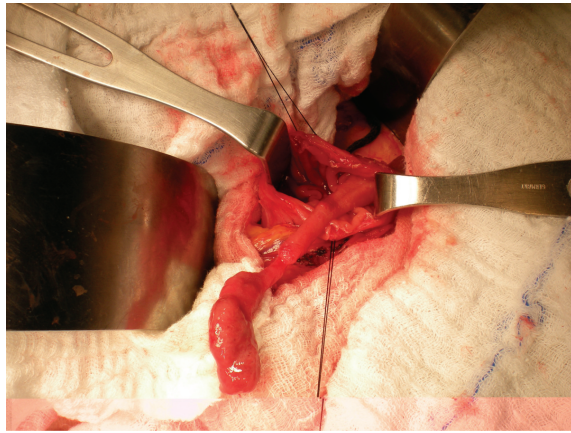
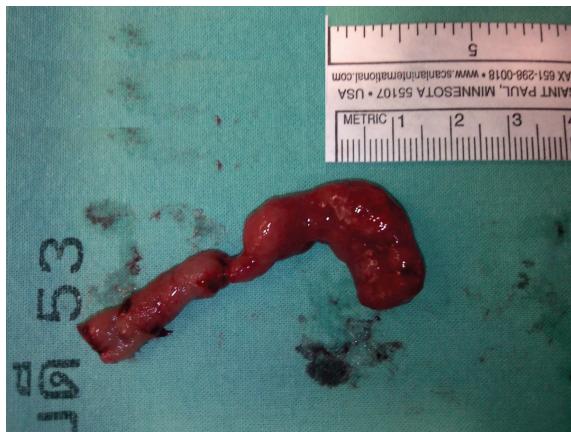

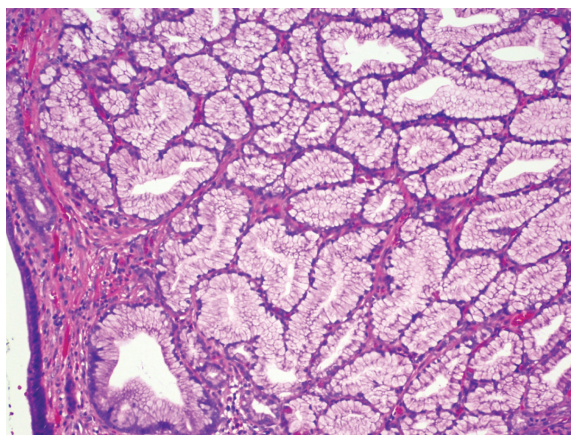
Fig. 1 Brunner's gland hamartoma



**Fig. 2** A pedunculated polypoid mass at the posterior wall of the second portion of the duodenum



**Fig. 3** A pedunculated polyp, measuring 8 cm long and 0.8 cm in diameter



**Fig. 4** Brunner's gland hamartoma

fatal<sup>(22,25)</sup>. The majority of patients are manifested as anemia from chronic blood loss<sup>(5)</sup>. Less frequently, they presented with melena or hematemesis<sup>(3)</sup>. Melena is four times more common than hematemesis. In the presented cases, one presented with melena and the other one with hematemesis and melena.

Rare cases of obstructive jaundice and even pancreatitis, presumably due to obstruction of the ampulla of Vater, have been reported<sup>(9,18)</sup>.

The location of Brunner's gland hamartoma is often at the posterior wall of the duodenal bulb and the incidence decreases with the increase of the distance from the pyloric ring<sup>(1,8,16,22)</sup>. Levine et al from the Mayo Clinic, USA, in 1995 reported a series of 27 Brunner's gland hamartoma and found 70% of cases in the duodenal bulb, 26% in the second part, and 4% in the third part of the duodenum<sup>(26)</sup>. They are either pedunculated (89%) or sessile (11%)<sup>(26)</sup>.

In the presented cases, each was pedunculated and sessile polyp. It was found at the bulbar part in one and at the second part in the other.

Upper GI endoscopy is the diagnostic method of choice<sup>(1,12,17,22)</sup>. The differential diagnosis usually includes leiomyoma, adenoma, lipoma, carcinoid tumor, lymphoma, adenocarcinoma, GIST, and aberrant pancreatic tissue<sup>(1,12,17,22,27)</sup>. However, endoscopic biopsies usually give a negative result owing to the submucosal location of the mass<sup>(1,28,29)</sup>. EUS is considered to be the imaging modality of choice<sup>(4,13,17,30)</sup>. It helps to differentiate between intraluminal and extraluminal mass and to establish a preliminary diagnosis on the layer from which the lesion arises and from the characteristic appearance of the lesion<sup>(4,16,17,31)</sup>. It appears as a heterogeneous lesion with solid and cystic components<sup>(31)</sup>. Of course, the definite diagnosis was usually established on the pathological examination of the resected specimen<sup>(16,22)</sup>. In the presented cases, the diagnosis was made on resected specimens after surgery. EUS may help in the diagnosis of these small lesions without symptoms before an unnecessary surgical resection. However, EUS follow-up on patients treated for Brunner's gland hamartoma is not warranted<sup>(4,11)</sup>.

CT scan is insensitive, only helpful for distinguishing relation of the lesion and its adjacent structures<sup>(11,32)</sup>.

Natural history of the lesion is poorly defined. Block et al in 2000 noted a more than 20-year interval between the initial diagnosis and subsequent development of upper GI hemorrhage<sup>(33)</sup>, suggesting an essentially benign clinical course.

Most reports have described Brunner's gland hamartoma as non-neoplastic and entirely benign lesion. However, Brookes et al in 2003 described a Brunner's gland hamartoma with multiple foci of dysplasia<sup>(20)</sup>. Akino et al in 2002<sup>(34)</sup> and Ohta et al in 2008<sup>(7)</sup> reported two cases of an early duodenal carcinoma arising from Brunner's gland. This can be confused with a lesion of more oncological importance such as duodenal adenoma or adenocarcinoma. Thus, recognition of Brunner's gland hamartoma and differentiation from a malignant tumor is critical for appropriate treatment. Hol et al in 2007<sup>(35)</sup> suggested that previous reports of malignant degeneration of Brunner's gland hamartoma may actually have been cases involving the coexistence of an adenocarcinoma of the ampulla of Vater.

The regression of Brunner's gland hamartoma is very rare<sup>(2)</sup>. It is still controversial whether asymptomatic cases found incidentally needs surgical removal. Most authors suggested that it needs no treatment from the benign nature of this condition<sup>(4,5,11,12,19,20,22,36)</sup>, whereas others hold that it should undergo resection in order to prevent complications and malignant transformation<sup>(27,34)</sup>. The authors agree that resection should be considered only for symptomatic cases. Either endoscopic polypectomy or surgical resection should be performed in symptomatic patients or when definite diagnosis is necessary<sup>(2,5,11,12,19,20,22,37)</sup>.

Endoscopic polypectomy has seldom been reported<sup>(38-41)</sup>. Surgical resection should be considered in the case of a large lesion (> 2 cm) or when malignancy is suspected<sup>(11,16,29)</sup>. Only three cases of Brunner's gland hamartoma treated by pancreaticoduodenectomy have been reported in the literature<sup>(1,2,27)</sup>. In all cases, the authors were concerned about malignancy, although malignancy was not identified on final pathology.

It must be noted that endoscopic polypectomy for the duodenal lesion carries a higher complication rate than colonic polypectomy, due to its proximity to anatomically important structures<sup>(5)</sup>. This is made more hazardous by the potentially poor visualization within the duodenum, and the risk of peristalsis carrying the resected specimen distally and out of reach. The size of the polyp also limits the use of endoscopic polypectomy<sup>(2,5)</sup>.

The authors' two cases were treated surgically because of the significant symptom of upper GI hemorrhage. Although the diagnosis was not known before surgery, the benign nature of the lesion was

suspected. Its size and location hampered endoscopic polypectomy. In the first case, endoscopic resection was not performed because of the large size of the lesion that was occupying entirely the duodenal bulb and the sessile characteristic of the lesion. At operation, the authors found the lesion to have a large sessile polyp not amenable to perform transduodenal polypectomy but the location allowed distal gastrectomy. In the second case, no attempt was made at endoscopic polypectomy due to its large size and the difficulty in gaining access to the base of the pedunculated polyp at the second portion of the duodenum for snaring. At operation, the authors found the large pedunculated polyp amenable to a transduodenal polypectomy.

Up until now, recurrence of a resected Brunner's gland hamatoma has not been documented in the literature. The presented cases had no recurrence after the longest follow-up period of nine years after surgery. The outcome of the operation is excellent.

#### Conclusion

The authors present two rare cases of Brunner's gland hamartoma with upper GI hemorrhage that were successfully treated by surgical resection.

Surgeons should be aware that Brunner's gland hamartoma might cause upper GI hemorrhage. The careful observation of the duodenum is important during endoscopy for the patient with upper GI hemorrhage.

#### Acknowledgement

The authors wish to thank Mrs. Woraporn Sriyodwieng for her assistance in preparing the manuscript.

#### References

1. Stewart ZA, Hruban RH, Fishman EF, Wolfgang CL. Surgical management of giant Brunner's gland hamartoma: case report and literature review. *World J Surg Oncol* 2009; 7: 68.
2. Lee WC, Yang HW, Lee YJ, Jung SH, Choi GY, Go H, et al. Brunner's gland hyperplasia: treatment of severe diffuse nodular hyperplasia mimicking a malignancy on pancreatic-duodenal area. *J Korean Med Sci* 2008; 23: 540-3.
3. Rocco A, Borriello P, Compare D, De Colibus P, Pica L, Iacono A, et al. Large Brunner's gland adenoma: case report and literature review. *World J Gastroenterol* 2006; 12: 1966-8.
4. Stolpman DR, Hunt GC, Sheppard B, Huang H,

- Gopal DV. Brunner's gland hamartoma: a rare cause of gastrointestinal bleeding — case report and review of the literature. *Can J Gastroenterol* 2002; 16: 309-13.
5. Tan YM, Wong WK. Giant Brunneroma as an unusual cause of upper gastrointestinal hemorrhage: report of a case. *Surg Today* 2002; 32: 910-2.
  6. Adeonigbagbe O, Lee C, Karowe M, Feeney M, Wallack M, Montes M, et al. A Brunner's gland adenoma as a cause of anemia. *J Clin Gastroenterol* 1999; 29: 193-6.
  7. Ohta Y, Saitoh K, Akai T, Uesato M, Ochiai T, Matsubara H. Early primary duodenal carcinoma arising from Brunner's glands synchronously occurring with sigmoid colon carcinoma: report of a case. *Surg Today* 2008; 38: 756-60.
  8. Patel ND, Levy AD, Mehrotra AK, Sobin LH. Brunner's gland hyperplasia and hamartoma: imaging features with clinicopathologic correlation. *AJR Am J Roentgenol* 2006; 187: 715-22.
  9. Bal A, Joshi K, Vaiphei K, Wig JD. Primary duodenal neoplasms: a retrospective clinico-pathological analysis. *World J Gastroenterol* 2007; 13: 1108-11.
  10. Peison B, Benisch B. Brunner's gland adenoma of the duodenal bulb. *Am J Gastroenterol* 1982; 77: 276-8.
  11. de Nes LC, Ouwehand F, Peters SH, Boom MJ. A large Brunner's gland hamartoma causing gastrointestinal bleeding and obstruction. *Dig Surg* 2007; 24: 450-2.
  12. Chattopadhyay P, Kundu AK, Bhattacharyya S, Bandyopadhyay A. Diffuse nodular hyperplasia of Brunner's gland presenting as upper gastrointestinal haemorrhage. *Singapore Med J* 2008; 49: 81-3.
  13. Becker SA, Ziv-Sokolovskya N. Brunner's gland hamartoma of the duodenum (Brunneroma). *Isr Med Assoc J* 2004; 6: 702-3.
  14. GOLDMAN RL. Hamartomatous polyp of Brunner's glands. *Gastroenterology* 1963; 44: 57-62.
  15. Fadare O. Images in pathology: brunner's gland hamartoma. *Int J Surg Pathol* 2002; 10: 294.
  16. Yadav D, Hertan H, Pitchumoni CS. A giant Brunner's gland adenoma presenting as gastrointestinal hemorrhage. *J Clin Gastroenterol* 2001; 32: 448-50.
  17. Coriat R, Mozer-Bernardeau M, Terris B, Chrysostalis A, Prat F, Chaussade S. Endoscopic resection of a large Brunner's gland hamartoma. *Gastroenterol Clin Biol* 2008; 32: 11-4.
  18. Stermer E, Elias N, Keren D, Rainis T, Goldstein O, Lavy A. Acute pancreatitis and upper gastrointestinal bleeding as presenting symptoms of duodenal Brunner's gland hamartoma. *Can J Gastroenterol* 2006; 20: 541-2.
  19. Gao YP, Zhu JS, Zheng WJ. Brunner's gland adenoma of duodenum: a case report and literature review. *World J Gastroenterol* 2004; 10: 2616-7.
  20. Brookes MJ, Manjunatha S, Allen CA, Cox M. Malignant potential in a Brunner's gland hamartoma. *Postgrad Med J* 2003; 79: 416-7.
  21. Botsford TW, Crowe P, Crocker DW. Tumors of the small intestine. A review of experience with 115 cases including a report of a rare case of malignant hemangio-endothelioma. *Am J Surg* 1962; 103: 358-65.
  22. Hirasaki S, Kubo M, Inoue A, Miyake Y, Oshiro H. Pedunculated Brunner's gland hamartoma of the duodenum causing upper gastrointestinal hemorrhage. *World J Gastroenterol* 2009; 15: 373-5.
  23. Woharndee P, Sornmayura P, Bunyaratvej S. Brunner's gland adenoma: a report of two cases. *J Med Assoc Thai* 2005; 88: 841-4.
  24. Bastounis E, Pikoulis E, Leppaniemi A, Tsetis D, Tsetis A. Polypoid hamartoma of Brunner's gland of the duodenum. *Dig Surg* 1999; 16: 431-3.
  25. Schluger LK, Rotterdam H, Lebwohl O. Gastrointestinal hemorrhage from a Brunner's gland hamartoma. *Am J Gastroenterol* 1994; 89: 2088-9.
  26. Levine JA, Burgart LJ, Batts KP, Wang KK. Brunner's gland hamartomas: clinical presentation and pathological features of 27 cases. *Am J Gastroenterol* 1995; 90: 290-4.
  27. Iusco D, Roncoroni L, Violi V, Donadei E, Sarli L. Brunner's gland hamartoma: 'over-treatment' of a voluminous mass simulating a malignancy of the pancreatic-duodenal area. *JOP* 2005; 6: 348-53.
  28. Gourtsoyiannis NC, Zarifi M, Gallis P, Mouchtouris A, Livaditou A. Radiologic appearances of Brunner's gland adenoma: a case report. *Eur J Radiol* 1990; 11: 188-90.
  29. Perez A, Saltzman JR, Carr-Locke DL, Brooks DC, Osteen RT, Zinner MJ, et al. Benign nonampullary duodenal neoplasms. *J Gastrointest Surg* 2003; 7: 536-41.
  30. Mumtaz R, Shah IA, Ramirez FC. Brunner's gland hamartoma simulating a pancreatic mass with duodenal obstruction. *Gastrointest Endosc* 2002; 56: 932-4.

31. Hizawa K, Iwai K, Esaki M, Suekane H, Inuzuka S, Matsumoto T, et al. Endosonographic features of Brunner's gland hamartomas which were subsequently resected endoscopically. *Endoscopy* 2002; 34: 956-8.
32. Buckley JA, Jones B, Fishman EK. Small bowel cancer. Imaging features and staging. *Radiol Clin North Am* 1997; 35: 381-402.
33. Block KP, Frick TJ, Warner TF. Gastrointestinal bleeding from a Brunner's gland hamartoma: characterization by endoscopy, computed tomography, and endoscopic ultrasound. *Am J Gastroenterol* 2000; 95: 1581-3.
34. Akino K, Kondo Y, Ueno A, Yamazaki K, Hosokawa M, Shimoji H, et al. Carcinoma of duodenum arising from Brunner's gland. *J Gastroenterol* 2002; 37: 293-6.
35. Hol JW, Stuijbergen WN, Teepen JL, van Laarhoven CJ. Giant Brunner's hamartomas of the duodenum and obstructive jaundice. An overview of the literature and suspicion of malignancy in a case. *Dig Surg* 2007; 24: 452-5.
36. Shemesh E, Ben Horin S, Barshack I, Bar-Meir S. Brunner's gland hamartoma presenting as a large duodenal polyp. *Gastrointest Endosc* 2000; 52: 435-6.
37. de Silva S, Chandrasoma P. Giant duodenal hamartoma consisting mainly of Brunner's glands. *Am J Surg* 1977; 133: 240-3.
38. Matsumoto T, Iida M, Matsui T, Yao T, Fujishima M. A large Brunner's gland adenoma removed by endoscopic polypectomy. *Endoscopy* 1990; 22: 192-3.
39. Jansen JM, Stuijbergen WN, van Milligen de Wit AW. Endoscopic resection of a large Brunner's gland adenoma. *Neth J Med* 2002; 60: 253-5.
40. Rajagopalan S, al Arrayed S, Dhiman RK. Brunner's gland polyp with upper gastrointestinal bleeding managed by endoscopic polypectomy: a report of two cases. *Trop Gastroenterol* 2003; 24: 133-4.
41. Tai M, Yoshikawa I, Kume K, Murata I, Otsuki M. A large Brunner's gland hamartoma resected by endoscopic polypectomy. *Gastrointest Endosc* 2001; 53: 207-8.

---

การผ่าตัดรักษาภาวะเลือดออกจากทางเดินอาหารส่วนบนที่เกิดจาก Brunner's gland hamartoma: รายงานผู้ป่วย 2 รายและการทบทวนวารสารทางการแพทย์

จักรพันธ์ เอื้อนรเศรษฐ์, พัฒนา ศรีมยุรา

*Brunner's gland hamartoma* เป็นเนื้องอก ชนิดไม่ไ้มะเร็งของ duodenum ที่พบได้ไม่บ่อย เนื้องอกส่วนใหญ่จะมีขนาดเล็ก และไม่มีอาการ มีเพียงบางครั้ง ที่เนื้องอกชนิดนี้จะโตและทำให้เกิดอาการเลือดออกจากทางเดินอาหารส่วนบน หรือ การอุดตันของ duodenum ซึ่งพบน้อยมาก

ผู้นิพนธ์ได้รายงานผู้ป่วย 2 ราย ที่มีอาการเลือดออกจากทางเดินอาหารส่วนบน จาก Brunner's gland hamartoma ที่ไม่สามารถรักษาด้วยการตัดชิ้นเนื้องอกด้วยการส่องกล้องได้ จึงทำการรักษาด้วยการผ่าตัดทางช่องท้อง ผู้นิพนธ์ได้ทบทวนรายงานจากวารสารต่าง ๆ ที่เกี่ยวข้องกับ Brunner's gland hamartoma