

Fractures of the Hyoid Bone and Thyroid Cartilage in Suicidal Hanging

Nantana Charoonnate MD*,
Paitoon Narongchai MD*, Somsak Vongvaivet MD*

* Department of Forensic Medicine, Faculty of Medicine, Chiang Mai University, Chiang Mai, Thailand

Objective: To analyze the frequency of hyoid bone and thyroid cartilage fractures caused by suicidal hanging in Thai people and compare the different methods of visualizing the those fractures. Results could be used for forensic purposes.

Material and Method: A prospective study of hyoid bone and thyroid cartilage fractures in Thai people who died from suicidal hanging between November 2008 and August 2009. The authors confirmed suicides, based on history, crime scene investigation, autopsy reports, and other police information, visual and palpatory examination, and stereomicroscopy with or without 1% Toluidine. Neck dissection was performed following the protocol of Prinsloo and Gordon. Results and data analysis were performed via SPSS version 16.

Results: Twenty male cases of suicidal hanging were reviewed. Fractures of the hyoid bone and/or thyroid cartilage were found in five cases (25%). Two cases of the hyoid bone fracture, two cases of thyroid cartilage fracture, and one case was both bone fractures. Mean age of all cases, non-fracture, and fracture cases were 42.40, 35.93, and 61.80 years, respectively. The knot was at the back of the neck in most cases (12 cases, 60%) and at the left, front, and right in four, two, and two cases, respectively. However, there was no relation between location of the knot at the neck and fractures of hyoid bone and thyroid cartilage ($p=1$). Incomplete and complete hanging were found in 11 and nine cases. Five cases with fractures of the hyoid bone and/or thyroid cartilage were incomplete hanging. The visual and palpatory examination did not detect the fracture of hyoid bone in all 20 cases but stereomicroscopy and stereomicroscopy with Toluidine blue stain detected fracture in three cases. For detecting thyroid cartilage fractures, all three methods had the same result.

Conclusion: Fractures of the hyoid bone and thyroid cartilage in 25% of Thais who died of suicidal hanging were related with older ages and incomplete hanging but not related with location of the knot. The stereomicroscopic method is fast and effective in detecting fractures of the hyoid bone and thyroid cartilage.

Keywords: Hyoid bone, Thyroid cartilage, Suicidal hanging, Stereomicroscopic method, Toluidine

J Med Assoc Thai 2010; 93 (10): 1211-6

Full text. e-Journal: <http://www.mat.or.th/journal>

Hanging is a form of ligature strangulation in which the force applied to the neck is derived from the gravitational drag of the body weight⁽¹⁻⁷⁾. Most hangings are suicides, while only a few are accidents or homicides⁽¹⁻⁹⁾. As a method of suicide, hanging is found as frequently as drug use or poisoning^(5,10-13). The position of the knot of hanging is very important because it can cause unequal pressure to the neck and result in different injuries to the organs⁽¹⁴⁾. The type of hanging can be divided by pressure into two groups, complete and incomplete hanging. Complete hanging is a hanging in which the full body weight acts

upon the ligature and places pressure on the neck, Incomplete hanging is a hanging in which some organs touch the floor, using only part of the body weight to load and cause pressure to the neck^(1,2,9). Fractures of the hyoid bone and thyroid cartilage are important pathogenesis to forensic science, especially when death is caused by neck pressure, manual strangulation, or ligature strangulation from homicide^(1-3,8,9,13), as it can be found in suicidal hanging. However, information ranges from 0%-76.6%^(3-6,15,20) depending on study methods and diagnosis procedures of the fractures. For these reasons, the present study analyzed the frequency of the hyoid bone and thyroid cartilage fractures in Thai people caused by suicidal hanging. It also compared and diagnosed those fractures by different methods and uses these results for forensic purposes.

Correspondence to:

Narongchai P, Department of Forensic Medicine, Chiang Mai University, Chiang Mai 50200, Thailand.

Phone & Fax: 053-945-432-4

E-mail: pnarongc@med.cmu.ac.th or paitoon6@hotmail.com

Material and Method

The present study was a pilot study conducted as a prospective study of the fractures of the hyoid bone and thyroid cartilage in Thai people who died from by suicidal hanging. It was conducted at the Department of Forensic Medicine, Faculty of Medicine, Chiang Mai University, over a 10-month period between November 2008 and August 2009. The authors only used bodies from confirmed suicides, based on history, crime scene investigation, autopsy reports and other police information, to conduct a study of the relation of factors related to the fractures. The data collected included age, sex, location of the knot, and type of suspension. In the present study, fracture means an ante-mortem fracture in which hemorrhage was detected at the fracture site via stereomicroscopic. The location of the knot was divided into left, right, front, and back. Neck dissection was performed after evisceration of the other body organs, following the protocol of Prinsloo and Gordon⁽¹⁶⁾. Hyoid bone and thyroid cartilage fractures were detected using visual and palpatory examination before examining the bones with a stereomicroscope. Next, 1% Toluidine blue solution was applied to both pieces of bone, left for 15 seconds and cleaned off with pure water. The bones were re-examined with a stereomicroscope and the results were recorded in order to compare the efficiency of hyoid bone and thyroid cartilage fractures detection. Cases were omitted from the present study if death occurred more than 24 hours prior, if there were congenital anomalies of the hyoid bone and/or thyroid cartilage or if the manner of death was unknown. Results and data analysis were performed via SPSS version 16 using Chi-Square Test, Fisher’s Exact Test, Independent t-test, Kolmogorov-Smirnov Test and Phi Coefficient.

The whole study was supervised according to the ethical standards by a Research Ethics Committee 3 on human experimentation (reference No.395/2008).

Results

During the 10 months of present study, there were 20 cases of suicidal hanging, all male. Of these, fractures of the hyoid bone and/or thyroid cartilage were found in five cases (25%) (Fig. 1). Only hyoid bone fracture was found in two cases (10%), only thyroid cartilage fracture was found in two cases (10%), and both bone fractures were found in one case (5%). Hyoid bone fracture was found at the greater horn in one case and at the lesser horn in two cases. Thyroid

Table 1. Frequency of fracture sites of hyoid bone and thyroid cartilage

Hyoid bone		Thyroid cartilage	
Fracture site	Frequency	Fracture site	Frequency
Greater horn	1	Superior horn	3
Lesser horn	2	Inferior horn	0
Body	0	Body	0
Total	3	Total	3

cartilage fracture was found at the superior horn in three cases (Table 1). In the case with both fractures, they were found at the lesser horn of the hyoid bone and the superior horn of the thyroid cartilage (Table 2).

Age

There were 20 cases aged 20-78 years with a mean age of 42.40 years. The mean age of the group in which fractures of hyoid bone or thyroid cartilage were not detected (15 cases) was 35.93 years, and the mean age of the group in which bone fracture was detected (5 cases) was 61.80 years. The group in which bones fractures were detected had a higher mean age and the difference was statistically significant (t-test = -4.152, p=0.001).

Location of the knot

The knot was at the back of the neck in most cases (12 cases, 60%). It was on the left in four cases (20%), on the front in two cases (10%) and on the right in two cases (10%). Of the case with fractures of the hyoid bone or thyroid cartilage, four cases were hung with the knot on the back of the neck, and one case was hung with the knot on the left (Fig. 2). However, there was no relation between location of the knot at the neck and fractures of hyoid bone and thyroid cartilage (p = 1).

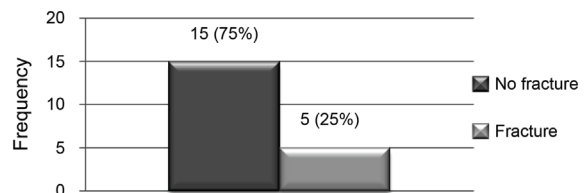


Fig. 1 Fracture frequency

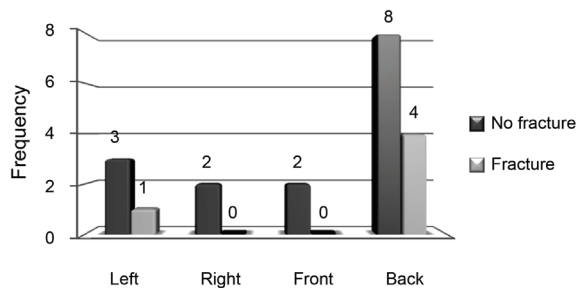


Fig. 2 Location of the knot and fractures distribution

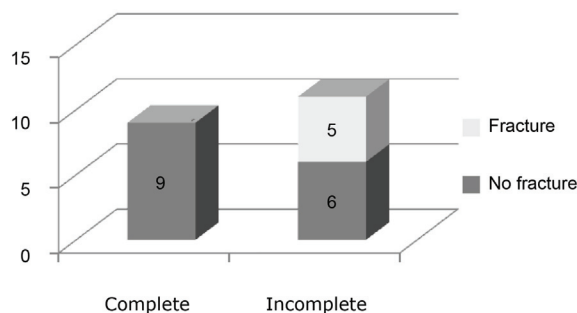


Fig. 3 Suspension and fractures distribution

Type of suspension

Incomplete hanging was found slightly more than complete hanging, 11 cases (55%), and nine cases (45%) respectively. Five cases with fractures of hyoid bone and/or thyroid cartilage were incomplete hanging (Fig. 3). Therefore, it is not surprising to find that type of suspension relates with fractures of the hyoid bone and thyroid cartilage with statistical significance ($p = 0.038$) and moderate relation level ($\Phi = 0.522$).

Effectiveness of different methods

The result of three different methods to detect hyoid bone fracture are 1) visual and palpatory examination did not detect the fracture of hyoid bone in all 20 cases, 2) stereomicroscopy, and 3) stereomicroscopy with Toluidine blue stain each detected fracture of the hyoid bone in three cases and did not detect the fractures in 17 cases (Table 3). For detecting thyroid cartilage fractures, all three methods have the same result, they detected fractures

Table 2. Summary of cases in which fractures were detected

Age	Gender	Knot	Suspension	Fracture
78	Male	Left	Incomplete	Left lesser hyoid horn, Left superior thyroid horn
68	Male	Back	Incomplete	Left lesser hyoid horn
47	Male	Back	Incomplete	Both superior thyroid horns
48	Male	Back	Incomplete	Right superior thyroid horn
68	Male	Back	Incomplete	Right greater hyoid horn

Table 3. Detection results of hyoid bone fracture with each method

Hyoid bone	Visual & Palpate	Stereomicroscopy	Stereomicroscopy + Toluidine
No fracture	20	17	17
Fracture	0	3	3

Table 4. Detection results of thyroid cartilage fracture with each method

Thyroid cartilage	Visual & Palpate	Stereomicroscopy	Stereomicroscopy + Toluidine
No fracture	17	17	17
Fracture	3	3	3

of thyroid cartilage in three cases and did not detect them in 17 cases (Table 4).

Discussion

Fractures of the hyoid bone and/or thyroid cartilage were detected in 25% of the suicidal hanging cases: 10% of hyoid bone fractures, 10% of thyroid cartilage fractures, and 5% of both bone fractures. Green et al (2000) did a prospective study of 40 cases of suicidal hanging in Australia and detected hyoid bone and/or thyroid cartilage fractures in 47.5%⁽¹⁷⁾. Paparo and Siegel (1984) studied cases of suicidal hanging in both retrospective and prospective studies. They found fractures of the hyoid bone and thyroid cartilage in 20% and 46% in a prospective study⁽¹⁸⁾. However, many studies were considered retrospective studies and had a high frequency of bone fractures such as 45-68%^(4,6,19,20). Moreover, defining fractures only as ante-mortem fractures can cause the present study to have a lower frequency of fractures than studies that do not rule out postmortem fractures.

In the present study, fractures of the hyoid bone and thyroid cartilage were detected equally. This differs from most studies, which detected thyroid cartilage more frequently^(4,17,21). However, those studies diagnosed fractures via visual and palpatory examination. The anatomical location of the hyoid bone is located deeper along the mandible bone and part of the horn down to the back, which can make detection difficult. Fractures of the hyoid bone were detected only at the lesser horn in two cases and at the greater horn in one case. There were three cases of superior horn of thyroid cartilage fracture and agrees with the result of Betz and Eisenmenger⁽²⁰⁾. It may be caused by size and shape of the horn that sticks out from the body, so that fractures can occur more frequently.

Regarding fractures of the superior horn of thyroid cartilage, ligature marks are mostly narrow and often located higher than thyroid notch and causes more pressure than the position of the body or the inferior horn of the thyroid. Moreover, another possible mechanism is the ligature pressure that causes stretching of the thyrohyoid membrane. On the other hand, Sharma et al (2008) found that the fractures of the horn and body of the hyoid bone were equal and were found more frequently at the body than at the horn of thyroid cartilage in India. This could be because the material used for hanging was a sari or a chunni, which is soft material and broad ligature, placing more pressure on the body of the thyroid than in other studies⁽²²⁾.

Age

Mean age of the group in which bone fractures were detected was higher than the undetected group with statistical significance ($p = 0.001$) and has relation with both bone fracture. In the present study, the youngest person in whom bone fractures were found was 47 years old, and almost all the bone fractures that were not detected were less than 47 years old. In previous studies, bone fractures can be detected in persons older than 30 years^(4,6,17,20,22) while Paparo and Siegel (1984) and Simonsen (1988) noted that fractures were found in all age groups above 19 and 25 years of age, respectively^(18,19). Advanced ossification of the hyoid bone and thyroid cartilage is responsible for the increased frequency of fractures in older people^(1-4,13,14,17,20,22).

Gender

Since all 20 cases were male, gender cannot be studied as a factor. Previous studies have found more fractures in males^(17,19), more fractures in women⁽¹⁸⁾, and no gender association in fractures^(5,21,22).

Location of the knot

In previous studies, the knot was on the back of the neck in 60% of the cases, on the side in 30% (20% on the left and 10% on the right) and on the front or under the chin in 10%^(1-4,9,13,19,20). In the present study, the knot was most frequently on the back of the neck in bone fractures (33%, 4 of 12 cases). It was on the left in 25% of bone fractures. Statistical comparison showed no relation between knot location and fractures of the hyoid bone and thyroid cartilage ($p = 1$). This was similar to studies by Nikolic⁽⁴⁾ and Suarez-Penaranda⁽⁵⁾.

Type of suspension

Incomplete hanging was slightly more frequent than complete hanging at 55% and 45%^(6,17,21). It is interesting that all fractures of the hyoid bone and thyroid cartilage were in the incomplete hanging group, while the present study found no fracture in the complete hanging group. In contrast, the study of Sharma et al (2008) found fractures in complete hanging more frequent⁽²²⁾. However, in the present study, incomplete hanging related with fractures of the hyoid bone and thyroid cartilage to a statistically significant degree ($p = 0.038$). The possible explanation is that there is less pressure on the neck, which leads to cerebral hypoxia and gradually causes a longer convulsion phase.

Effectiveness of different methods

It was found that visual and palpatory examination could not detect fractures of the hyoid bone, but that all three methods are equally effective in detecting thyroid cartilage fractures. This can be explained by the anatomical position of the hyoid bone, which is taller and deeper in the neck, smaller size of the lesser horn, and greater horn that entwine in the back of the neck to make visualizing fractures and hemorrhages more difficult. Moreover, the ligaments tend to stick, meaning there is no displacement to detect. Stereomicroscopy with Toluidine blue stain has the same results as the stereomicroscopic method. It was also found that dying with 1% of Toluidine blue is quite complicated. Moreover, it can be difficult to see the difference between the blue-green of the fracture position and the purple blue of the surrounding tissue. In short, the stereomicroscopic method may be adequate. In cases where problems remain difficult to detect, the authors should use other methods such as radiography or complete preparation with stereomicroscopy. Khokhlov (1997) found that these methods were much more effective than visual and palpatory examination⁽¹⁵⁾.

Conclusion

The present study found fractures of the hyoid bone and thyroid cartilage in 25% of Thais who died due to suicidal hanging. The factors that related with the fractures to a statistically significant degree were older ages and incomplete hanging. Location of the knot at the neck had no relation with the fractures.

Visual and palpatory examination may give false negative results in detecting fractures of the hyoid bone. Stereomicroscopy with Toluidine blue stain, meanwhile, is complicated and no more effective than the stereomicroscopic method. Therefore, the authors highly recommend using the "stereomicroscopic method" as it is convenient, fast, and effective in detecting fractures of the hyoid bone and thyroid cartilage.

References

1. Hunvichit U. Hanging. In: Ingkatanuwat M, Hunvichit U, Wathanakhajorn T, editors. Forensic medicine 1. Faculty of Medicine, Chulalongkorn University. Bangkok: Chulalongkorn University; 1999: 194-9.
2. Saukko P, Knight B. Fatal pressure on the neck. In: Saukko P, Knight B, editors. Knight's forensic pathology. 3rd ed. London: Edward Arnold; 2004: 368-94.
3. Dimaio VJM, Dimaio D. Hanging. In: Dimaio VJM, Dimaio D, editors. Forensic pathology. 2nd ed. Florida: CRC Press; 2001: 180, 247-56.
4. Nikolic S, Micic J, Atanasijevic T, Djokic V, Djonic D. Analysis of neck injuries in hanging. Am J Forensic Med Pathol 2003; 24: 179-82.
5. Suarez-Penaranda JM, Alvarez T, Miguens X, Rodriguez-Calvo MS, de Abajo BL, Cortesao M, et al. Characterization of lesions in hanging deaths. J Forensic Sci 2008; 53: 720-3.
6. Uzun I, Buyuk Y, Gurpinar K. Suicidal hanging: fatalities in Istanbul retrospective analysis of 761 autopsy cases. J Forensic Leg Med 2007; 14: 406-9.
7. Kumar V. Hanging without knot in the noose. J Forensic Leg Med 2007; 14: 35-8.
8. Huiprasert L. Asphyxia. In: Huiprasert L, editor. Forensic medicine. 2nd rev. ed. Bangkok: Royal Police Cadet Academy; 2000: 151-67.
9. Purdue BN. Hanging. In: Mason JK, Purdue BN, editors. The pathology of trauma. 3rd ed. London: Edward Arnold; 2000: 244-7.
10. Burns A, Goodall E, Moore T. A study of suicides in Londonderry, Northern Ireland, for the year period spanning 2000-2005. J Forensic Leg Med 2008; 15: 148-57.
11. Havasi B, Magori K, Toth A, Kiss L. Fatal suicide cases from 1991 to 2000 in Szeged, Hungary. Forensic Sci Int 2005; 147(Suppl): S25-8.
12. Mohanty S, Sahu G, Mohanty MK, Patnaik M. Suicide in India: a four year retrospective study. J Forensic Leg Med 2007; 14: 185-9.
13. Spitz WU. Hanging. In: Spitz WU, editor. Spitz and Fisher's medicolegal investigation of death. 4th ed. Springfield: Charles C Thomas; 1993: 784-806.
14. Aiongpraparn W. Asphyxia. In: Aiongpraparn W, editor. Forensic medicine. 4th ed. Bangkok: Numkungkarnpim; 1987: 338-42.
15. Khokhlov VD. Injuries to the hyoid bone and laryngeal cartilages: effectiveness of different methods of medico-legal investigation. Forensic Sci Int 1997; 88: 173-83.
16. Prinsloo I, Gordon I. Post-mortem dissection artifacts of the neck; their differentiation from ante-mortem bruises. S Afr Med J 1951; 25: 358-61.
17. Green H, James RA, Gilbert JD, Byard RW. Fractures of the hyoid bone and laryngeal cartilages in suicidal hanging. J Clin Forensic Med 2000; 7: 123-6.
18. Paparo GP, Siegel H. Neck markings and fractures

- in suicidal hangings. Forensic Sci Int 1984; 24: 27-35.
19. Simonsen J. Patho-anatomic findings in neck structures in asphyxiation due to hanging: a survey of 80 cases. Forensic Sci Int 1988; 38: 83-91.
 20. Betz P, Eisenmenger W. Frequency of throat-skeleton fractures in hanging. Am J Forensic Med Pathol 1996; 17: 191-3.
 21. Feigin G. Frequency of neck organ fractures in hanging. Am J Forensic Med Pathol 1999; 20: 128-30.
 22. Sharma BR, Harish D, Sharma A, Sharma S, Singh H. Injuries to neck structures in deaths due to constriction of neck, with a special reference to hanging. J Forensic Leg Med 2008; 15: 298-305.
 23. Polson CJ. Hanging. In: Polson CJ, Gee DJ, Knight B, editors. The essential of forensic medicine. 4th ed. London: Pergamon; 1985: 357-88.

กระดูกไฮออยด์และกระดูกอ่อนไทรอยด์แตกหักในศพที่แขวนคอฆ่าตัวตาย

นันทนา จรุงนตร, ไพฑูรย์ ณรงค์ชัย, สมศักดิ์ วงษ์ไวยเวช

วัตถุประสงค์: เพื่อวิเคราะห์การแตกหักของกระดูกไฮออยด์และกระดูกอ่อนไทรอยด์ในคนไทยที่แขวนคอเพื่อฆ่าตัวตาย และเปรียบเทียบวิธีการวินิจฉัยวิธีต่าง ๆ เพื่อประโยชน์ในงานนิติเวชศาสตร์

วัสดุและวิธีการ: การศึกษากระดูกไฮออยด์และกระดูกอ่อนไทรอยด์หักนี้เป็นการศึกษาแบบไปข้างหน้า ระหว่างเดือนพฤศจิกายน พ.ศ. 2551 ถึง เดือนสิงหาคม พ.ศ. 2552 การวินิจฉัยว่าแขวนคอเพื่อฆ่าตัวตายโดยอาศัยประวัติ การตรวจสถานที่เกิดเหตุ การตรวจชันสูตรพลิกศพ การตรวจทางห้องปฏิบัติการ การสอบสวนของเจ้าหน้าที่ตำรวจ และการตรวจด้วยกล้องสแตโรไอไมโครสโคป สำหรับการวิเคราะห์ข้อมูลใช้โปรแกรม เอสพีเอสเอส

ผลการศึกษา: การแขวนคอเพื่อฆ่าตัวตายมีทั้งหมด 20 ศพ และเป็นเพศชายทั้งหมด พบมีกระดูกไฮออยด์ และหรือกระดูกอ่อนไทรอยด์หักมีจำนวน 5 ศพ สำหรับอายุเฉลี่ยของศพทั้งหมด ศพที่ไม่มีกระดูกหัก และศพที่มีกระดูกหักคือ 42.4, 35.9 และ 61.8 ปี ตามลำดับ ส่วนปมของเชือกที่แขวนคอจะอยู่ด้านหลังคอกมากที่สุด รองลงมาปมอยู่ด้านซ้าย แต่ไม่พบความแตกต่างอย่างมีนัยสำคัญทางสถิติ ลักษณะการแขวนคอแบบไม่สมบูรณ์ และสมบูรณ์มีจำนวนใกล้เคียงกัน คือ 11 ศพ และ 9 ศพ ทั้ง 5 ศพ ที่มีการแตกหักของกระดูกอย่างใดอย่างหนึ่ง หรือ ทั้งสองชิ้นเป็นการแขวนคอแบบไม่สมบูรณ์ การดูและการคลำไม่สามารถวินิจฉัยการแตกของกระดูกไฮออยด์ได้เลย แต่การตรวจด้วยสแตโรไอไมโครสโคป ทั้งที่ไม่มีและมีการข้อมสีโหลไวดีนสามารถตรวจกระดูกไฮออยด์แตกหักได้จำนวน 3 ศพ แต่การตรวจวินิจฉัยกระดูกอ่อนไทรอยด์แตกหักนั้นทั้ง 3 วิธี สามารถตรวจพบกระดูกแตกหักโดยไม่มี ความแตกต่างกัน

สรุป: การแตกหักของกระดูกไฮออยด์และกระดูกอ่อนไทรอยด์พบจำนวนร้อยละ 25 ของคนไทยที่ฆ่าตัวตาย โดยการแขวนคอ ซึ่งมีความสัมพันธ์กับอายุและลักษณะการแขวนคอแบบไม่สมบูรณ์ และไม่สัมพันธ์กับตำแหน่งของปมเชือกที่ใช้แขวนคอ การตรวจด้วยวิธีสแตโรไอไมโครสโคปเป็นวิธีที่ตรวจได้อย่างรวดเร็ว และมีประสิทธิภาพในการตรวจการแตกหักของกระดูกไฮออยด์ และหรือ กระดูกอ่อนไทรอยด์