

Case Report

Acute Appendicitis as Primary Symptom of Prostatic Adenocarcinoma: Report of a Case

Samrerng Ratanarapee MD*,
Chaiyong Nualyong MD**

* Department of Pathology, Faculty of Medicine Siriraj Hospital, Mahidol University, Bangkok, Thailand

** Division of Urology, Department of Surgery, Faculty of Medicine Siriraj Hospital, Mahidol University, Bangkok, Thailand

The most common disease of appendix is acute appendicitis. There have been at least 20 case reports of metastasis-induced appendicitis in English literature. The authors reported a 62-year-old Thai man who underwent appendectomy due to classical symptoms and signs of acute appendicitis and was subsequently referred to Siriraj Hospital for proper management after a pathological report of metastatic adenocarcinoma to the appendix. By morphology, the primary site was thought to be the prostate gland. Confirmation was done based on serum PSA study, transrectal ultrasound-guided core needle biopsy, and review of the material from Hua Hin Hospital. Orchidectomy was performed with satisfactory outcome. The patient was doing well for two years before upper gastrointestinal hemorrhage and obstructive jaundice caused by another aggressive tumor developed. He died of the second tumor associated with subsequent renal failure in spite of good response to orchidectomy.

Keywords: Appendicitis, Metastatic prostatic carcinoma, Prostatic adenocarcinoma

J Med Assoc Thai 2010; 93 (11): 1327-31

Full text. e-Journal: <http://www.mat.or.th/journal>

The appendix is a rudimentary structure with no obvious function arising from the medial wall of the cecum. Prominent lymphoid tissue in the mucosa, which is particularly prominent during adolescence, and neurogenous hyperplasia or appendiceal neuroma (formerly known as chronic appendicitis obliterans)⁽¹⁾ are considered as physiologic changes and traditionally are of no clinical significance. The most common disease affecting the appendix is acute appendicitis, which usually requires surgical resection⁽²⁾. Tumors, benign and malignant, of the appendix are uncommon. Metastatic tumors of the appendix are much rarer⁽²⁻⁵⁾. To date approximately twenty cases of well-documented cases appendicular metastases of proven malignant tumors from different organs have been recorded in English medical literature (Table 1)⁽⁶⁻²⁵⁾. To the authors' knowledge, appendicular metastasis from a prostatic carcinoma has never been reported. In the present report, the authors presented a unique case of metastasis to

the appendix from a silent prostatic carcinoma with resultant acute appendicitis.

Case Report

In August 2005, a 62-year-old Thai man was referred from Hua Hin Hospital for proper management of questionable prostatic carcinoma. Two months earlier, he experienced acute right lower abdominal pain with classical symptoms and signs of acute appendicitis. According to the information from the referral request form, the excised appendix showed ill-defined, firm white induration involving the muscular wall and adjacent periappendiceal tissue grossly. Pathological diagnosis from Hua Hin Hospital was metastatic adenocarcinoma associated with acute appendicitis. Prostatic carcinoma was suspected to be the primary tumor site by morphology (no available slide or paraffin block for confirmation at that time). Physical examination revealed only diffuse stony hard prostate without definite mass. His serum PSA (prior to any manipulation) was 158 ng/ml (normal = 0-4 ng/ml). Transrectal ultrasound-guided (TRUS) core needle biopsy of the prostate, performed two days later, showed high-grade prostatic adenocarcinoma involving both sides of the gland with intraprostatic

Correspondence to:

Ratanarapee S, Department of Pathology, Faculty of Medicine, Siriraj Hospital, Mahidol University, Bangkok 10700, Thailand.
Phone: 0-2411-2005
E-mail: sisrt@mahidol.ac.th

Table 1. Cases of metastasis-induced acute appendicitis

Case	Author	Primary tumor	Clinical manifestation/appendicial status
1	Moller (1984)	Gastric cancer	Appendicitis
2	Ohnishi (1986)	Gallbladder carcinoma	Peritonitis
3	Gillesse (1987)	Cardia carcinoma	Appendicitis
4	Pang (1988)	Bronchogenic carcinoma	Appendicitis
5	Ciganak (1989)	Gastric carcinoma	Peritonitis
6	Maddox (1990)	Breast carcinoma	Appendicitis
7	Haid (1992)	Gastric carcinoma	Appendicitis
8	Hsu (1995)	Nasopharyngeal carcinoma	Appendicitis
9	Gopez (1997)	Bronchogenic carcinoma	Appendicitis
10	Rose (1997)	Ovarian carcinoma	Staging laparotomy
11	Wolf (1999)	Carcinoma of lung	Appendicitis
12	Sudirman (2001)	Carcinoma of cervix	Appendicitis
13	Filik (2003)	Pancreatic carcinoma	Noduly in the appendicular aifice
14	Goldstein (2004)	Small cell lung carcinoma	Acute appendicitis with perforation
15	Lin (2005)	Gastric carcinoma	Appendicitis
16	Miyazaki (2005)	Lung adenocarcinoma	Appendiceal mass
17	Miller (2006)	Endometrial adenocarcinoma	Appendiceal mass
18	Fu (2007)	Gastric cancer	Appendiceal mass
19	Pina-Oviedo (2007)	Gastric carcinoma	Neurogenous hyperplasia (appendiceal neuroma)
20	Kim (2008)	Hepatocellular carcinoma	Acute appendicitis

perineural invasion (Fig. 1). Subsequent review of the slide from Hua Hin Hospital confirmed metastatic adenocarcinoma to the appendix associated with acute appendicitis (Fig. 2). The neoplastic acini showed strong immunoreactivity for PSA, but negative reactivity for neuroendocrine cell (chromogranin A, synaptophysin, NSE, and S-100 protein), confirming prostatic origin of the tumor. Radionuclide bone scan (Tc-99m MDP) for metastatic foci was negative. Orchidectomy was performed two weeks after definite diagnosis. The

serum PSA gradually decreased to 0.1 ng/dl in January 2006. The patient was doing well with low serum PSA until August 2007 when gastric ulcer with recurrent massive hemorrhage developed and shortly followed by obstructive jaundice. Diffuse dilatation of the biliary system, including the distal common bile duct compatible with obstructive mass lesion at panereatic neck and multiple regional lymph node metastasis were shown in the CT scan. Subsequent renal failure was noted a month later. His latest serum

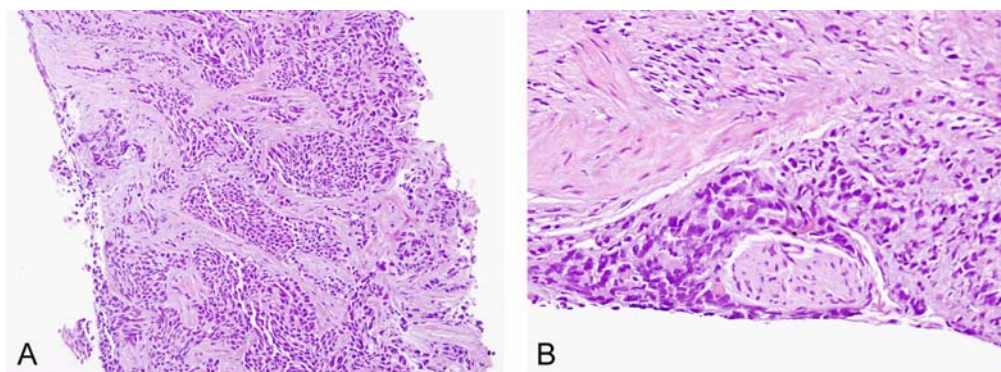


Fig. 1 A) Core needle biopsy of the prostate (S48-15588) showing Gleason pattern 5 adenocarcinoma (H&E, x40)
B) Perineural invasion (H&E, x600)

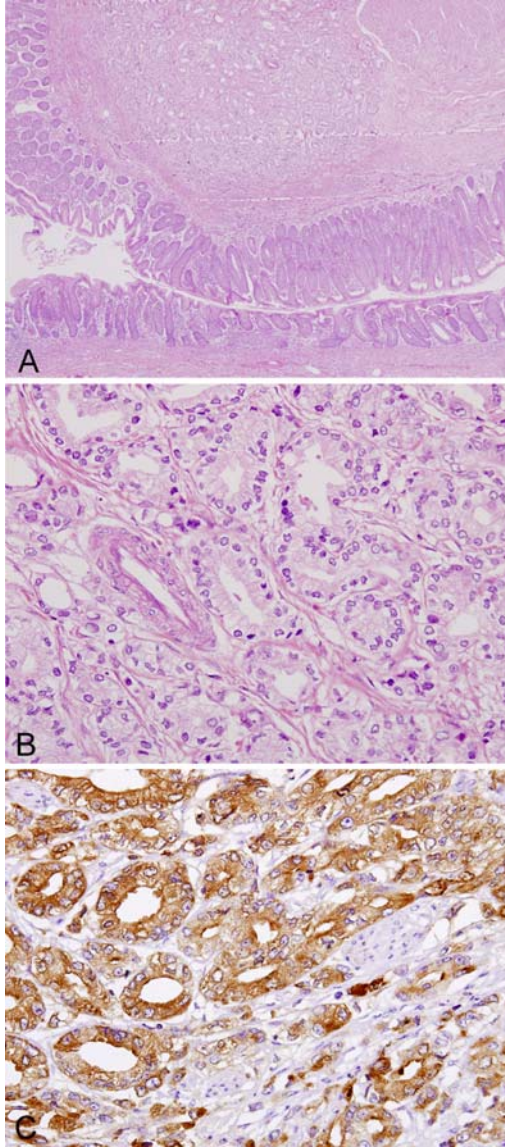


Fig. 2 A) Metastatic prostatic adenocarcinoma to the appendix (S48-19780). Malignant acini were confined in the submucosal and muscular layers. Note narrowing of appendiceal lumen but unremarkable mucosa (H&E, x100)
 B) Malignant acini at higher magnification (H&E, x400)
 C) Malignant acini with strong immunorecetivity for PSA (PSA immunostain, x600)

PSA (studied in late 2006) remained 0.062 ng/ml. He died of advanced carcinoma of the pancreato-biliary system in association with renal failure in September 2007.

Discussion

Many cases of acute appendicitis follow luminal obstruction. The increased intraluminal pressure can cause injury to the mucosa with resultant impaired resistance to microorganisms⁽²⁶⁾. The most common cause of obstruction is a fecalith, but any other conditions, such as tumors, can cause the same effect⁽²⁷⁻³¹⁾. A study of 172 appendectomies in Siriraj Hospital in 1979 showed that fecaliths at least could accelerate the progression of inflammation, leading to gangrenous change, and perforation⁽³²⁾. Cases with metastatic tumor caused acute appendicitis via this mechanism. The present case showed definite luminal narrowing caused by tumor nodule in the submucosa and muscular wall without mucosal change.

Tumors other than carcinoid tumors and adenocarcinomas when present in the appendix are easily recognized as metastatic, particularly when primary tumors in other organs are detected^(13,15,16,25). Adenocarcinomas with typical histologic features and specific tumor markers can also be easily detected by means of immunobistochemical study. The presented case is a good example. Typical prostatic pattern acini in H & E slide associated with strong immunoreactivity for PSA in immunohistochemical study prompted the diagnosis of metastatic prostatic adenocarcinoma. Negative immunoreactivity for chromogranin A, synaptophysin, NSE, and S-100 protein confirmed the absence of neuroendocrine cell. Other possible adenocarcinoma and primary carcinoid tumor with glandular pattern were all excluded.

Another helpful observation is the locations of metastatic tumors associated with apparently appendiceal normal mucosa (no dysplastic change). Tumor cells in the serosa, muscular wall, muscularis mucosae, and lymphatics are likely to be secondary^(5,9,11,14,33).

Patients with metastatic appendiceal tumors usually have poor prognosis^(5,34,35). However, if the appendix is the only organ involved associated with the nature of tumor, as in the presented case, prognosis might not be so poor. The presented patient did not die of prostatic carcinoma but he died with it but of another second advanced, aggressive tumor.

The common sites of metastases for prostatic carcinoma are pelvic lymph nodes, bone (with osteoblastic lesion), and lungs^(36,37). Liver, adrenal gland, large intestine, and central nervous system might occasionally be affected, particularly when estrogen is given⁽³⁶⁾. Multiple organ involvements are frequent in advanced cancers. The authors failed to

detect any other involved organ in this case. It was possible that the appendix was the single site of metastasis

Conclusion

The authors reported an extremely rare case of metastatic prostatic adenocarcinoma to the appendix causing clinical signs and symptoms of acute appendicitis. Confirmation of prostatic carcinoma was based on serum PSA level, TRUS prostatic core needle biopsy, and study of the previously removed appendix. Similar cases in the English literature were summarized. Careful examination of the gross specimen is helpful in detecting possible metastatic tumors in an inflamed appendix. To the authors' knowledge, this is the first case ever reported in English literature.

Acknowledgments

The authors wish to thank Dr. Napat Sukgasi, the first pathologist of the Institute of Pathology, Department of Medical Services, Ministry of Public Health, who reported the possible metastatic prostatic adenocarcinoma from Hua Hin Hospital, and subsequently transferred all materials to Siriraj Hospital, Mr. Vicha Sookpatdhee and Ms. Pornpiroon Lipimongkol, our staff, who prepared the photographs and manuscript.

References

1. Masson P. Carcinoids (Argentaffin-Cell Tumors) and Nerve Hyperplasia of the Appendicular Mucosa. *Am J Pathol* 1928; 4: 181-212.
2. Blair NP, Bugis SP, Turner LJ, MacLeod MM. Review of the pathologic diagnoses of 2,216 appendectomy specimens. *Am J Surg* 1993; 165: 618-20.
3. Collins DC. 71,000 human appendix specimens. A final report, summarizing forty years' study. *Am J Proctol* 1963; 14: 265-81.
4. Berge T, Lundberg S. Cancer in Malmo 1958-1969. An autopsy study. *Acta Pathol Microbiol Scand Suppl* 1977; (260): 1-235.
5. Dieter RA Jr. Carcinoma metastatic to the vermiform appendix: report of three cases. *Dis Colon Rectum* 1970; 13: 336-40.
6. Moller P, Lohmann M. Acute appendicitis as primary symptom of gastric cancer. *Ann Chir Gynaecol* 1984; 73: 241-2.
7. Ohnishi S, Hoh E, Kodama T, Moriyama T, Imawari M, Takaku F, et al. A case of gallbladder carcinoma metastatic to the appendix associated with acute peritonitis. *Nippon Shokakibyō Gakkai Zasshi* 1986; 83: 1540-3.
8. Gillesse EG, Mud HJ, Prins ME. An unusual cause of acute appendicitis. *Neth J Surg* 1987; 39: 153-4.
9. Pang LC. Metastasis-induced acute appendicitis in small cell bronchogenic carcinoma. *South Med J* 1988; 81: 1461-2.
10. Ciganak J, Florek E. Carcinoma metastasis into the vermiform appendix. *Rozhl Chir* 1989; 68: 511-3.
11. Maddox PR. Acute appendicitis secondary to metastatic carcinoma of the breast. *Br J Clin Pract* 1990; 44: 376-8.
12. Haid M, Larson R, Christ M. Metastasis from adenocarcinoma of the lung producing acute appendicitis. *South Med J* 1992; 85: 319-21.
13. Hsu KL, Wang KS, Chen L, Chou FF. Acute appendicitis secondary to metastatic nasopharyngeal carcinoma. *J Surg Oncol* 1995; 60: 131-2.
14. Gopez EV, Mourelatos Z, Rosato EF, Livolsi VA. Acute appendicitis secondary to metastatic bronchogenic adenocarcinoma. *Am Surg* 1997; 63: 778-80.
15. Rose PG, Abdul-Karim FW. Isolated appendiceal metastasis in early ovarian carcinoma. *J Surg Oncol* 1997; 64: 246-7.
16. Sudirman A, Sukumar N, Davaraj B. Appendicular metastasis from carcinoma cervix. *Med J Malaysia* 2001; 56: 100-1.
17. Wolf C, Friedl P, Obrist P, Ensinger C, Gritsch W. Metastasis to the appendix: sonographic appearance and review of the literature. *J Ultrasound Med* 1999; 18: 23-5.
18. Filik L, Ozdal-Kuran S, Cicek B, Zengin N, Ozyilkan O, Sahin B. Appendicular metastasis from pancreatic adenocarcinoma. *Int J Gastrointest Cancer* 2003; 34: 55-8.
19. Goldstein EB, Savel RH, Walter KL, Rankin LF, Satheesan R, Lehman HE, et al. Extensive stage small cell lung cancer presenting as an acute perforated appendix: case report and review of the literature. *Am Surg* 2004; 70: 706-9.
20. Lin CY, Huang JS, Jwo SC, Chen HY. Recurrent gastric adenocarcinoma presenting as acute appendicitis: a case report. *Int J Clin Pract Suppl* 2005; (147): 89-91.
21. Miyazaki K, Satoh H, Sekizawa K. Metastasis to appendix from lung adenocarcinoma. *Int J Gastrointest Cancer* 2005; 36: 59-60.
22. Miller JS, Ramalingam P, Wang BY, Lee JR. Appendiceal mass in a middle-aged woman.

- Endometrioid endometrial carcinoma metastatic to the appendix. Arch Pathol Lab Med 2006; 130: 407-8.
23. Fu K, Horimatsu T, Sano Y, Katagiri A, Kaji Y, Fujimori T. Metastasis to the appendix from gastric cancer detected incidentally on colonoscopy. Endoscopy 2007; 39(Suppl 1): E17.
 24. Pina-Oviedo S, Del Valle L, Leon-Bojorge B, Ortiz-Hidalgo C. 'Signet-ring' cell gastric adenocarcinoma metastatic to a neurogenous hyperplasia of the appendix. Histopathology 2007; 50: 663-5.
 25. Kim HC, Yang DM, Jin W, Kim GY, Choi SI. Metastasis to the appendix from a hepatocellular carcinoma manifesting as acute appendicitis: CT findings. Br J Radiol 2008; 81: e194-6.
 26. Wangenstein OH, Dennis C. Experimental proof of the obstructive origin of appendicitis in man. Ann Surg 1939; 110: 629-47.
 27. Bizer LS. Acute appendicitis is rarely the initial presentation of cecal cancer in the elderly patient. J Surg Oncol 1993; 54: 45-6.
 28. Clark LP. Calculi in the appendix. Br J Surg 1952; 40: 272-3.
 29. Forbes GB, Lloyd-Davies RW. Calculous disease of the vermiform appendix. Gut 1966; 7: 583-92.
 30. Peltokallio P. Acute appendicitis associated with carcinoma of the colon. Dis Colon Rectum 1966; 9: 453-6.
 31. Zarabi M, LaBach JP. Ganglioneuroma causing acute appendicitis. Hum Pathol 1982; 13: 1143-6.
 32. Ratanarapee S, Trisakwatana S, Manonukul J, Laohapan T, Chantarakul N. Appendicitis: a pathological study. Siriraj Hosp Gaz 1979; 31: 45-9.
 33. Zelikowski A, Urca I. Metastatic carcinoma of the appendix: report of a case. Dis Colon Rectum 1972; 15: 305-7.
 34. Goldfarb A, Zuckner J. Acute suppurative appendicitis with perforation resulting from metastatic carcinoma; report of a case. Surgery 1951; 29: 137-41.
 35. Bolker H, Shapiro AL. Appendiceal metastasis in carcinoma of the breast. NY State J Med 1940; 40:219-20.
 36. de la Monte SM, Moore GW, Hutchins GM. Metastatic behavior of prostate cancer. Cluster analysis of patterns with respect to estrogen treatment. Cancer 1986; 58: 985-93.
 37. Saitoh H, Hida M, Shimbo T, Nakamura K, Yamagata J, Satoh T. Metastatic patterns of prostatic cancer. Correlation between sites and number of organs involved. Cancer 1984; 54: 3078-84.

ไส้ติ่งอักเสบเฉียบพลัน เป็นอาการนำของมะเร็งต่อมลูกหมากที่แพร่กระจายมายังไส้ติ่ง: รายงานผู้ป่วย 1 ราย

สำเริง รัตนะระพี, ไชยรงค์ นวลยง

รายงานผู้ป่วยชายไทยอายุ 62 ปี ที่ถูกส่งตัวมารักษาต่อที่โรงพยาบาลศิริราชในเดือนสิงหาคม พ.ศ. 2548 สองเดือนก่อนผู้ป่วยได้รับการผ่าตัดไส้ติ่งจากโรงพยาบาลหัวหิน เนื่องจากอาการ และอาการแสดงของไส้ติ่งอักเสบเฉียบพลัน การตรวจทางพยาธิวิทยา พบว่ามีการแพร่กระจายของมะเร็งชนิด อติโนคารสิโนมา มาที่ผนังไส้ติ่งร่วมกับการอักเสบ มีการสันนิษฐานว่ามะเร็งที่แพร่มาน่าจะเป็นมะเร็งต่อมลูกหมากพบว่าลักษณะทางจุลทรรศน์ พีเอสเอในซีรัม และตรวจชิ้นเนื้อต่อมลูกหมากผ่านทางทวารหนัก รวมทั้งการศึกษาไส้ติ่งที่ตัดมาแล้วยืนยันได้ว่าผู้ป่วยเป็นมะเร็งต่อมลูกหมากจริง ผู้ป่วยได้รับการรักษาโดยการผ่าตัดลูกอัณฑะทั้งสองข้างออก ซึ่งได้ผลดี สองปีต่อมาผู้ป่วยเกิดโรคอื่นตามมาอีกสองโรค คือ แผลในกระเพาะอาหาร ซึ่งทำให้ผู้ป่วยอาเจียนเป็นเลือดหลายครั้ง และมะเร็งบริเวณตับอ่อน ซึ่งทำให้ผู้ป่วยตัวเหลือง ตาเหลืองแบบทางเดินน้ำดีอุดตัน ผู้ป่วยเสียชีวิตจากภาวะไตวาย ซึ่งเกิดขึ้นภายหลังจากการพบมะเร็งชนิดที่สอง ไม่พบการแพร่กระจายของมะเร็งต่อมลูกหมากเลย ตลอดเวลาสองปีก่อนที่ผู้ป่วยจะเสียชีวิต