

Case Report

Paradoxical Embolism in Bilateral Total Knee Arthroplasty: A Case Report

Suksan Tangsataphorn MD*,
Keerati Chareancholvanich MD*

* Department of Orthopaedic Surgery, Faculty of Medicine, Siriraj Hospital, Mahidol University, Bangkok, Thailand

Paradoxical embolism is defined as venous thrombosis causing systemic embolization through a right-to-left shunt.

We, herein, report a case of bilateral total knee arthroplasty and developed paradoxical embolism caused by patent foramen ovale. A sixty-two year old female had a simultaneous, total knee arthroplasty for primary osteo-arthritis. A pulmonary emboli was suspected on the thirteenth post operative day. Two days later, acute arterial insufficiency at her leg was suspected. An embolectomy and intra-operative transesophageal echocardiogram was performed. It showed patent foramen ovale (PFO) 2-3 mm. Five days after embolectomy, she developed infarction lesion at the right occipital area. The foramen ovale was closed with a closure device nineteen days later. The patient eventually could walk using a walker. She was discharged thirty-six days after the operation.

Keyword: *Paradoxical embolism, Bilateral total knee arthroplasty, Pulmonary embolism, Patent foramen ovale*

J Med Assoc Thai 2009; 92 (10): 1387-92

Full text. e-Journal: <http://www.mat.or.th/journal>

Total knee arthroplasty can provide reliable pain relief and consistent correction of limb alignment in patients with moderate or severe arthritis. Currently, more than 315,000 total knee replacements are performed annually in the United States in the Medicare population alone⁽¹⁾. Many of these patients have bilateral gonarthrosis requiring operative intervention. The choice of simultaneous or staged total knee arthroplasty for the operative treatment of bilateral knee arthritis remains controversial. The surgeon and patient are then faced with the decision of whether to proceed with a staged bilateral total knee replacement, done as two unilateral total knee arthroplasty procedures performed on different days, or a simultaneous bilateral total knee replacement. Several authors have reported an increased risk of cardiovascular and neurological complications in patients undergoing bilateral surgery⁽²⁾. On the other hand, several investigators believe that simultaneous

total knee arthroplasty is associated with a minimal or no increase in complications or risks⁽³⁻²⁰⁾.

Thromboembolic complications are the most frequent associated pathologies after knee replacement. The secondary deep vein thrombosis in the knee arthroplasty is often low symptomatic or asymptomatic and, sometimes, it could lead to fatal pulmonary embolism⁽²¹⁾. Deep vein thrombosis (DVT) and pulmonary embolism (PE) are considered uncommon in Asian populations and thrombo-prophylaxis is rarely indicated⁽²²⁾. The present article reviews a serious complication that rarely occurs after simultaneous bilateral total knee arthroplasty.

Case Report

A sixty-two-year-old female had a simultaneous total knee arthroplasty for primary osteoarthritis. Her medical history was positive for 1 year and hypertension was treated with micardis (40mg). Cardiopulmonary risk was evaluated by a cardiologist. Routine investigation was performed before operation. She was taught appropriate rehabilitative exercises before surgery.

Correspondence to: Tangsataphorn S, Department of Ortho-paedic Surgery, Faculty of Medicine, Siriraj Hospital, Mahidol University, Bangkok 10700, Thailand.

She then underwent bilateral total knee arthroplasties without intra-operative complications. She was treated with antifibrinolytic drug (tranxamine) 500 mg 3 hours after surgery. On the first post operative day, she was transfused with autologous blood for acute blood-loss anemia as her hemoglobin had decreased from a pre-operative value of 12.9 at 1 day before surgery to 10. She was started on early mobilization by physical therapy on second post operative day. On the third post operative day, she was transferred to the acute rehabilitation unit.

On the thirteenth post operative day, while the patient did physical therapy she developed syncope. The patient had drowsiness, dyspnea, shortness of breath and complained of pain at mid back. She was found to have rales on examination of her lungs. A pulmonary embolus was suspected. Blood gases showed oxygen saturation of 93% and wide A-a gradient. Supplemental oxygen therapy was initiated. Computerized tomography angiography (CTA) scan revealed multiple segmental embolism and bilateral deep vein thrombosis (Fig. 1). She was treated with heparin 3600 unit immediately and then drip via intravenous. She was transferred immediately to intensive care unit. Echocardiogram was performed and showed good function of right ventricle.

Second day at ICU, she complained of marked pain and numbness at her left leg. The left lower extremity was cold, and dorsalis pedis and posterior tibial arteries were not palpable. Acute arterial insufficiency was suspected, and an emergency arterial Doppler study was performed that revealed evidence of acute popliteal occlusion. CTA was performed again and revealed occlusion of left popliteal artery at its origin with reconstituted at bifurcation of tibioperoneal trunk and anterior tibial artery. The patient was taken to the operating room. An embolectomy and intra-operative tranesophageal echocardiogram was performed. It showed patent foramen ovale (PFO) 2-3 mm. After the operative, symptoms improved, with normalization of pulse and strength of the extremity.

On the fifth post operative embolectomy day, the patient complained of loss of her visual field. She presented with abnormal speech and alteration of conscious. A neurosurgeon was consulted to assist evaluating for a suitable investigation. The physical examination showed left homonymous hemianopia. Computerized tomography was performed and showed infarction lesion at right occipital area (Fig. 3). She was treated with continuous anticoagulant.

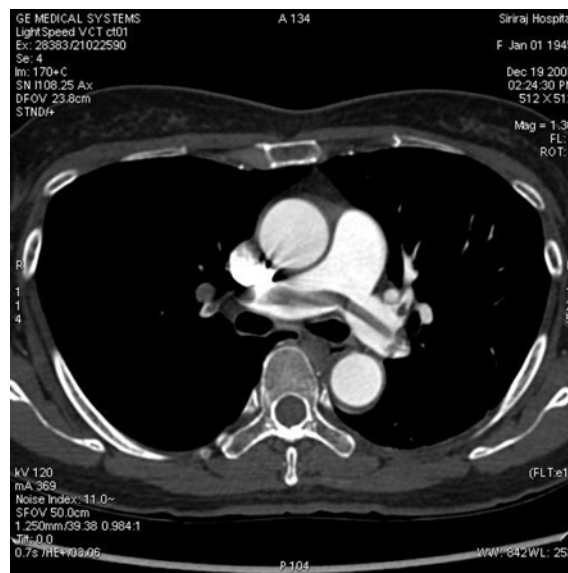


Fig. 1 Pulmonary computer tomographic angiography on postoperative day 13 demonstrating multiple segmental embolisms

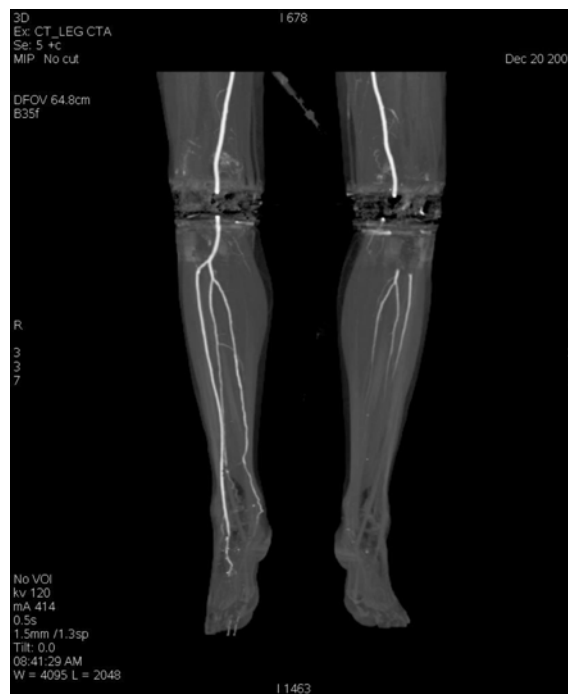

Fig. 2 Leg computer tomographic angiography demonstrating occlusion of left popliteal artery

The nineteenth post operative embolectomy day, foramen ovale was closed with device closure and temporary IVC filter was removed. The patient could

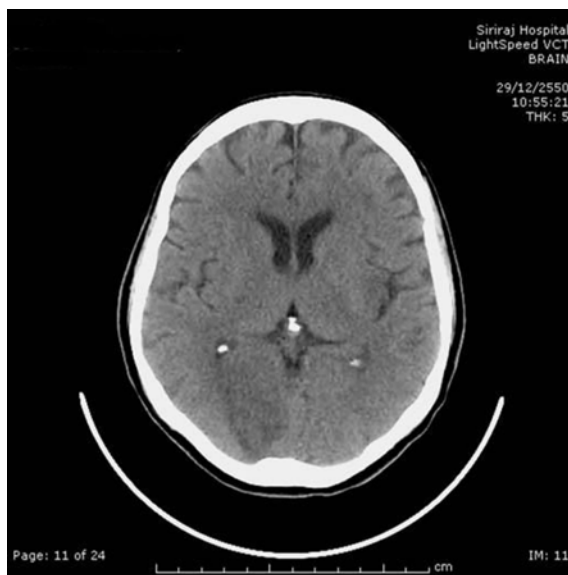


Fig. 3 Computer tomography of brain demonstrating infarction of right occipital area

walk using a walker on the second post operative day. The rest of the hospital stay was uneventful. She was discharged thirty-six days after the operation.

Discussion

Critics of simultaneous bilateral total knee replacement believe that the rate of perioperative complications is greater than that associated with staged bilateral arthroplasty⁽²³⁾. Several authors have shown that bilateral procedures result in an increased prevalence of fat emboli with resulting pulmonary and neurological effects⁽²⁴⁻²⁶⁾. However, proponents of simultaneous bilateral total knee arthroplasty have reported greater patient satisfaction, lower overall rehabilitation time, similar functional gains, and decreased costs for the patient and institution^(7,8,13,15,30,31,33).

Soudry et al, who evaluated 304 patients and reported a two-fold increased relative risk of deep venous thrombosis in the cohort treated with unilateral arthroplasty⁽¹⁸⁾. The overall pooled odds ratio was 0.99. The lowest odds ratio for deep venous thrombosis occurring after simultaneous bilateral total knee arthroplasty was 0.37 for a sample size of 769 patients and 1024 knees. Results suggest a trend toward a decreased prevalence of deep venous thrombosis in patients treated with bilateral total knee arthroplasty. One hypothesis for the decreased rate of deep venous thrombosis in association with the bilateral arthroplasties is that the larger intra-operative blood

loss and surgical insult may consume many of the patients' clotting factors, resulting in a less coagulable state. In contrast to the findings regarding deep venous thrombosis, the probability of a pulmonary embolism in patients who had undergone simultaneous bilateral total knee arthroplasty was higher than that in patients who had undergone a unilateral total knee arthroplasty⁽³⁰⁾.

Pulmonary embolism most commonly results from DVT occurring in the deep veins of the lower extremities, proximal to and including the popliteal veins. Both DVT and PE are frequently clinically unsuspected, leading to significant diagnostic and therapeutic delays and accounting for substantial morbidity and mortality. Innumerable clinical investigations have established that DVT cannot be reliably diagnosed on the basis of the history and physical examination, even in high-risk patients⁽³¹⁾.

Patent foramen ovale (PFO) is a common finding in healthy subjects; a pooled analysis of autopsy studies showed an average prevalence of PFO of 26%⁽³²⁾. Thompson and Evans in a postmortem study identified a "pencil patent" patent foramen ovale (PFO) (0.6-1 cm) in 6% of individuals and a "probe patent" PFO (0.2-0.6 cm) in 29% of individuals⁽³³⁾. Now reports did not find exact evidence of PFO in knee surgery patients.

PFO can cause hypoxemia and embolic phenomena when right atrial (RA) pressure exceeds the left atrial (LA) pressure⁽³⁴⁻³⁶⁾. A PFO induces an increase in right-to-left shunt in case of an elevated intrapulmonary pressure. Pulmonary embolism (PE) has been described as the most common cause of short-term elevation of right atrial pressure (RAP) and right-to-left shunt in patients with PFO and occurs in at least 60% cases of paradoxical embolism^(37,38).

Paradoxical embolism, which is defined as venous thrombosis causing systemic embolization through a right-to-left shunt, is a rare cause of peripheral arterial emboli and acute limb ischemia^(37,38). Paradoxical embolism of thrombus, fat, and air through a PFO is a well-recognized complication⁽³⁹⁾. Paradoxical emboli have been suggested as the main mechanism of stroke in patients with a PFO. In patients who present with arterial emboli and are found to have PFO, the diagnosis of paradoxical embolism is favored in the presence of venous thrombosis and further supported by a pressure gradient that favors right-to-left shunting⁽⁴⁰⁾.

Chaikof, E L et al, reviewed hospital records for all patients diagnosed with both a documented PFO

and a thromboembolic event between January 1970 and June 1993. They found that the presumptive diagnosis of paradoxical embolism was made in seven patients. There were five men and two women, with a median age of 43 years. Four patients were admitted with an acute cerebral ischemic event, and in three others hospitalization was prompted by the development of an acutely ischemic limb (two upper extremities; one lower extremity). Symptoms suggestive of pulmonary emboli were noted in two patients, and in only one patient was there evidence on physical examination of a deep venous thrombosis⁽⁴¹⁾.

The recent development of percutaneous methods of PFO closure provides a valuable backup for those cases when PFO is not closed and post-operative hypoxemia or other complications may be attributable to the uncorrected PFO⁽⁴²⁾. Percutaneous transcatheter closure of PFO/ASD is a safe and effective therapeutic option for the secondary prevention of presumed paradoxical embolism. It is associated with a high success rate, low incidence of hospital complications, and very low frequency of recurrent systemic embolic events⁽⁴³⁾.

Surgeons vary considerably regarding the use of prophylactic development of deep venous thrombosis after total knee arthroplasty particular in low risk patients. Simultaneous bilateral TKA is a relatively safe and beneficial procedure with a minimal increase in the risk of systemic complications⁽⁴⁴⁾. The presented patient did not receive DVT prophylaxis before surgery because of low risk: 1. not obese, 2. young age, 3. no prior venous thrombosis, 4. no cardiogenic or hematologic disorder. However, it is apparent that she developed DVT which resulted in symptomatic pulmonary embolism.

The administration of tranexamic acid is associated with a decrease in the number of red blood cell (RBC) units transfused. However, concerns about its safety have hindered its broader use. Rozano et al concluded that tranexamic acid treatment was not associated with an increase in thromboembolic complications⁽⁴⁵⁾. It is also clear that the thrombus was not associated with a using antifibrinolytic agent.

The authors have demonstrated the paradoxical embolism in the presented patient. Arterial embolism and the presence of multiple DVT, a PFO with right-to-left shunt, sudden onset of symptoms, and Doppler study was suggestive of embolus and strongly supported this diagnosis. The presence of risk factors for DVT and PE in such a knee arthroplasty surgery patients should prompt the evaluation for a

PFO. Future studies should include PFO as a potential factor for the development of acute arterial occlusion in arthroplasty surgery.

References

1. Weinstein J, Birkmeyer J. The Dartmouth atlas of musculoskeletal health care. Chicago, IL: American Hospital Association; 2000: 60.
2. Lynch NM, Trousdale RT, Ilstrup DM. Complications after concomitant bilateral total knee arthroplasty in elderly patients. *Mayo Clin Proc* 1997; 72: 799-805.
3. Benjamin J, Tucker T, Ballesteros P. Is obesity a contraindication to bilateral total knee arthroplasties under one anesthetic? *Clin Orthop Relat Res* 2001; (392): 190-5.
4. Brotherton SL, Roberson JR, de Andrade JR, Fleming LL. Staged versus simultaneous bilateral total knee replacement. *J Arthroplasty* 1986; 1: 221-8.
5. Cohen RG, Forrest CJ, Benjamin JB. Safety and efficacy of bilateral total knee arthroplasty. *J Arthroplasty* 1997; 12: 497-502.
6. Dennis DA. Debate: bilateral simultaneous total knee arthroplasty. *Clin Orthop Relat Res* 2004; (428): 82-3.
7. Gradillas EL, Volz RG. Bilateral total knee replacement under one anesthetic. *Clin Orthop Relat Res* 1979; (140): 153-8.
8. Hardaker WT Jr, Ogden WS, Musgrave RE, Goldner JL. Simultaneous and staged bilateral total knee arthroplasty. *J Bone Joint Surg Am* 1978; 60: 247-50.
9. Jankiewicz JJ, Sculco TP, Ranawat CS, Behr C, Tarantino S. One-stage versus 2-stage bilateral total knee arthroplasty. *Clin Orthop Relat Res* 1994; (199): 94-101.
10. Kolettis GT, Wixson RL, Peruzzi WT, Blake MJ, Wardell S, Stulberg SD. Safety of 1-stage bilateral total knee arthroplasty. *Clin Orthop Relat Res* 1994; (309): 102-9.
11. McLaughlin TP, Fisher RL. Bilateral total knee arthroplasties. Comparison of simultaneous (two-team), sequential, and staged knee replacements. *Clin Orthop Relat Res* 1985; (199): 220-5.
12. Morrey BF, Adams RA, Ilstrup DM, Bryan RS. Complications and mortality associated with bilateral or unilateral total knee arthroplasty. *J Bone Joint Surg Am* 1987; 69: 484-8.
13. Ritter MA, Meding JB. Bilateral simultaneous total knee arthroplasty. *J Arthroplasty* 1987; 2: 185-9.

14. Ritter MA. Simultaneous knee replacement is better for the patient. *Orthopedics* 1998; 21: 415, 418.
15. Ritter MA. Bilateral simultaneous TKR: doing what's best for the patient. *Orthopedics* 2000; 23: 538.
16. Ritter MA, Harty LD, Davis KE, Meding JB, Berend M. Simultaneous bilateral, staged bilateral, and unilateral total knee arthroplasty. A survival analysis. *J Bone Joint Surg Am* 2003; 85-A: 1532-7.
17. Ritter MA, Harty LD. Debate: simultaneous bilateral knee replacements: the outcomes justify its use. *Clin Orthop Relat Res* 2004; (428): 84-6.
18. Soudry M, Binazzi R, Insall JN, Nordstrom TJ, Pellicci PM, Goulet JA. Successive bilateral total knee replacement. *J Bone Joint Surg Am* 1985; 67: 573-6.
19. Stanley D, Stockley I, Getty CJ. Simultaneous or staged bilateral total knee replacements in rheumatoid arthritis. A prospective study. *J Bone Joint Surg Br* 1990; 72: 772-4.
20. Vince KG. Bilateral total knee arthroplasty under one anesthesia: a safe protocol. *Mayo Clin Proc* 1997; 72: 883-5.
21. Prejbeanu R, Vermesan H, Dragulescu SI, Vermesan D, Motoc A, Sabatini R, et al. Thromboembolic risk after knee endoprosthesis. *Eur Rev Med Pharmacol Sci* 2007; 11: 297-300.
22. Pookarnjanamorakot C, Sirisriro R, Eurvilaichit C, Jaovisidha S, Koysoibatolan I. The incidence of deep vein thrombosis and pulmonary embolism after total knee arthroplasty: the screening study by radionuclide venography. *J Med Assoc Thai* 2004; 87: 869-76.
23. Rosenberg AG. True indications for bilateral simultaneous TKR are rare. *Orthopedics* 2000; 23: 540.
24. Dorr LD, Merkel C, Mellman MF, Klein I. Fat emboli in bilateral total knee arthroplasty. Predictive factors for neurologic manifestations. *Clin Orthop Relat Res* 1989; (248): 112-8.
25. Ries MD, Rauscher LA, Hoskins S, Lott D, Richman JA, Lynch F Jr. Intramedullary pressure and pulmonary function during total knee arthroplasty. *Clin Orthop Relat Res* 1998; (356): 154-60.
26. Lachiewicz PF, Ranawat CS. Fat embolism syndrome following bilateral total knee replacement with total condylar prosthesis: report of two cases. *Clin Orthop Relat Res* 1981; (160): 106-8.
27. Borden LS, Perry JE, Davis BL, Owings TM, Grabiner MD. A biomechanical evaluation of one-stage vs two-stage bilateral knee arthroplasty patients. *Gait Posture* 1999; 9: 24-30.
28. Minter JE, Dorr LD. Indications for bilateral total knee replacement. *Contemp Orthop* 1995; 31: 108-11.
29. Reuben JD, Meyers SJ, Cox DD, Elliott M, Watson M, Shim SD. Cost comparison between bilateral simultaneous, staged, and unilateral total joint arthroplasty. *J Arthroplasty* 1998; 13: 172-9.
30. Bullock DP, Sporer SM, Shirreffs TG Jr. Comparison of simultaneous bilateral with unilateral total knee arthroplasty in terms of perioperative complications. *J Bone Joint Surg Am* 2003; 85-A: 1981-6.
31. Wheeler HB. Diagnosis of deep vein thrombosis. Review of clinical evaluation and impedance plethysmography. *Am J Surg* 1985; 150(4A): 7-13.
32. Hagen PT, Scholz DG, Edwards WD. Incidence and size of patent foramen ovale during the first 10 decades of life: an autopsy study of 965 normal hearts. *Mayo Clin Proc* 1984; 59(10): 17-20.
33. Thompson T, Evans W. Paradoxical embolism. *Q J Med* 1930; 23: 135-50.
34. Strunk BL, Cheitlin MD, Stulbarg MS, Schiller NB. Right-to-left interatrial shunting through a patent foramen ovale despite normal intracardiac pressures. *Am J Cardiol* 1987; 60: 413-5.
35. Nazzal SB, Bansal RC, Fitzmorris SJ, Schmidt CA. Platypnea-orthodeoxia as a cause of unexplained hypoxemia in an 82-yr-old female. *Cathet Cardiovasc Diagn* 1990; 19: 242-5.
36. Smeenk FW, Postmus PE. Interatrial right-to-left shunting developing after pulmonary resection in the absence of elevated right-sided heart pressures. Review of the literature. *Chest* 1993; 103: 528-31.
37. AbuRahma AF, Downham L. The role of paradoxical arterial emboli of the extremities. *Am J Surg* 1996; 172: 214-7.
38. Ward R, Jones D, Haponik EF. Paradoxical embolism. An underrecognized problem. *Chest* 1995; 108: 549-58.
39. Pell AC, Hughes D, Keating J, Christie J, Busuttill A, Sutherland GR. Brief report: fulminating fat embolism syndrome caused by paradoxical embolism through a patent foramen ovale. *N Engl J Med* 1993; 329: 926-9.
40. Ahmed S, Sadiq A, Siddiqui AK, Borgen E, Mattana J. Paradoxical arterial emboli causing acute limb ischemia in a patient with essential thrombocytosis. *Am J Med Sci* 2003; 326: 156-8.
41. Chaikof EL, Campbell BE, Smith RB III. Paradoxical

- embolism and acute arterial occlusion: rare or unsuspected? J Vasc Surg 1994; 20: 377-84.
42. Dubiel M, Bruch L, Liebner M, Schmehl I, Winkelmann A, Rux S, et al. Exclusion of patients with arteriosclerosis reduces long-term recurrence rate of presumed arterial embolism after PFO closure. J Interv Cardiol 2007; 20: 275-81.
43. Bailey CE, Allaqaband S, Bajwa TK. Current management of patients with patent foramen ovale and cryptogenic stroke: our experience and review of the literature. WMJ 2004; 103: 32-6.
44. Yoon HS, Han CD, Yang IH. Comparison of simultaneous bilateral and staged bilateral total knee arthroplasty in terms of perioperative complications. J Arthroplasty 2009 Feb 3 [Epub ahead of print].
45. Munoz M, Garcia-Erce JA, Cuenca J. Tranexamic acid for reducing transfusion requirements after total knee arthroplasty: can efficacy and cost ratios be improved? Vox Sang 2008; 95: 350-1.

การเกิด paradoxical embolism ในผู้ป่วยหลังผ่าตัดเปลี่ยนข้อเข่าเทียมพร้อมกันสองข้าง

สุขสันต์ ตั้งสถาพร, กิรติ เจริญชลวานิช

Paradoxical embolism คือ ภาวะที่เกิดมีลิ่มเลือดอุดตันบางส่วนหลุดไปจากระบบหลอดเลือดดำ และเข้าไปอุดตันในหลอดเลือดแดงในตำแหน่งต่าง ๆ โดยผ่านช่องทางต่อระหว่างห้องหัวใจด้านขวาและด้านซ้าย (patent foramen ovale = PFO) จะสงสัยการเกิดภาวะดังกล่าวในผู้ป่วยที่พบว่ามีอาการเกิดก้อนลิ่มเลือดแข็งตัวในระบบหลอดเลือดดำ และในขณะเดียวกันที่มีแรงดันของเลือดในห้องหัวใจจากห้องด้านขวาดันเลือดไปสู่ห้องด้านซ้าย เนื่องจากภาวะแทรกซ้อนที่พบได้บ่อยที่สุดในการผ่าตัดเปลี่ยนข้อเข่าเทียมคือ การเกิดก้อนลิ่มเลือดในระบบหลอดเลือดดำ ซึ่งผู้ป่วยที่ทำการรายงานนี้ได้รับการผ่าตัดเปลี่ยนข้อเข่าเทียม หลังผ่าตัดพบว่าผู้ป่วยมีลักษณะดังกล่าวของภาวะ paradoxical embolism

ผู้ป่วยรายนี้เป็นหญิง อายุ 62 ปี ได้รับการผ่าตัดเปลี่ยนข้อเข่าเทียมสองข้างในเวลาต่อเนื่องกัน หลังผ่าตัด 13 วัน ตรวจพบว่ามี deep vein thrombosis ต่อมาตรวจพบว่ามี pulmonary embolism ในวันที่ 13 หลัง จากผ่าตัด อีกสองวันต่อมาพบว่า ผู้ป่วยมีการอุดตันของลิ่มเลือดเข้าไปในระบบหลอดเลือดแดง เริ่มจากตำแหน่งแรกที่หลอดเลือดแดงหลังเข่า และอีก 5 วันต่อมาพบก้อนเลือดอุดตันที่หลอดเลือดสมองทำให้สมองบางส่วนขาดเลือด หลังจากได้ทำการผ่าตัดรักษาภาวะก้อนเลือดอุดตันในหลอดเลือดหลังเข่าแล้วผู้ป่วยได้รับการตรวจ ด้วยเครื่อง esophageal ultrasound พบว่าผู้ป่วยมีภาวะ patent foramen ovale จึงสามารถอธิบายได้ว่าลิ่มเลือดที่อุดตันในหลอดเลือดดำไหลผ่าน PFO เข้าสู่ระบบหลอดเลือดแดง และไปอุดตันหลอดเลือดแดงขนาดเล็กในที่ต่าง ๆ ได้

ในที่สุดผู้ป่วยรายนี้ได้รับการรักษาโดยการผ่าตัดปิดรูของ PFO และผู้ป่วยสามารถเดินได้ด้วย walker และกลับบ้านได้หลังจากผ่าตัดไป 36 วัน