

Case Report

Laparoscopic Extravesical Ureteral Reimplantation for Iatrogenic Distal Ureteral Stricture

Sompol Permpongkosol MD, PhD*, Anthony J Bella MD**,
Ussapol Tantarawongsa MNS*, Marshall L Stoller MD***

* Division of Urology, Department of Surgery, Faculty of Medicine, Ramathibodi Hospital,
Mahidol University, Bangkok, Thailand

** Division of Urology, Department of Surgery, University of Ottawa, Ontario, Canada

*** Department of Urology, University of California-San Francisco, San Francisco, California, USA

Objective: The authors describe their experience with laparoscopic extravesical neoureterocystostomy for iatrogenic distal ureteral stricture using a transperitoneal intracorporeal freehand suturing technique.

Material and Method: Three patients with distal ureteral strictures underwent laparoscopic transperitoneal extravesical ureteral reimplantation. A 77 year old male underwent a Lich-Gregoir antireflux ureteral reimplantation following complications arising from transurethral resection of the prostate, and two females, aged 28 and 34 years, underwent refluxing ureteral reimplantation with concurrent psoas hitch after gynecologic surgery. The authors reviewed patient records to assess peri- and postoperative outcomes following definitive laparoscopic management of stricture segments.

Results: All procedures were completed entirely using a laparoscopic approach. No intra- or post-operative complications were reported. Operative times ranged between 180-250 minutes and mean blood loss was 50-150 ml. The mean time to restarting oral intake was 12 hours. Pathological evaluation confirmed benign lesions in each case and follow-up imaging confirmed satisfactory functional results.

Conclusion: Laparoscopic extravesical neoureterocystostomy for iatrogenic distal ureteral strictures is a safe and efficacious procedure. Larger cohorts and longer-term results are required before this technique is considered first-line therapy in this patient group.

Keywords: Laparoscopy, Ureter

J Med Assoc Thai 2009; 92 (10): 1380-6

Full text. e-Journal: <http://www.mat.or.th/journal>

Minimally invasive laparoscopic uretero-neocystostomy was first performed by Ehrlich et al in 1994 and Janetschek et al in 1995, using the refluxing technique and the Lich-Gregoir antireflux procedure, respectively^(1,2). Reports of such procedures are few in peer-reviewed literature, as laparoscopic uretero-neocystostomy has been limited by technical challenges when performing complicated surgical maneuvers⁽³⁾. However, refinement and/or development of novel laparoscopic instrumentation, coupled with improved

techniques for laparoscopic suturing (ex. freehand intracorporeal suturing), have allowed for the reproduction of the same steps used in open surgery for ureteric strictures⁽⁴⁾. Even with such advances, laparoscopic extravesical ureteral reimplantation for iatrogenic distal ureteral strictures in adults remains rarely reported and consists primarily of case reports (Table 1). Interestingly, no perioperative complication was reported in these procedures to date. The authors herein described their approach to laparoscopic extravesical transperitoneal ureteral reimplantation by refluxing technique or the Lich-Gregoir antireflux procedure for iatrogenic distal ureteral strictures using transperitoneal intracorporeal freehand suturing techniques.

Correspondence to: Permpongkosol S, Division of Urology, Department of Surgery, Faculty of Medicine, Ramathibodi Hospital, Mahidol University, Rama 6 road, Bangkok 10400, Thailand. Phone: 0-2201-1315, Fax: 0-2201-1315, E-mail: permpongkosol@gmail.com

Material and Method

Institutional Review Board approvals from Mahidol University (MU) and the University of California San Francisco (UCSF), as well as informed patient consent, were obtained to permit assessment of data. Two females and one male, ages 28, 34, and 77 respectively, with a clinical diagnosis of an iatrogenic distal stricture were treated laparoscopically by extravesical transperitoneal ureteral reimplantation. Pathological evaluation of distal ureter confirmed benign disease. Exclusion criteria included surgery conducted for vesicoureteral reflux, immediate repair of ureteral injury, malignant ureteral tumors, and Boari-flap procedures. Patient demographics, intra-operative findings, pathologic data, and clinical/radiological outcomes were analyzed.

Case 1

A 77-year-old male with significant comorbidity presented with intermittent mild left flank pain (MU). Patient history included hypertension, diabetic mellitus, and ischemic heart disease. He had undergone a transurethral resection of the prostate (TURP) 2 years earlier. An intravenous urogram (IVU) confirmed left-sided hydronephrosis and kinking of the hydroureter, which was traced to ureteric orifice (Fig. 1A). Cystourethroscopy was performed and left ureteric orifice could not be identified due to severe scarring secondary to the TURP.

After reviewing treatment options with the patient, laparoscopic extravesical ureteroneocystostomy using the Lich-Gregoir antireflux procedure was performed (see Surgical Technique). Operative time was 180 minutes and estimated blood loss was 150 ml. No peri- or post-operative complications were reported. Oral intake was initiated at 12 hours and pain was scored at 3 on a visual 10-point scale. No post-operative narcotic analgesia was used. The abdominal drain was removed after 48 hours, followed by the ureteric stent at 2 weeks. An IVU at four months showed an unobstructed ureterovesical anastomosis (Fig. 1B) and cystogram did not show any evidence of reflux. One-year follow-up ultrasound revealed good emptying of the left lower ureter (Fig. 1C).

Case 2

A 34-year-old female was referred (UCSF) for management of a right iatrogenic ureteral stricture three years post-thermal injury from laparoscopic treatment for chronic endometriosis and pelvic pain. Endourologic treatments included balloon dilation and

prolonged stenting. The stricture did not resolve, culminating in urinary leakage from the right ureter. The IVU demonstrated right-sided hydronephrosis and an obstructed lower third of the ureter (Fig. 2A).

A right laparoscopic refluxing ureteroneocystostomy with psoas hitch was performed. The operative time was 250 minutes with an estimated blood loss of less than 50 mL. Postoperatively, the patient's hospital course was complicated by pain, which required a Fentanyl patient-controlled anesthesia. On postoperative day 3, her Jackson-Pratt drain was removed and she was discharged with oral medications. The Foley catheter and double-J ureteric stent were removed 3 and 6 weeks after the operative day, respectively. Two-month follow-up ultrasonography revealed mild residual pelvicaliceal dilatation on the right kidney. However, the patient continued to complain of severe pain and was referred to the Anesthesia Pain Service for consultation.

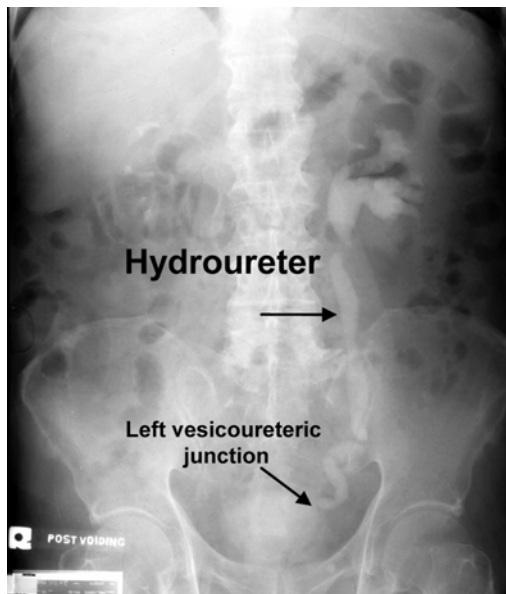
Case 3

A 28-year-old female with a history of hysterectomy and gynecologic surgery two years previously for high-grade cervical dysplasia presented with acute right-sided colic. A contrast-enhanced computed tomography scan (CT) showed right-sided hydronephrosis and hydroureter. She had failed right double J-stent management, requiring right percutaneous nephrostomy tube drainage. An antegrade nephrostogram revealed a ureterovesical junction stricture without evidence of stone, mass or extrinsic compression (Fig. 2B).

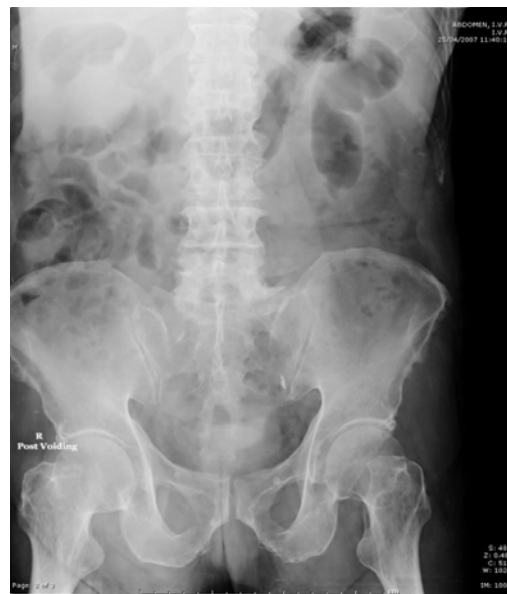The patient underwent right laparoscopic refluxing ureteroneocystostomy with psoas hitch at UCSF. The operative time was 240 minutes with blood loss of 100 mL. The patient was discharged on day 3, following an uneventful postoperative course. The Jackson-Pratt drain, Foley catheter, and the double-J stent were removed on day 3, day 7 and 4 weeks after surgery, respectively. A contrast enhanced CT at 2 months demonstrated mild residual hydronephrosis and good excretion of contrast medium from the right kidney and ureter.

Surgical technique

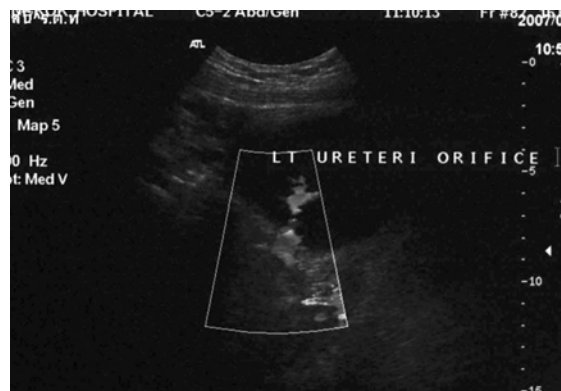The patients were given a preoperative dose of intravenous antibiotic. Under general anesthesia, the patients were prepared and draped. Orogastric tubes and Foley catheters were inserted to decompress the stomach and bladder. All patients were placed in the low lithotomy position.



A. Post-voiding IVU



B. Post-voiding IVU after corrective surgery



C. One year follow-up ultrasound Postoperative ultrasonography

Fig. 1 Case 1 (A) Preoperative post-voiding IVU shows hydroureter (B) Postoperative post-voiding IVU reveals unobstructed ureterovesical anatomy (C) Postoperative ultrasonography demonstrates good flow of urine at left ureteric orifice

Case 1

A small incision was made in the inferior umbilical fold. Using the Hasson technique, a 12-mm port was placed and a pneumoperitoneum created. A pure laparoscopic approach using two 12 mm ports and two 5 mm ports was performed. A 12 mm port and a 5 mm port were placed in a left and right lateral position (respectively to the rectus muscle) between the umbilicus and anterior superior iliac spine. The fourth port (5 mm) was placed in left rectus muscle at the level of the umbilicus.

The left ureter was identified above the level of the iliac vessels and was gently mobilized circumferentially down to the bladder. It was divided proximally in relation to the strictured area after ligation of the distal end. The distal strictured ureter was sent for histopathology review. The proximal ureter was spatulated and the bladder was filled with 200 mL of normal saline. The overlying anterior and left lateral peritoneum was incised to drop the bladder posteriorly. After the urachus was divided, the bladder was freed anterior to the retropublic space with sharp

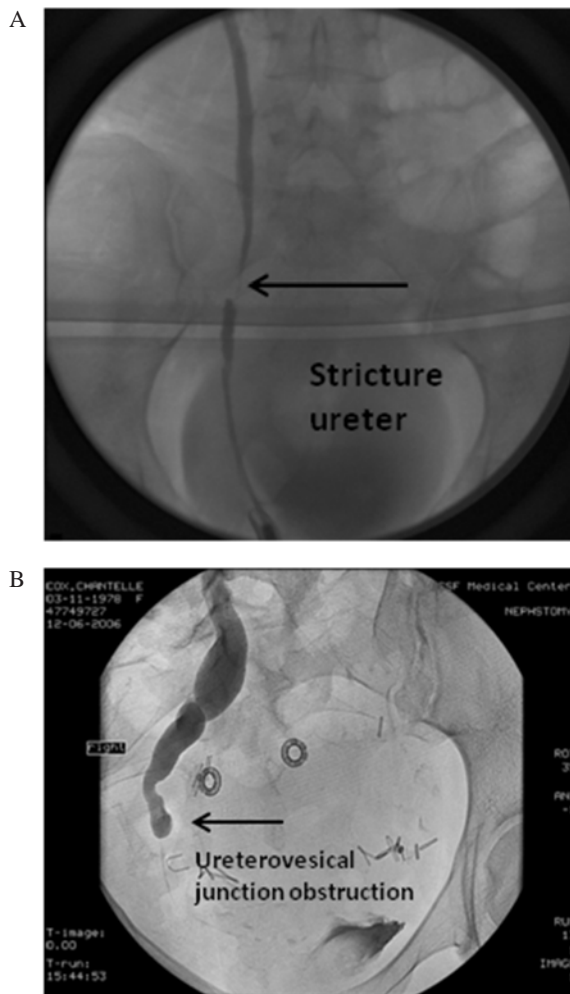


Fig. 2 (A) Preoperative IVU for Case 2 demonstrated right-sided hydronephrosis and an obstructed lower third of the ureter. and (B) Preoperative antegrade nephrostogram showed complete stricture in Case 3

dissection. The optimal location of the detrusor tunnel was carefully determined with the bladder distended, and the site was marked with electrocautery along the anterior lateral bladder wall. The serosal and muscular layers of bladder were opened, and the Lich-Gregoir reimplant technique was followed. An intravesical tunnel length to ureteral diameter ratio of at least 5:1 was maintained. The intact urothelium bulged out, allowing the correct plane to be located with ease. An anastomosis between the ureteral end and the neoureteral opening was performed with six interrupted mucosa-to-mucosa 4-0 Vicryl sutures. Before the last few stitches were placed, a number 8 feeding tube was

placed to the distal ureter. The detrusor muscle and serosa of the bladder were closed with four interrupted sutured of 3-0 Vicryl suture to make the submucosal tunnel. The drain was placed paravesically, and brought out through the 5 mm trocar site. The orogastric tube was removed at the end of the procedure.

Cases 2 and 3

After pneumoperitoneum creation with a Veress needle, an 11-mm camera port was placed in the umbilicus and a 30-degree telescope was inserted into the camera port. Under direct visualization, an 11-mm port was placed at the left lateral border of the rectus muscle and 3 cm caudal to the umbilicus. A 5-mm port was then placed midway between the umbilicus and the right anterior superior iliac spine, and a second 5 mm port was placed in the midline between the suprapubic bone and the umbilicus.

The colon was reflected medially by incising the line of Toldt. The ureter was identified above the level of the iliac vessels, and freed as distally as possible, taking care to preserve the periureteral tissue to avoid ureteral devascularization. A vessel loop was placed around the ureter. The bladder was distended with 250 mL of sterile saline via the Silastic urethral catheter. The psoas hitch was performed with three 2-0 Maxon absorbable sutures after the space of Retzius was identified and the bladder mobilized by freeing its peritoneal attachments. The ureter was then transected and spatulated.

A cystostomy was made with the guidance of a rigid cystoscope. A ureteral stitch was placed into the corresponding location of the bladder at the 6 o'clock position. The medial ureteroneocystotomy anastomosis was completed with interrupted 4-0 Vicryl sutures mounted on V-20 needles. Once the opening was closed to 0.5 cm, a cystoscope was introduced into the bladder via urethra. A guide wire was then placed up into the kidney, through the anastomosis. A 26 cm x 6 F double J-stent was placed over the wire with the proximal and distal curls placed in the appropriate location. Finally, the ureteral neocystotomy was closed with three additional sutures. Tisseal was then applied to reinforce the suture line. A drain and Foley catheter were placed, with the previously placed percutaneous nephrostomy tube removed.

Discussion

Laparoscopic surgery is now an integral part of urologic practice, with an ever-expanding role defined primarily by advances in reconstructive

Table 1. A review of published reports for laparoscopic extravesical ureteral reimplantation for iatrogenic distal ureteral strictures#

References	Age, sex (No. of patients)	Iatrogenic etiology	Transperitoneal approach with a psoas hitch (+)	Operative duration, min	EBL, mL	Complications
Yohannes et al, 2001 ⁽¹²⁾	33F	Laser lithotripsy	Refluxing (-)	233	<50	None
Modi et al 2005 ⁽¹³⁾	38.8*F ⁽⁶⁾	Ureterovaginal fistula/ GyneSx	Antirefluxing (+)	227*	90*	None
Kamat & Khandel, 2005 ⁽³⁾	40F	Gyne Sx	Refluxing (-)	240	<50	None
	30F	NA	Antirefluxing (+)	230	<50	None
Branco 2005 ⁽¹⁴⁾	48F	Gyne Sx (Lap)	Antirefluxing (-)	150	100	None
Rassweiler et al, 2007 ⁽⁷⁾	35F	Rectum Sx	Refluxing (+)	165	250	None
	38M	LPND	Antirefluxing (+)	243	550	None
	78F	TUR bladder	Antirefluxing (+)	197	350	None
Simmons et al, 2007 ⁽⁸⁾	NR ⁽⁴⁾	NA	Refluxing (NA)	NR	NR	None
Present study	77M	TURP	Antirefluxing (-)	240	<50	None
	34F	Gyne Sx (Lap)	Refluxing (+)	NR	<50	None
	28F	Gyne Sx	Refluxing (+)	NR	<50	None

Note: NR = not reported, NA = not available, EBL = estimated blood loss, TURP= transurethral resection of the prostate, Gyne = Gynecologic, Sx = surgery, LPND = laparoscopic retroperitoneal lymph node dissection, * = mean

Cases performed for vesicoureteral reflux, immediate repair of ureteral injury, malignant ureteral tumors and Boari-flap procedures were excluded

techniques⁽⁵⁾. Indications for ureteral reconstruction include iatrogenic injury, trauma, and malignancies⁽⁶⁾. Recently, Chung et al reported their experience with laparoscopic ureteroneocystostomy for obstruction secondary to injury of the distal ureter⁽⁴⁾. The authors report their experience for pure laparoscopic extravesical ureteroneocystostomy at MU and UCSF.

Previously reported series for laparoscopic extravesical ureteral reimplantation are presented in Table 1. Rassweiler et al⁽⁷⁾ and Simmons et al⁽⁸⁾ have presented retrospective comparisons of patients who underwent open and laparoscopic ureteroureterostomy, Boari flap, and ureteroneocystostomy. Although both groups suggest that laparoscopic surgery may become the 'procedure of choice' for reconstruction of obstructive ureteral pathologies in adults, there were several significant limitations to these studies including small patient cohorts (10 and 12 patients, respectively), uneven distribution of procedures (open > laparoscopic), and a lack of key clinical details that would allow for extrapolation of these results⁽⁸⁾.

All cases in the present series involved a delayed presentation resulting in chronic ureteral obstruction refractory to conservative treatment (stenting or balloon dilatation). Technically, laparoscopic extravesical ureteroneocystostomy was

completed in all patients and in contrast to Baldwin et al, the intraperitoneal pressure was neither greater than the bladder pressure nor did it result in suboptimal exposure and a difficult dissection of the detrusor from the underlying urothelium⁽⁹⁾. Filling of the bladder in an attempt to produce mucosal bulging allowed for protrusion into the working space, improving visibility and allowing the correct plane to be located more easily.

The present technique for the first case mimics that used for open Lich-Gregoir repair and is feasible using laparoscopy. Although antirefluxing procedures for ureteral reimplantation in adults are less important than for children, no differences in the risk of stenosis with antireflux versus reflux procedures has been noted⁽¹⁰⁾. Nevertheless, if the peri- and post-operative risks to the patient with antirefluxing and refluxing procedures using laparoscopic techniques are equivalent, the former is preferred as the absence of vesicoureteral reflux may create less postoperative morbidity⁽⁴⁾. In the present review, laparoscopic extravesical refluxing ureteroneocystostomy with or without psoas hitch had an operative time and complications comparable to the antirefluxing technique (consistent with data presented in Table 1).

For the final two cases, refluxing ureteroneocystostomy with psoas hitch was the preferred

intervention, consistent with traditionally accepted practice for tension-free, distal ureteral repair. The psoas hitch was performed before the ureterovesical anastomosis, as the authors do not agree with Kamat and Khandewal's concern that performing the laparoscopic ureterovesical anastomosis subsequently is technically more challenging⁽³⁾. Moreover, these authors do not find cystoscopy to select the site of the neomeatus necessary; the authors believe that the benefit of cystoscopy is for placement and monitoring of the neocystomy site at the dome of the bladder⁽¹⁰⁾. Interestingly, recently robot-assisted laparoscopic distal ureterectomy and ureteral reimplantation with psoas hitch was reported by Uberoi et al, but endoscopic incision of ureteral orifice was required in all patients with a history of transitional-cell carcinoma⁽¹¹⁾.

Conclusion

Transperitoneal laparoscopic extravesical ureteroneocystostomy is a safe and feasible surgical approach for iatrogenic distal ureteral stricture. Further studies are necessary to refine the technical nuances and evaluate long-term outcomes.

References

1. Janetschek G, Radmayr C, Bartsch G. Laparoscopic ureteral anti-reflux plasty reimplantation. First clinical experience. *Ann Urol (Paris)* 1995; 29: 101-5.
2. Ehrlich RM, Gershman A, Fuchs G. Laparoscopic vesicoureteroplasty in children: initial case reports. *Urology* 1994; 43: 255-61.
3. Kamat N, Khandewal P. Laparoscopic extravesical ureteral reimplantation in adults using intracorporeal freehand suturing: report of two cases. *J Endourol* 2005; 19: 486-90.
4. Chung H, Jeong BC, Kim HH. Laparoscopic ureteroneocystostomy with vesicopsoas hitch: nonrefluxing ureteral reimplantation using cystoscopy-assisted submucosal tunneling. *J Endourol* 2006; 20: 632-8.
5. Modi P, Goel R, Dodia S, Devra A. Case report: laparoscopic Boari flap. *J Endourol* 2006; 20: 642-5.
6. Castillo OA, Litvak JP, Kerkebe M, Olivares R, Urena RD. Early experience with the laparoscopic boari flap at a single institution. *J Urol* 2005; 173: 862-5.
7. Rassweiler JJ, Gozen AS, Erdogru T, Sugiono M, Teber D. Ureteral reimplantation for management of ureteral strictures: a retrospective comparison of laparoscopic and open techniques. *Eur Urol* 2007; 51: 512-22.
8. Simmons MN, Gill IS, Fergany AF, Kaouk JH, Desai MM. Laparoscopic ureteral reconstruction for benign stricture disease. *Urology* 2007; 69: 280-4.
9. Baldwin DD, Pope JC, Alberts GL, Herrell SD, Dunbar JA, Roberts RL, et al. Simplified technique for laparoscopic extravesical ureteral reimplantation in the porcine model. *J Endourol* 2005; 19: 502-7.
10. Stefanovic KB, Bukurov NS, Marinkovic JM. Non-antireflux versus antireflux ureteroneocystostomy in adults. *Br J Urol* 1991; 67: 263-6.
11. Uberoi J, Harnisch B, Sethi AS, Babayan RK, Wang DS. Robot-assisted laparoscopic distal ureterectomy and ureteral reimplantation with psoas hitch. *J Endourol* 2007; 21: 368-73.
12. Yohannes P, Gershbaum D, Rotariu PE, Smith AD, Lee BR. Management of ureteral stricture disease during laparoscopic ureteroneocystostomy. *J Endourol* 2001; 15: 839-43.
13. Modi P, Goel R, Dodiya S. Laparoscopic ureteroneocystostomy for distal ureteral injuries. *Urology* 2005; 66: 751-3.
14. Branco AW, Branco Filho AJ, Kondo W. Laparoscopic ureteral reimplantation in ureteral stenosis after gynecologic laparoscopic surgery. *Int Braz J Urol* 2005; 31: 51-3.

การผ่าตัดฝังหลอดไตเข้าใหม่กับผนังของกระเพาะปัสสาวะโดยวิธีการส่องกล้อง

สมพล เพิ่มพงศ์โกศล, แอนโทนี แบลลา, อัสน พล ตันตะราวศา, มาแซล สเตเลอร์

วัตถุประสงค์: เพื่อรายงานประสบการณ์การผ่าตัดด้วยการส่องกล้องฝังหลอดไตนอกกระเพาะปัสสาวะ (laparoscopic extravesical neoureterocystostomy) ในกรณีท่อไตส่วนปลายตีบแคบ โดยใช้เทคนิคการผ่าตัด transperitoneal intracorporeal freehand suturing technique

วัสดุและวิธีการ: ผู้ป่วยสามคนที่มีหลอดไตส่วนปลายตีบแคบได้รับการผ่าตัดด้วยการส่องกล้องฝังท่อไตนอกกระเพาะปัสสาวะ ผู้ป่วยชายอายุ 77 ปี ได้รับการผ่าตัดที่เรียกว่า Lich-Gregoir antireflux ureteral reimplantation เกิดโรคแทรกซ้อนหลังจากผ่าตัดเอาต่อมลูกหมากออก (transurethral resection of the prostate) ผู้ป่วยหญิงอายุ 28 ปีและ 34 ปีได้รับการผ่าตัด refluxing ureteral reimplantation และ psoas hitch หลังการผ่าตัดทางนรีเวช ผู้นิพนธ์ได้ศึกษาผู้ป่วยย้อนหลังถึงผลระหว่างการผ่าตัดและติดตามหลังการผ่าตัด

ผลการศึกษา: การผ่าตัดทั้งหมดจากการใช้กล้องผ่าตัดประสบความสำเร็จด้วยดีไม่พบว่ามีโรคแทรกซ้อนระหว่างการผ่าตัด หรือ หลังการผ่าตัด เวลาในการผ่าตัดอยู่ระหว่าง 180-250 นาที และค่าเฉลี่ยของการสูญเสียเลือด 50-150 มิลลิลิตร ค่าเฉลี่ยของการเริ่มรับประทานอาหารเท่ากับ 12 ชั่วโมง ผลพยาธิวิทยาของหลอดไตส่วนปลายของที่ตีบในแต่และคนไม่พบว่ามีลักษณะมะเร็ง และภาพเอกซเรย์ติดตามหลังการรักษาได้ผลเป็นที่น่าพอใจ

สรุป: การผ่าตัดด้วยการส่องกล้อง laparoscopic extravesical neoureterocystostomy เพื่อรักษา ในกรณีหลอดไตส่วนปลายตีบแคบจากแพทย์ทำเป็นวิธีที่ปลอดภัยและมีประสิทธิภาพ การศึกษาในผู้ป่วยจำนวนมากขึ้นและการติดตามผลระยะยาวเป็นสิ่งจำเป็น
