

Case Report

Delayed Encephalopathy and Cognitive Sequelae after Acute Carbon Monoxide Poisoning: Report of a Case and Review of the Literature

Toungnat Tapeantong MD*,
Niphon Pongvarin MD, FRCP, FRCP(E)*

* Division of Neurology, Department of Medicine, Faculty of Medicine Siriraj Hospital,
Mahidol University, Bangkok, Thailand

Serious delayed encephalopathy and cognitive sequelae following acute carbon monoxide intoxication constitutes a rare and a distinct entity. A case of delayed encephalopathy and cognitive sequelae after acute carbon monoxide poisoning is presented. The patient is a 50-year-old Thai female with a history of carbon monoxide poisoning during her vacation tour in Arizona in winter. She developed encephalopathy 4 weeks after recovery from the acute stage. Her MRI-brain found abnormal white matter change of cerebral hemispheres bilaterally and abnormal signal intensity at both putamens and caudate nuclei. She regained some improvement in her memory and other cognitive function after 4 weeks of treatment including hyperbaric oxygen therapy (HBOT).

Keywords: Carbon monoxide poisoning, Delayed encephalopathy, Cognitive sequelae

J Med Assoc Thai 2009; 92 (10): 1374-9

Full text. e-Journal: <http://www.mat.or.th/journal>

Carbon monoxide (CO) is a colorless, odorless, toxic gas that is a product of incomplete combustion. Motor vehicles, heaters, appliances that use carbon based fuels, and household fires are the main sources of this toxic substance. In the human body, CO attaches to the hemoglobin and blocks the capacity to carry oxygen. CO binds reversibly to hemoglobin with an affinity 200-240 times that of oxygen. It has been suggested that carboxyhemoglobin causes severe generalized tissue hypoxia and a direct toxic effect on the mitochondria⁽¹⁾. CO is now realized as one of the gaseous neurotransmitter similar to nitric oxide.

Delayed postanoxic encephalopathy causes deterioration and relapse of cognitive ability and behavioural movement a few weeks after complete recovery from initial hypoxic injury⁽²⁾. In Thailand, there is no case report of delayed post anoxic encephalopathy after CO poisoning. The patient was diagnosed and demonstrated extensive white matter lesions in the brain parenchyma including deep grey matter nuclei

Correspondence to: Pongvarin N, Division of Neurology, Department of Medicine, Faculty of Medicine Siriraj Hospital, Mahidol University, Bangkok 10700, Thailand.

on diffusion weighted magnetic resonance imaging. Literature review of this condition was extensively searched.

Case Report

A 50-year-old Thai female was admitted at Siriraj Hospital Medical School, Mahidol University, Bangkok. She had a definite history of severe CO poisoning from the malfunctioned heat generator in the United States (US) on 3rd January 2008. Her family included her daughter and husband were also intoxicated with a milder degree and documented high carboxyhemoglobin levels. She appeared to be the one most affected.

The patient and her husband went to the US on 3rd January 2008 to celebrate their daughter's bachelor graduation. They spent their vacation with a touring agency to Arizona. At the small local hotel, where the patient and her family stayed, a central heat generator in her room was malfunctioning, thus the hotel manager took a mobile heat generator for substitution. On the next morning there was no response to the wake up call, thus at 9.00 a room

service man broke into the room. The patient, her daughter and her husband were found all in a comatose stage. Along the side of the patient, vomitus was found but no medication was noticed. They were then taken immediately to the local hospital. After intubation and ventilation, she could then move all four extremities spontaneously but she was still in a semicomatose state. Both her husband and daughter were also intoxicated and were transferred by helicopter for hyperbaric oxygenation therapy (HBOT) in New Mexico City. The patient was admitted to the medical intensive care unit, where she was found to have a serum CO level to 17.2%. The patient subsequently underwent several sessions of HBOT. At Presbyterian Hospital, arterial blood gases showed pH of 7.33, PCO₂ of 43 mmHg, PO₂ of 42 mmHg, backup of 22 mmHg, and an Aa gradient of 504, which was markedly elevated. EKG upon admission showed normal sinus rhythm with T-wave abnormality; however, no evidence of ischemia was detected including the patient's troponin blood levels and on further EKG testing.

With treatment per HBOT, the patient did well. O₂ saturation returned to normal value. She was subsequently extubated approximately 2 days after admission. She did well after extubation; however she continued to desaturate for a few more days only on exertion. She showed apparently resolved neurological symptoms and discharge from the hospital 3 days later.

She flew back to Thailand on 22nd January 2008 after her full recovery. She herself felt normal and was able to return to work. Two weeks after she returned to Thailand, she went to her office in the morning. In the evening she was found in her car which was parked at the side of the highway. Car

windows were closed, but there was no evidence of a car accident. The patient was alert but did not utter any word, could not follow any commands and had urinary incontinence. She was finally sent to Siriraj Hospital in the status of apathy, global aphasia, incontinence and disorientation. She was admitted to the medical intensive care unit. On examination she was alert but could not talk and was disoriented and did not obey or understand any commands. She had spasticity of both upper extremities with hyperreflexia. No gross motor weakness was detected. She had abnormal movement in choreiform character. Other examinations were unremarkable. Her laboratory investigations revealed normal complete blood count and metabolic profiles. Her chest radiogram and EKG were normal. Her Thai mental state exam (TMSE) score was 18/30 (impaired orientation, calculation, and language). Her MRI-brain showed abnormal white matter changes over both cerebral hemispheres and abnormal signal intensity at both putamens and caudate nuclei (Fig. 1).

Her electroencephalogram revealed generalized intermittent slow activity throughout both hemispheres. She was diagnosed as delayed neuropsychological and cognitive sequelae of CO poisoning. HBOT was the treatment of choice for her and she was given a total of 3 treatments. Follow-up brain single photon emission computed tomography (brain-SPECT) study was performed at about three weeks after admission showed multiple areas of decreased cerebral perfusion (Fig. 2). The cognitive impairment improved greatly a few weeks after discharge (admission for 8 weeks). Her TMSE score was 28/30 significantly improved (impaired calculation 2 points). Similarly, the follow-up brain MRI showed a steady improvement (Fig. 3, 4).

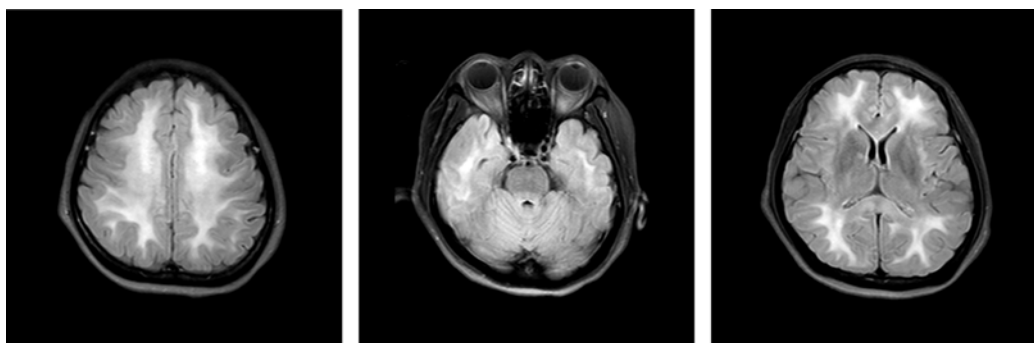


Fig. 1 MR images obtained on day 30th after carbon monoxide exposure. T2-weighted images show bilateral, symmetrical, confluent areas of high signal intensity in both centrum semiovale and periventricular white matter

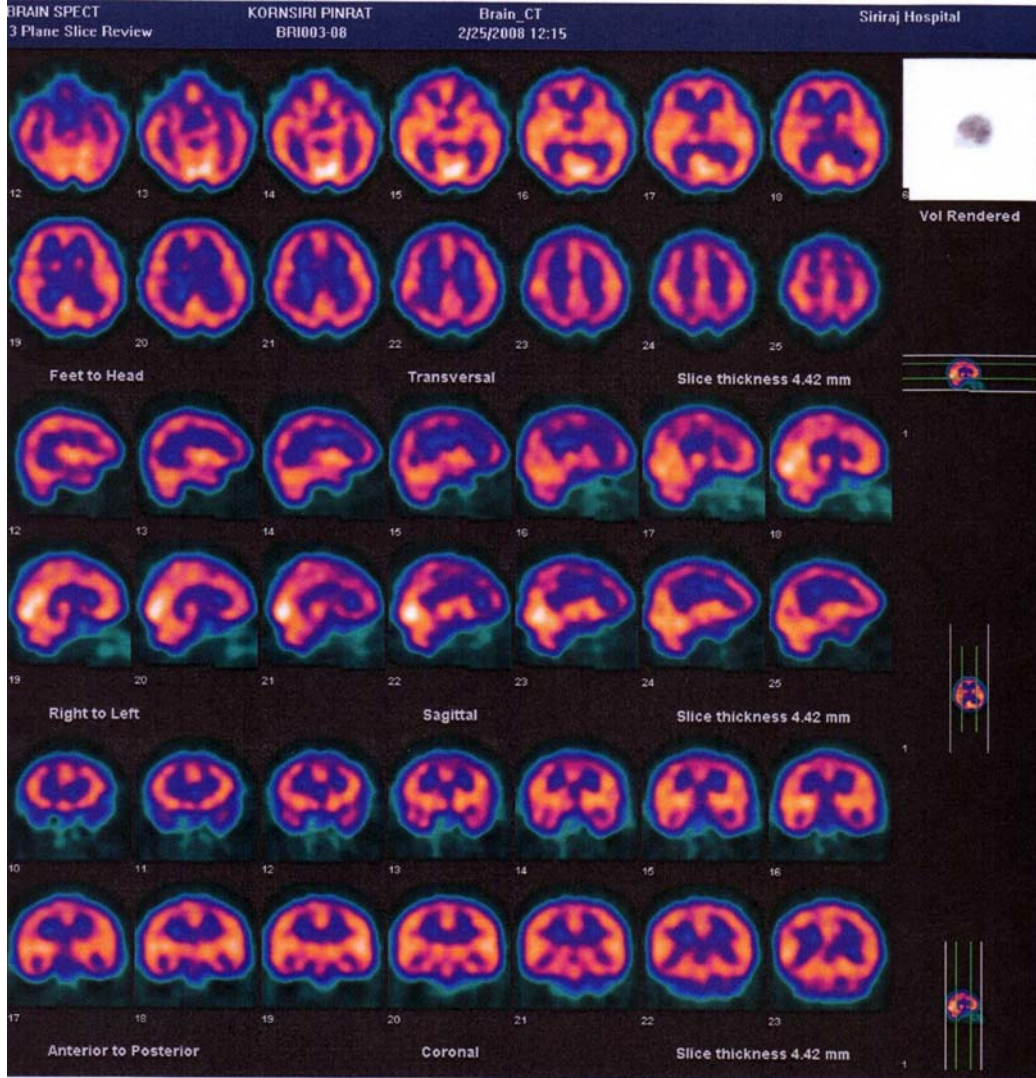


Fig. 2 Brain SPECT (Tc-99 ECD) showed multiple areas of decreased cerebral perfusion

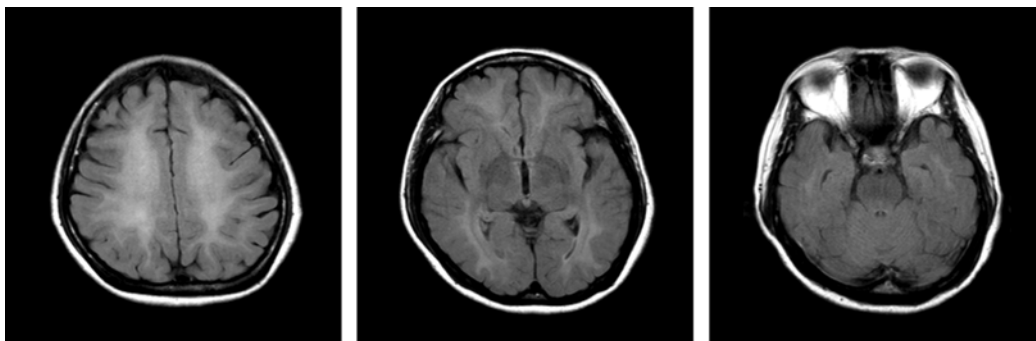


Fig. 3 MR images obtained on 2 months after carbon monoxide exposure. T2-weighted images show decreased areas of high signal intensity in both centrum semiovale and periventricular white matter

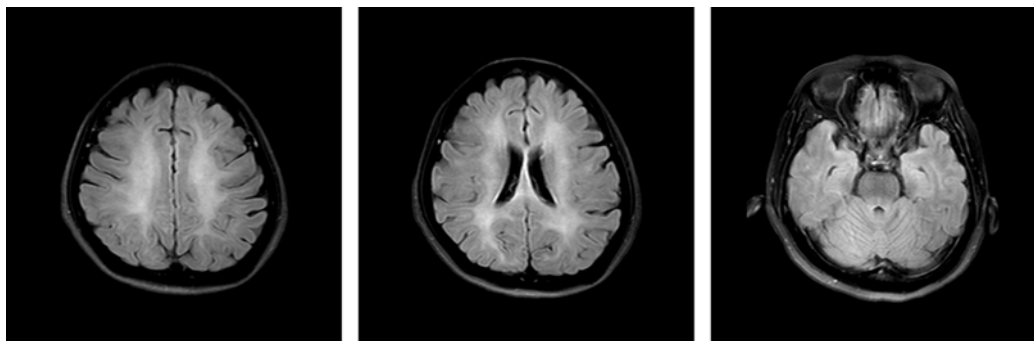


Fig. 4 MR images obtained on 9 months after carbon monoxide exposure. T2-weighted images show significantly improvement of white matter lesion in both centrum semiovale and periventricular

Discussion

Most patients with CO poisoning, whether incidental or accidental, initially visit the Emergency Department. Prompt recognition and proper management of this condition is essential. Most of them recover well without any complication with hyperbaric or high oxygen therapy. Delayed encephalopathy occurring from 14 to 45 days after recovery from the acute stage is well recognized. Clinical manifestations included cognitive impairment, akinetic mutism, sphincter incontinence, gait ataxia and extra-pyramidal syndromes such as chorea, dystonia, and parkinsonism⁽²⁾. It is estimated that as high as 50% of individuals with CO poisoning will develop neurologic, neurobehavioral, or cognitive sequelae. CO related cognitive impairments included impaired memory, attention, executive function, motor, visual spatial, and slow mental processing speed⁽³⁾. The delayed neuropsychiatric impairment showed that 2.75% of patients suffered from this complication with a mean lucid period of about 3 weeks⁽⁴⁾.

Brain MRI revealed multiple lesions in the subcortical white matter and basal ganglia, mostly in the globus pallidus, and to a lesser degree in the putamen, and caudate⁽⁵⁻⁷⁾. On apparent diffusion co-efficient (ADC) in patients with delayed encephalopathy of CO intoxication appeared to be within the normal range on day 23rd after CO exposure, but they progressively decreased until day 38th after exposure, then slowly increased. There have been reports which suggest delayed encephalopathy of CO intoxication, the restricted diffusion of the white matter lesion develops late after the patient exposure to CO and persists longer than usual 2-3 weeks after an acute ischemic infarction (Table 1)⁽⁸⁾.

It has been the retrospective study assess regional cerebral blood flow in patients after CO intoxication by using brain-SPECT and statistical parametric mapping, significantly decreased regional cerebral blood flow was noted extensively in the bilateral frontal lobes as well as the bilateral insula and a part of the right temporal lobe in the patients with delayed neuropsychiatric sequelae compared with normal volunteers ($p < 0.005$)⁽⁹⁾.

The recovery from delayed encephalopathy after CO poisoning occurs in 50%-75% within one year⁽⁴⁾. Similarly, the follow-up brain MRI showed a steady improvement⁽³⁾. It seems that no specific treatment is required for delayed encephalopathy after CO poisoning. It has been reported in a small randomised trial that the HBOT for acute CO poisoning could decrease the incidence of delayed neuropsychiatric sequelae⁽¹⁰⁾.

The timely administration of HBOT prevents neuronal injury, delayed neuropsychological sequelae and terminates the biochemical deterioration⁽¹¹⁻¹³⁾. Diffusion tensor MR imaging can be a quantitative method for the assessment of the white matter change and monitor the treatment response in patients of delayed encephalopathy after CO poisoning with a good clinical correlation⁽¹⁴⁾. The HBOT may be an effective therapy for delayed encephalopathy after CO poisoning⁽¹⁴⁾. Some studies showed that the repetitive HBOT may prevent the delayed neuropsychiatric sequelae of CO poisoning when applied individually with monitoring of the peak alpha frequency as an indicator of efficacy⁽¹⁵⁾.

Clinical status or carboxyhaemoglobin level on initial CO poisoning could not predict the occurrence of delay encephalopathy after CO poisoning. The most

Table 1. Summary of clinical features in five patients with delayed encephalopathy of CO intoxication

Patient/age (yr)/sex*	Initial manifestations of acute CO intoxication	Lucid interval (wk)	Major clinical findings of delayed encephalopathy
1/54/F	Coma with multiple burn injury	3	Short-term memory loss, confabulation; much improved at 7-mo follow-up
2/71/M	Sudden decrease of verbal output, free voiding	1	Aphasia, gait disturbance; much improved at 5-mo follow-up
3/63/M	Abnormal repetitive behavior, progressive abulia	3	Abulia, akinetic mutism; much improved at 8-mo follow-up
4/65/F	Coma, decrease of verbal output and cognitive dysfunction	4	Urinary/fecal incontinence, short-stepped gait; persistent clinical symptoms at 6-mo follow-up
5/63/F	Coma, free voiding, and defecation	4	Abulia, bradykinesia, free voiding; much improved at 5-mo follow-up

* In all patients except patient 4, the cause of their exposure to CO gas was a gas leakage from an under-the-floor home heating system. Patient 4 was exposed to exhaust gas from a car

common computed tomography (CT) finding in several cases of CO was low density in the cerebral white matter followed by lesions of the globus pallidi⁽¹⁶⁾. Some investigators reported that there was significant correlation between the cerebral white matter changes in the initial CT scan and the development of delayed neurological sequelae after acute CO poisoning⁽¹⁷⁾. Bilateral symmetric white matter hyperintensity in MRI (T2WI/FLAIR) could be a good predictor of delayed encephalopathy after acute CO intoxication⁽¹⁸⁾. Most CO poisoning patients present to the Emergency Department. Early detection and treatment can improve the outcome of delayed encephalopathy sequelae of patients with CO poisoning.

Conclusion

In conclusion, the authors presented a Thai woman with delayed hypoxic encephalopathy after CO intoxication, which presented with many clinical manifestations. In addition, to the best of our knowledge, this case is the first case in Thailand of neuropsychological and cognitive sequelae described after CO intoxication. In the evaluation of clinical condition associated with any brain lesion, the related pathways should be considered in addition to the functions of the independent region.

Reference

1. Gorman D, Drewry A, Huang YL, Sames C. The clinical toxicology of carbon monoxide. *Toxicology* 2003; 187: 25-38.
2. Hsiao CL, Kuo HC, Huang CC. Delayed encephalopathy after carbon monoxide intoxication - long-term prognosis and correlation of clinical manifestations and neuroimages. *Acta Neurol Taiwan* 2004; 13: 64-70.
3. Hopkins RO, Woon FL. Neuroimaging, cognitive, and neurobehavioral outcomes following carbon monoxide poisoning. *Behav Cogn Neurosci Rev* 2006; 5: 141-55
4. Choi IS. Delayed neurologic sequelae in carbon monoxide intoxication. *Arch Neurol* 1983; 40: 433-5.
5. Chang KH, Han MH, Kim HS, Wie BA, Han MC. Delayed encephalopathy after acute carbon monoxide intoxication: MR imaging features and distribution of cerebral white matter lesions. *Radiology* 1992; 184: 117-22.
6. Kim HY, Kim BJ, Moon SY, Kwon JC, Shon YM, Na DG, et al. Serial diffusion-weighted MR Imaging in delayed postanoxic encephalopathy. A case study. *J Neuroradiol* 2002; 29: 211-5.
7. Horowitz AL, Kaplan R, Sarpel G. Carbon monoxide toxicity: MR imaging in the brain.

- Radiology 1987; 162: 787-8.
8. Kim JH, Chang KH, Song IC, Kim KH, Kwon BJ, Kim HC, et al. Delayed encephalopathy of acute carbon monoxide intoxication: diffusivity of cerebral white matter lesions. *Am J Neuroradiol* 2003; 24: 1592-7.
 9. Watanabe N, Nohara S, Matsuda H, Sumiya H, Noguchi K, Shimizu M, et al. Statistical parametric mapping in brain single photon computed emission tomography after carbon monoxide intoxication. *Nucl Med Commun* 2002; 23: 355-66.
 10. Weaver LK, Hopkins RO, Chan KJ, Churchill S, Elliott CG, Clemmer TP, et al. Hyperbaric oxygen for acute carbon monoxide poisoning. *N Engl J Med* 2002; 347: 1057-67.
 11. Hart IK, Kennedy PG, Adams JH, Cunningham NE. Neurological manifestation of carbon monoxide poisoning. *Postgrad Med J* 1988; 64: 213-6.
 12. Harper A, Croft-Baker J. Carbon monoxide poisoning: undetected by both patients and their doctors. *Age Ageing* 2004; 33: 105-9.
 13. Ernst A, Zibrak JD. Carbon monoxide poisoning. *N Engl J Med* 1998; 339: 1603-8.
 14. Lo CP, Chen SY, Chou MC, Wang CY, Lee KW, Hsueh CJ, et al. Diffusion-tensor MR imaging for evaluation of the efficacy of hyperbaric oxygen therapy in patients with delayed neuropsychiatric syndrome caused by carbon monoxide inhalation. *Eur J Neurol* 2007; 14: 777-82.
 15. Murata M, Suzuki M, Hasegawa Y, Nohara S, Kurachi M. Improvement of occipital alpha activity by repetitive hyperbaric oxygen therapy in patients with carbon monoxide poisoning: a possible indicator for treatment efficacy. *J Neurol Sci* 2005; 235: 69-74.
 16. Miura T, Mitomo M, Kawai R, Harada K. CT of the brain in acute carbon monoxide intoxication: characteristic features and prognosis. *Am J Neuroradiol* 1985; 6: 739-42.
 17. Choi IS, Kim SK, Choi YC, Lee SS, Lee MS. Evaluation of outcome after acute carbon monoxide poisoning by brain CT. *J Korean Med Sci* 1993; 8: 78-83.
 18. Otubo S, Shirakawa Y, Aibiki M, Nishiyama T, Maekawa S, Kikuchi K, et al. Magnetic resonance imaging could predict delayed encephalopathy after acute carbon monoxide intoxication. *Chudoku Kenkyu* 2007; 20: 253-61.

Delayed encephalopathy และการสูญเสียประชนจากพิษคาร์บอนมอนนอกไซด์เฉียบพลัน: รายงานผู้ป่วย 1 ราย และบททวนวารสาร

ดวงรัตน์ ตะเพียนทอง, นิพนธ์ พวงวรินทร์

ภาวะ *delayed encephalopathy* และการสูญเสียประชน ที่เกิดจากพิษคาร์บอนมอนนอกไซด์แบบเฉียบพลันเป็นภาวะที่พบน้อยและยังไม่เคยมีรายงานผู้ป่วยในประเทศไทย คณะผู้รายงานจึงรายงานผู้ป่วยหญิงไทย อายุ 56 ปี ซึ่งได้รับพิษจากก๊าซคาร์บอนมอนนอกไซด์ขณะไปเที่ยวที่เมืองอริโซนาในช่วงหน้าหนาวและ เกิดความผิดปกติของสมอง 4 สัปดาห์ หลังจากได้รับการรักษาจนหายเป็นปกติจากภาวะพิษจากก๊าซคาร์บอนมอนนอกไซด์ในระยะเฉียบพลัน ผลการตรวจ *brain magnetic resonance imaging* พบความผิดปกติของ *white matter*, *putamen* และ *caudate nucleus* ทั้งสองข้าง ผู้ป่วยได้รับการรักษาด้วย *hyperbaric oxygen therapy (HBOT)* จนอาการค่อย ๆ ดีขึ้นในด้านความจำโดยเริ่มดีขึ้นมากใน 4 สัปดาห์หลังการรักษา