

Case Report

Acute Suppurative Thyroiditis with Thyrotoxicosis[□]

Ouyporn Panamonta MD*, Sunee Panombualert MD*,
Manat Panamonta MD*, Chalida Apinives MD**

[□]This manuscript was presented at the Quarterly Meetings of the Thai Society of Pediatric Endocrinology, February 2008

*Department of Pediatrics, Faculty of Medicine, Srinagarind Hospital, Khon Kaen University, Khon Kaen

**Department of Radiology, Faculty of Medicine, Srinagarind Hospital, Khon Kaen University, Khon Kaen

Background: Acute suppurative thyroiditis (AST) is a rare condition in children, and most children with AST usually have normal thyroid function.

Objective: To report a case of thyrotoxicosis complicating AST in a child.

Case Report: A 6-year-old boy with AST presented with the unusual clinical features of severe thyrotoxicosis. Two palpable masses were found to be of firm to hard consistency with tenderness without any acute inflammatory signs on the overlying skin of the thyroid gland. The diagnosis of AST was confirmed by ultrasonography and fine needle aspiration. Thyroid function tests were normal within a week after antibiotic treatment and surgical drainage.

Conclusion: Transient thyrotoxicosis complicating AST is very rare in children. Awareness of this unusual complication is important to avoid inappropriate treatment of hyperthyroid disease.

Keywords: Acute suppurative thyroiditis, Thyrotoxicosis

J Med Assoc Thai 2009; 92 (10): 1370-3

Full text. e-Journal: <http://www.mat.or.th/journal>

Acute suppurative thyroiditis (AST) is a rare condition, as the thyroid gland is relatively resistant to infection. The common organisms are Staphylococcus and Streptococcus species and anaerobes, but rarely Mycobacterium tuberculosis and fungi are found. AST in children most often arises with congenital conditions connecting the thyroid directly to the oropharynx, such as a pyriform fistula or thyroglossal duct resulting in recurrent infection. Children usually have fever and pain and a normal thyroid function test⁽¹⁻⁴⁾. In Thailand, the first report of AST in children and the authors' previous report showed normal thyroid function test in all patients^(5,6). A small number of cases of thyrotoxicosis complicating AST have been reported in adults but is very rare in children⁽⁷⁻¹²⁾. The first report from Japan described AST with thyrotoxicosis in the immuno-compromised children who received aggressive chemotherapy⁽¹³⁾. Herein the authors report the first case of AST with thyrotoxicosis

in a previously normal child, a presentation similar to subacute thyroiditis.

Case Report

A 6-year-old boy was referred with a painful neck mass, fever, chills and dysphagia. Two weeks prior to admission, he had an upper respiratory tract infection and a sore throat. Swelling of the right thyroid gland was observed one week later and Ampicillin and Gentamicin were given at the local primary hospital. At our tertiary care hospital, the boy still had fever, a painful neck mass, sweating and tachycardia and had lost 2 kg. Physical examination revealed a temperature of 38.5 °C, tachycardia with a heart rate of 120 per minute, two masses at the right lobe and lower part of the left lobe of thyroid gland with marked tenderness, firm to hard consistency, with no fluctuation and no redness of the overlying skin (Fig. 1). Laboratory investigations and thyroid function test showed a leukocyte count of 17,700/mL with polymorphonuclear cells at 78.0%, ESR 62.0 mm/hr, serum T4 18.9 µg/dL, T3 220.47 ng/dL, TSH 0.09 mU/L, FT4 2.51 ng/dL, thyroglobulin 28.5 ng/mL with negative

Correspondence to: Panamonta O, Department of Pediatrics, Faculty of Medicine, Srinagarind Hospital, Khon Kaen University, Khon Kaen 40002, Thailand. Phone: 043-348-382, Fax: 043-348-382. E-mail: ouypan@kku.ac.th

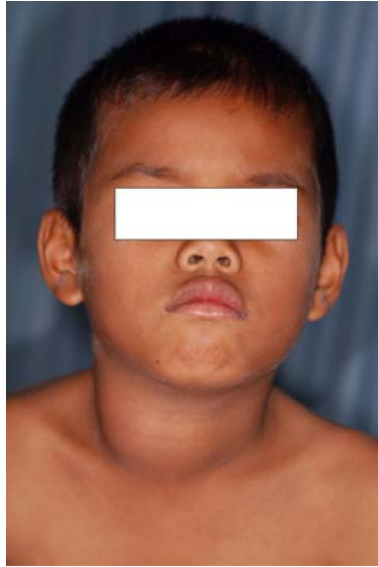

Fig. 1 A mass at the right lobe and lower part of the left lobe of thyroid, firm to hard consistency, with no fluctuation and no redness of the overlying skin

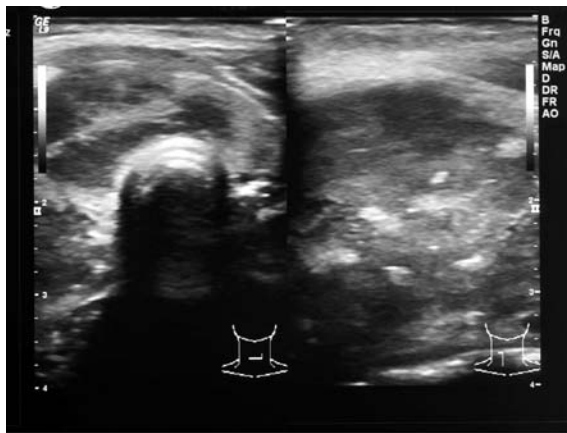


Fig. 2 Ultrasonography of the neck revealed enlargement of the right lobe, isthmus and lower part of the left lobe with an ill-defined area of heterogenous mix-echoic lesions

thyroid autoantibodies. Ultrasonography of the neck revealed enlargement of the right lobe, isthmus and lower part of the left lobe of thyroid gland with an ill-defined area of heterogenous mix-echoic lesions (Fig. 2). Barium swallowing revealed no fistula tract connecting to the thyroid gland. Pus was obtained through fine needle aspiration. A few mixed organisms

(both Gram positive and negative) were observed by a Gram stain of the pus, but negative acid fast staining and no growth of bacteria from the pus culture. Surgical drainage was performed and Clindamycin plus Amikacin were given for 10 days. The thyroid function test returned to normal 5 days after treatment. He had normal thyroid function test and regained weight loss one month later.

Khon Kaen University human investigation committee approved the study and written informed consent from parents was obtained.

Discussion

AST is often associated with a recent upper respiratory tract infection. The relative rarity of thyroid infection is due to its complete encapsulation, generous vascular and lymphatic supply, and high local iodine level. Children and adults are predisposed to thyroid infection by pre-existing thyroid diseases, direct invasion from contiguous structures, presence of a thyroglossal duct remnant, blunt trauma, injury to the throat or a left pyriform sinus fistula^(1,6). Children usually have fever and pain, in association with a tender thyroid mass with generally normal thyroid function tests. The unusual clinical features of AST in the presented patient included the presence of symptoms and signs of severe thyrotoxicosis, firm to hard consistency of a thyroid mass rather than fluctuating or cystic, the lack of acute inflammatory signs on the overlying skin of the thyroid gland, high thyroid hormone levels, and a picture similar to subacute thyroiditis. Transient thyrotoxicosis in AST may follow rapid extensive inflammation of the gland resulting in follicular cell damage and destruction. The leaking of thyroid hormone from the gland raises thyroid hormone levels, causing suppression of TSH and symptoms of thyrotoxicosis. These symptoms often include anxiety, insomnia, palpitations, fatigue, weight loss, and irritability. This is also seen in patients with the toxic phase of subacute thyroiditis (de Quervain's thyroiditis)⁽¹⁴⁾. Ultrasonography often serves as the initial imaging modality for differentiating these two conditions followed by fine needle aspiration of pus. After surgical drainage and proper antibiotic therapy, a thyroid function test returns to normal within a week. To prevent recurrent AST, a barium swallow should be performed during the quiescent phase to rule out the congenital malformation connecting oropharynx with the thyroid. The authors did this and did not find any such malformations.

Conclusion

The authors report a case of acute suppurative thyroiditis in a previously normal child with clinical manifestation of thyrotoxicosis. The diagnosis of AST was confirmed by ultrasonography and fine needle aspiration. Awareness of transient thyrotoxicosis complicating AST is important to avoid inappropriate treatment for hyperthyroid disease. With appropriate antibiotics and drainage of the abscess, the prognosis is usually excellent.

Acknowledgements

The authors wish to thank the Department of Pediatrics at the Faculty of Medicine, Khon Kaen University, for its support and Mr. Bryan Roderick Hamman for assistance with the English-language presentation of the manuscript.

References

1. Sai Prasad TR, Chong CL, Mani A, Chui CH, Tan CE, Tee WS, et al. Acute suppurative thyroiditis in children secondary to pyriform sinus fistula. *Pediatr Surg Int* 2007; 23: 779-83.
2. Astl J, Kuchynkova Z, Taudy M, Betka J. Thyroid abscess at an adolescent age. *Int J Pediatr Otorhinolaryngol* 2003; 67: 1375-8.
3. Chi H, Lee YJ, Chiu NC, Huang FY, Huang CY, Lee KS, et al. Acute suppurative thyroiditis in children. *Pediatr Infect Dis J* 2002; 21: 384-7.
4. Lough DR, Ramadan HH, Aronoff SC. Acute suppurative thyroiditis in children. *Otolaryngol Head Neck Surg* 1996; 114: 462-5.
5. Mo-suwan L. Acute suppurative thyroiditis in children: a case report. *J Med Assoc Thai* 1984; 67: 570-3.
6. Panamonta O, Watanasupt W, Chaichanasuwat B. Acute suppurative thyroiditis in children. *J Med Assoc Thai* 1988; 71: 689-93.
7. Sicilia V, Mezitis S. A case of acute suppurative thyroiditis complicated by thyrotoxicosis. *J Endocrinol Invest* 2006; 29: 997-1000.
8. Fukata S, Miyauchi A, Kuma K, Sugawara M. Acute suppurative thyroiditis caused by an infected pyriform sinus fistula with thyrotoxicosis. *Thyroid* 2002; 12: 175-8.
9. Yung BC, Loke TK, Fan WC, Chan JC. Acute suppurative thyroiditis due to foreign body-induced retropharyngeal abscess presented as thyrotoxicosis. *Clin Nucl Med* 2000; 25: 249-52.
10. Khan EM, Haque I, Pandey R, Mishra SK, Sharma AK. Tuberculosis of the thyroid gland: a clinicopathological profile of four cases and review of the literature. *Aust N Z J Surg* 1993; 63: 807-10.
11. Walsh CH, Dunne C. Hyperthyroidism associated with acute suppurative thyroiditis. *Ir J Med Sci* 1992; 161: 137.
12. Nieuwland Y, Tan KY, Elte JW. Miliary tuberculosis presenting with thyrotoxicosis. *Postgrad Med J* 1992; 68: 677-9.
13. Imai C, Kakihara T, Watanabe A, Ikarashi Y, Hotta H, Tanaka A, et al. Acute suppurative thyroiditis as a rare complication of aggressive chemotherapy in children with acute myelogenous leukemia. *Pediatr Hematol Oncol* 2002; 19: 247-53.
14. Pearce EN, Farwell AP, Braverman LE. Thyroiditis. *N Engl J Med* 2003; 348: 2646-55.

ต่อมไทรอยด์อักเสบเป็นหนองร่วมกับภาวะไทรอยด์เป็นพิษในเด็ก

อวยพร ปะนะมณฑา, สุนีย์ พนมบัวเลิศ, มนัส ปะนะมณฑา, ชลิตา อภินิเวศ

ภูมิหลัง: ต่อมไทรอยด์อักเสบเป็นหนองพบได้น้อยในวัยเด็ก และผู้ป่วยส่วนใหญ่มีการทำงานของต่อมไทรอยด์อยู่ในเกณฑ์ปกติ

วัตถุประสงค์: เพื่อรายงานผู้ป่วยเด็กที่มีต่อมไทรอยด์อักเสบเป็นหนองและมีภาวะไทรอยด์เป็นพิษแทรกซ้อน

รายงานผู้ป่วย: เด็กชายไทยอายุ 6 ปี มีก้อนแข็งกดเจ็บที่คอและมีภาวะพิษจากไทรอยด์อย่างรุนแรงโดยไม่มีอาการอักเสบของผิวหนังบริเวณต่อมไทรอยด์ การบันทึกภาพด้วยคลื่นเสียงความถี่สูง และการใช้เข็มดูดหนองจากต่อมไทรอยด์ช่วยยืนยันการวินิจฉัยต่อมไทรอยด์อักเสบเป็นหนอง การรักษาด้วยการผ่าตัดระบายหนอง และให้ยาปฏิชีวนะที่เหมาะสม ทำให้การทำงานของต่อมไทรอยด์กลับมาเป็นปกติภายในหนึ่งสัปดาห์

สรุป: ภาวะพิษจากไทรอยด์แบบชั่วคราวแทรกซ้อนต่อมไทรอยด์อักเสบเป็นหนองพบได้น้อยในวัยเด็ก การเฝ้าระวังภาวะแทรกซ้อนชนิดนี้มีความสำคัญในการหลีกเลี่ยงการให้ยารักษาภาวะต่อมไทรอยด์ทำงานเกินโดยไม่จำเป็น
