

# Case Report

## Expression of Hormonal Receptor in Patients with Metastasizing Pleomorphic Adenoma of the Major Salivary Gland; A Clinicopathological Report of Three Cases

Noppadol Larbcharoensub MD\*,\*\*, Patcharee Karnsombut Cert, MLT\*,  
Jumroon Tungkeeraticchai MD\*\*\*, Supawadee Prakunhungsit MD\*\*\*,  
Ladawan Narkwong MD\*\*\*\*, Juvady Leopairut MD\*

\* Department of Pathology, Faculty of Medicine, Ramathibodi Hospital, Mahidol University, Bangkok, Thailand

\*\* Department of Anatomy, Faculty of Science, Mahidol University, Bangkok, Thailand

\*\*\* Department of Otolaryngology, Faculty of Medicine, Ramathibodi Hospital, Mahidol University, Bangkok, Thailand

\*\*\*\* Department of Radiology, Faculty of Medicine, Ramathibodi Hospital, Mahidol University, Bangkok, Thailand

---

**Background:** Metastasizing pleomorphic adenoma is an uncommon malignant tumor of the salivary gland demonstrating benign epithelial and modified myoepithelial elements intermingling with tissue of mucoid, myxoid, or chondroid appearance that inexplicably manifests local or distant metastasis.

**Objective:** To determine the expression of hormonal receptor in the patients with metastasizing pleomorphic adenoma of the major salivary gland.

**Material and Method:** Medical records, clinical and pathologic findings of three patients who were diagnosed as metastasizing pleomorphic adenoma were reviewed. The immunohistochemical stains for estrogen receptor, progesterone receptor, and Ki-67 were performed.

**Results:** Three cases of metastasizing pleomorphic adenoma, clinically presenting as painless, gradually enlarged cervical lymph nodes were reported. The pathologic examinations of the cervical lymph nodes are morphologically and immunohistologically identical to the sialoadenectomy specimen. Immunohistochemical stains show positive reactivity to progesterone receptor, but negative reactivity to estrogen receptor in both mesenchymal and epithelial components of pleomorphic adenoma.

**Conclusion:** These are the first reported cases of metastasizing pleomorphic adenoma of the major salivary glands associated with expression of progesterone receptor in both specimens of sialoadenectomy and lymph node biopsy. This finding supports the pathogenesis of benign metastasis of tumor. However, the role of hormonal receptor in the pathogenesis and treatment of salivary metastasizing pleomorphic adenoma should be further investigated.

**Keywords:** Adenoma, Pleomorphic, Immunohistochemistry, Neoplasm metastasis, Receptors, Progesterone, Salivary gland neoplasms

*J Med Assoc Thai* 2009; 92 (9): 1250-5

Full text. e-Journal: <http://www.mat.or.th/journal>

---

Metastasizing pleomorphic adenoma (MPA) is a histologically benign epithelial and modified myoepithelial elements intermingling with tissue of mucoid, myxoid, or chondroid appearance that

inexplicably manifests local or distant metastasis<sup>(1)</sup>. This term was introduced in 1953 by Foote and Frazel<sup>(2)</sup>. In 2005, according to World Health Organization (WHO) classification of tumours of the head and neck and Armed Forces Institute of Pathology (AFIP) classification of the tumors of the salivary glands, MPA is classified as an entity in malignant pleomorphic adenomas<sup>(1,3)</sup>. MPA is distinct from the other malignant

---

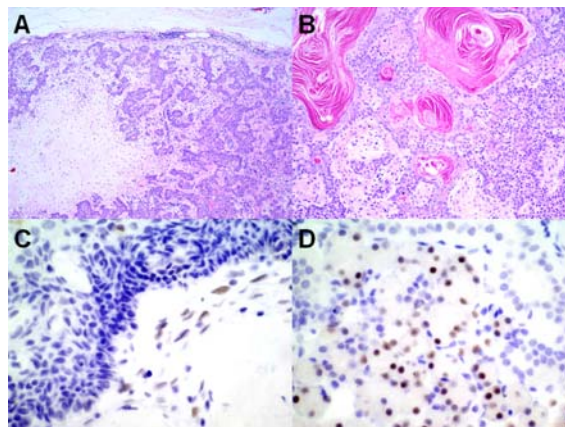
Correspondence to: Larbcharoensub N, Department of Pathology, Ramathibodi Hospital, Mahidol University, Bangkok 10400, Thailand. Phone: 0-2354-7277, Fax: 0-2354-7266, E-mail: Noppadol\_1@hotmail.com

pleomorphic adenoma including carcinoma ex pleomorphic adenoma and carcinosarcoma, because MPA remains histologically benign but metastasis<sup>(1,3)</sup>. To our knowledge, this disease has not been documented in Thai patients. The present report describes three patients with MPA expressing hormonal receptor, which appears to be the first report in the literature. Clinical investigations, histopathologic and immunopathologic features of cervical lymph nodes show typically characteristic findings of MPA. Report of Three Cases

## Case Report

### Case 1

A 36-year-old Thai female underwent right submandibulectomy at Ramathibodi Hospital on October 1994, because of the painless, gradually enlargement of her right submandibular gland of 2 months' duration. At the operation, a 4-cm submandibular mass was noted. Pathology revealed pleomorphic adenoma. There was no evidence of extracapsular growth, atypia, vascular and perineural involvement. She was seen for follow-up evaluation regularly for the first year, with no complaints. Thereafter, she was lost to follow-up, but returned 8 years later for antenatal care visit and labor. History and physical examination at that visit was unremarkable. After one year, she was evaluated because of upper respiratory tract infection symptoms. Physical examination of the neck revealed multiple bilateral cervical lymph nodes measuring 0.5 to 2.5 cm in diameter. Fine needle aspiration (FNA) of the left cervical lymph nodes was performed and revealed pleomorphic adenoma. Excisional biopsy of the cervical lymph nodes was performed and revealed MPA with a few perinodal invasions (Fig. 1A, 1B). Immunohistochemical stains showed tumorous mesenchymal in the right submandibular tumor and cervical lymph nodes to be positive with progesterone receptor (PR) (DAKO), and Ki-67 (DAKO) (Table 1),



**Fig. 1** Histopathology (1A, 1B) and immunohistochemical stain for progesterone receptor (PR) (1C, 1D). The section of the cervical lymph node shows benign epithelial and modified myoepithelial elements intermingling with chondroid tissue, x40 (1A). Focal squamous differentiation is detected, x100 (1B). The PR immunohistochemistry discloses nuclear staining in tumorous mesenchymal component of pleomorphic adenoma, but not in the surrounding epithelial compartment, x400 (1C). The submandibular acinar cells are positive for PR immunohistochemistry, x400 (1D)

whereas the estrogen receptor (ER) immunohistochemical stain was negative (Fig. 1C). The remaining submandibular acinar cells showed positive PR immunohistochemical stain in the nuclei (Fig. 1D). Chest roentgenography was within normal limit. The postoperative course was uneventful. The patient is currently disease free at 6 months after surgery.

### Case 2

A 42-year-old Thai female came to Ramathibodi Hospital on January 2006 with the complaint of multiple left cervical lymphadenopathy, starting 2 years prior to admission. She had undergone an

**Table 1.** Immunohistochemistry - results of primary antibodies used

Antigen	Clone	Dilution	Source	Reactivity		
				Case 1	Case 2	Case 3
Estrogen receptor	1D5	1:100	Dako, Glustrup, Denmark	Negative	Negative	Negative
Progesterone receptor	PR AT4.14	1:50	Dako, Glustrup, Denmark	15%	6%	8%
Ki-67	Polyclonal	1:100	Dako, Glustrup, Denmark	5%	6%	5%

uneventful excision of a pleomorphic adenoma of the left superficial parotid gland in 1996. No pain or facial palsy was described. Physical examination revealed well-defined, firm left cervical lymph nodes measuring 0.5 to 1 cm in diameter. An evaluation of the left parotid area was within normal limit. Total excision of the left cervical lymph nodes was performed. The histopathology showed MPA with morphologically identical to the parotidectomy specimen. No areas of malignant epithelial and mesenchymal lesions were detected. The immunohistochemical stain for PR was positive in tumorous mesenchymal cells. Tumor cells were negative for ER. Chest roentgenography was within normal limit. The postoperative course was uneventful. She was free from recurrence 30 months after excisional biopsy of the cervical lymph node.

### Case 3

A 40-year-old Thai female presented with multiple right cervical masses on February 2008. The first symptom had been observed 27 years earlier with the complaint of the right parotid mass. Fourteen years later, the tumor was excised with a superficial parotidectomy that spared the facial nerve. The pathologic diagnosis was pleomorphic adenoma. After one year, she observed a local recurrence consisting in a 4x3x2 cm tumor mass that affected the deep parotid lobe. The total parotidectomy was performed. The pathologic diagnosis was recurrent pleomorphic adenoma with infiltrating surgical margin. After the second surgery, the patient developed right facial palsy. She was lost to follow-up, but returned 12 years later with the complaint of the right cervical lymphadenopathy. Physical examination of the neck revealed multiple cervical lymph nodes measuring 0.3

to 1 cm in diameter. Excisional biopsy was performed and revealed MPA. The immunohistochemical stain for PR was positive in tumorous mesenchymal component of MPA. Tumor cells were negative for ER. Chest roentgenography was within normal limit. The postoperative course was uneventful. She received 6,600 cGy in divided doses for definitive treatment. She was still uneventful until 6 months after the operation and radiotherapy.

All patients' data are summarized in Table 2. This present study was approved by the committee on human research at Ramathibodi Hospital (ID05-51-37).

### Discussion

Metastasizing pleomorphic adenoma (MPA) is an uncommon clinically malignant tumor of the salivary gland<sup>(1,3)</sup>. MPA is a nebulous condition in which metastatic histologically benign-appearing pleomorphic adenoma deposits in the bone, lungs, lymph nodes, or subcutaneous tissue<sup>(4)</sup>. The average age at presentation occurs principally during the third to fourth decade. The reported ages of patients range from 8 to 73 years<sup>(4,5)</sup>. Most of the patients have a history of sialoadenectomy. The primary neoplasm, typically removed many years before the metastatic deposits are detected. There is an overwhelming history of incomplete surgery for salivary pleomorphic adenoma. Most patients had local recurrences before metastasis<sup>(4)</sup>. The mean presentation-to-metastasis latencies are 16.9 and 12.3 years for the patients with and without history of local recurrence, respectively<sup>(4)</sup>. The most frequently presenting symptoms of MPA are a palpable mass at the region of the head and neck.

The microscopic findings demonstrate benign epithelial and modified myoepithelial elements

**Table 2.** Patients' data summary

Detail	Case 1	Case 2	Case 3
Age at first diagnosis (years)	36	32	27
Sex	Female	Female	Female
Location	Submandibular	Parotid	Parotid
Side of primary tumor	Right	Left	Right
Size of primary tumor (cm)	4	Not available	4
Duration between first diagnosis and metastasis (years)	9	10	13
Side of lymph node	Bilateral	Left	Right
Size of lymph node (cm)	0.5 to 2.5	0.5 to 1	0.3 to 1
Treatment	Surgical resection	Surgical resection	Surgical resection and radiotherapy 6,600 cGy

**Table 3.** The details of expression of hormonal receptor in recurrent and/or malignant pleomorphic adenoma

Authors	Hormonal receptor study	Groups of salivary gland showing hormonal expression
Glas et al, 2002 <sup>(15)</sup> Nasser et al, 2003 <sup>(16)</sup>	Progesterone receptor Androgen, estrogen, and progesterone receptors	Recurrent pleomorphic adenoma of the parotid gland Malignant salivary gland tumor
Larbcharoensub et al	Progesterone receptor	Metastasizing pleomorphic adenoma

intermingling with tissue of mucoid, myxoid, or chondroid appearance that was almost identical to the previous sialoadenectomy specimen<sup>(1,3)</sup>. Therefore, FNA of the metastatic site typically diagnoses pleomorphic adenoma.

The pathogenesis of MPA is enigmatic. The relationship between the MPA and its benign sialoadenectomy counterpart has not been completely established. The pathogenesis of benign metastasis is widely accepted<sup>(3,6,7)</sup>. The hormonal receptor positivity in both salivary pleomorphic adenoma and extrasalivary cervical lymph nodes in the authors' cases, gives credence to this concept. On the other hand, there is also evidence to indicate that some reported examples might represent the multifocal origin of tumors rather than metastases from a benign pleomorphic adenoma. The second pleomorphic adenoma arising from salivary tissue embryologically entrapped within the lymph node has been postulated<sup>(8,9)</sup>. However, the fact that these lesions almost always occur after an operative procedure in which manipulation of the salivary gland tumor has taken place, lymphatic and vascular invasion followed surgical manipulation is hypothesized<sup>(6,10-14)</sup>.

Patients previously reported with recurrent pleomorphic adenoma of the parotid gland had been identified PR in the tumor cells<sup>(15)</sup>. Furthermore, there are a few cases in the literature documenting the expression of estrogen and progesterone receptors in malignant salivary gland tumors and recurrent pleomorphic adenoma<sup>(16)</sup>. It is suggested that hormonal receptor may be a factor in the development of malignant pleomorphic adenomas. The authors' cases are the MPA expressing PR in mesenchymal component. The details of expression of hormonal receptor in recurrent and/or malignant pleomorphic adenoma are shown in Table 3. The present findings suggest that predisposing hormonal factors may play a major role in susceptibility to metastasis of pleomorphic adenoma. The present findings also suggest the good possibility that tumors express PR will respond to endocrine

therapy. Since the study of relationship between hormonal receptor and MPA are still scarce, the role of hormonal receptor in the pathogenesis and treatment of salivary MPA should be further investigated.

Surgical excision remains the cornerstone of management of MPAs. Metastasectomy conferred a significant survival advantage on univariate log-rank analysis<sup>(4)</sup>. Some literatures suggest combined surgery and adjuvant radiotherapy<sup>(6)</sup>. However, the role of radiotherapy, therefore, awaits further investigation. The prognosis of MPA seems to be better than other types of malignant pleomorphic adenoma including carcinoma ex pleomorphic adenoma and carcinosarcoma<sup>(1,3)</sup>. This raises the possibility of the histologically benign appearance, resulting in a better prognosis of this subtype of malignant pleomorphic adenoma of the salivary gland.

### References

1. Gnepp DR. Metastasizing pleomorphic adenoma. In: Barnes L, Eveson JW, Reichart P, Sidransky D, editors. World Health Organization Classification of Tumours: Pathology and genetics of head and neck tumours. Lyon, France: IARC Press; 2005: 245.
2. Foote FW Jr, Frazell EL. Tumors of the major salivary glands. *Cancer* 1953; 6: 1065-133.
3. Ellis GL, Auclair PL. Metastasizing mixed tumor. In: Tumors of the salivary glands. 3<sup>rd</sup> series. Washington D.C.: Armed Forces Institute of Pathology; 1996: 245-51.
4. Nouraei SA, Ferguson MS, Clarke PM, Sandison A, Sandhu GS, Michaels L, et al. Metastasizing pleomorphic salivary adenoma. *Arch Otolaryngol Head Neck Surg* 2006; 132: 788-93.
5. Schreibstein JM, Tronic B, Tarlov E, Hybels RL. Benign metastasizing pleomorphic adenoma. *Otolaryngol Head Neck Surg* 1995; 112: 612-5.
6. Wenig BM, Hitchcock CL, Ellis GL, Gnepp DR. Metastasizing mixed tumor of salivary glands. A clinicopathologic and flow cytometric analysis.

- Am J Surg Pathol 1992; 16: 845-58.
7. Bradley PJ. 'Metastasizing pleomorphic salivary adenoma' should now be considered a low-grade malignancy with a lethal potential. *Curr Opin Otolaryngol Head Neck Surg* 2005; 13: 123-6.
  8. Shinohara M, Ikebe T, Nakamura S, Takenoshita Y, Oka M, Mori M. Multiple pleomorphic adenomas arising in the parotid and submandibular lymph nodes. *Br J Oral Maxillofac Surg* 1996; 34: 515-9.
  9. Seifert G. Primary salivary gland tumors in lymph nodes of the parotid gland. Report of 3 cases and review of the literature. *Pathologie* 1997; 18: 141-6.
  10. Chen I, Tu H. Pleomorphic adenoma of the parotid gland metastasizing to the cervical lymph node. *Otolaryngol Head Neck Surg* 2000; 122: 455-7.
  11. Stennert E, Guntinas-Lichius O, Klussmann JP, Arnold G. Histopathology of pleomorphic adenoma in the parotid gland: a prospective unselected series of 100 cases. *Laryngoscope* 2001; 111: 2195-200.
  12. Goodisson DW, Burr RG, Creedon AJ, Stirling RW, Morgan PR, Odell EW. A case of metastasizing pleomorphic adenoma. *Oral Surg Oral Med Oral Pathol Oral Radiol Endod* 1999; 87: 341-5.
  13. Marioni G, Marino F, Stramare R, Marchese-Ragona R, Staffieri A. Benign metastasizing pleomorphic adenoma of the parotid gland: a clinicopathologic puzzle. *Head Neck* 2003; 25: 1071-6.
  14. Steele NP, Wenig BM, Sessions RB. A case of pleomorphic adenoma of the parotid gland metastasizing to a mediastinal lymph node. *Am J Otolaryngol* 2007; 28: 130-3.
  15. Glas AS, Hollema H, Nap RE, Plukker JT. Expression of estrogen receptor, progesterone receptor, and insulin-like growth factor receptor-1 and of MIB-1 in patients with recurrent pleomorphic adenoma of the parotid gland. *Cancer* 2002; 94: 2211-6.
  16. Nasser SM, Faquin WC, Dayal Y. Expression of androgen, estrogen, and progesterone receptors in salivary gland tumors. Frequent expression of androgen receptor in a subset of malignant salivary gland tumors. *Am J Clin Pathol* 2003; 119: 801-6.

---

รายงานผู้ป่วยสามรายที่มีการแสดงออกของตัวรับฮอร์โมนในเนื้องอกชนิด *metastasizing pleomorphic adenoma* ของต่อมน้ำลาย

นพดล ลากเจริญทรัพย์, พิชริย์ การสมบัติ, จำริญ ตั้งกิริติชัย, สุภาวดี ประคุณหังสิต, ลดาวัลย์ นาควงษ์, ยวดี เลี้ยวไพรัตน์

**ภูมิหลัง:** เนื้องอกชนิด *metastasizing pleomorphic adenoma* เป็นเนื้องอกของต่อมน้ำลายที่พบบ่อย มีลักษณะเป็นกลุ่มของเซลล์นิวเคลียสและเซลล์กล้ามเนื้ออยู่ร่วมกัน สามารถมีการแพร่กระจายทั้งชนิดอยู่กับที่และไปที่อื่น

**วัตถุประสงค์:** เพื่อประเมินการแสดงออกของตัวรับฮอร์โมน ในเนื้องอกชนิด *metastasizing pleomorphic adenoma* ที่มีประวัติผ่าตัดเนื้องอกต่อมน้ำลาย

**วัสดุและวิธีการ:** เวชระเบียน ประวัติการตรวจรักษาและผลการตรวจทางพยาธิวิทยาชิ้นเนื้อ ของผู้ป่วย สามราย ที่ได้รับการวินิจฉัยว่าเป็น เนื้องอกชนิด *metastasizing pleomorphic adenoma* ได้รับการศึกษาพร้อมกับได้ทำการศึกษาการแสดงออกของโปรตีน คือ estrogen receptor, progesterone receptor, และ Ki-67 โดยวิธีอิมมูโนวิทยาเนื้อเยื่อ

**ผลการศึกษา:** รายงานผู้ป่วย 3 รายเป็นเนื้องอกชนิด *metastasizing pleomorphic adenoma* ผู้ป่วยมีประวัติผ่าตัดเนื้องอกต่อมน้ำลาย ต่อมาเมื่ออาการก้อนท่อน้ำลายก่อน ไม่เจ็บ ที่บริเวณคอโต ได้ทำการผ่าตัด และตรวจทางพยาธิวิทยาพบเป็น กลุ่มเซลล์เนื้องอกในต่อมน้ำเหลืองคอมีลักษณะเหมือนในต่อมน้ำลาย มีการแสดงออกของตัวรับฮอร์โมนเพศโพรเจสเตอโรน แต่ไม่แสดงออกต่อตัวรับฮอร์โมนเอสโตรเจน

**สรุป:** รายงานนี้เป็นกรณีศึกษาแรกของเนื้องอกชนิด *metastasizing pleomorphic adenoma* ที่มีการแสดงออกของตัวรับฮอร์โมนเพศโพรเจสเตอโรนทั้งในชิ้นเนื้อต่อมน้ำลายและต่อมน้ำเหลือง ซึ่งสนับสนุนแนวคิดเรื่องการแพร่กระจายของเนื้องอกไม่ร้ายแรง แต่อย่างไรก็ตามพยากรณ์กำเริบของการแสดงออกของตัวรับฮอร์โมนเพศในเนื้องอก *metastasizing pleomorphic adenoma* ของต่อมน้ำลายยังคงต้องศึกษาเพิ่มเติมต่อไป