

The Role of Laparoscopic Management in Suspected Traumatic Diaphragmatic Injury Patients: A Tertiary Care Center Experience[†]

Supaporn Opananon MD*, Thawatchai Akaraviputh MD**,
Kris Keorochana MD*, Lertpong Somcharit MD*

[†]Presented at the 11th World Congress of Endoscopic Surgery, September 2nd-5th, 2008, Yokohama, Japan

* Division of Trauma Surgery, Department of Surgery, Faculty of Medicine Siriraj Hospital, Mahidol University, Bangkok, Thailand

** Endo-laparoscopic Unit, Department of Surgery, Faculty of Medicine Siriraj Hospital, Mahidol University, Bangkok, Thailand

Background: Management of posttraumatic diaphragmatic injury (DI) is still challenging. In suspected patients with stable hemodynamic, laparoscopy may aid in the diagnosis and treatment of DI.

Objective: To analyze and determine the role of laparoscopy in diagnosis and treatment of suspected diaphragmatic injury patients at Trauma Centre, Faculty of Medicine Siriraj Hospital.

Material and Method: A prospective descriptive study was conducted between 2001 and 2008 in Division of Trauma Surgery, Siriraj Hospital, Mahidol University, Thailand. Twenty-four suspected DI patients with stable hemodynamic were reviewed and analyzed. Laparoscopy was performed in all patients.

Results: Of the patients, 95.8% were men with a mean age of 27.3 years (range, 14-54 yr). Twenty-three patients (95.8%) had a penetrating injury. Five patients (20.8%) presented with tachypnea and decreased breath sound. Pneumothorax occurred in five patients (20.8%). Chest x-ray revealed diaphragmatic elevation in one patient (4.2%). Five cases (20.8%) were found DI. In one patient with right-sided DI, thoracoscopic repair was performed. There were no procedure related complications. All patients were discharged 72 hours after the operation.

Conclusion: Laparoscopy is an excellent diagnostic and therapeutic tool in hemodynamically stable patients. Left-sided DI can be successfully treated with laparoscopic repair. However, right-sided DI may be better with thoracoscopic repair.

Keywords: Diaphragmatic injury, Laparoscopic repair

J Med Assoc Thai 2009; 92 (7): 903-8

Full text. e-Journal: <http://www.mat.or.th/journal>

Traumatic diaphragmatic injury is a common injury in 10% to 15% of victims of penetrating chest trauma⁽¹⁾. It occurs in 1% to 5% of automobile accident cases^(2,3). Diaphragmatic injury is one of the most commonly missed injuries in trauma cases, especially in the absence of an immediate indication for surgery in the injured patient. Early recognition of diaphragmatic hernias can be a diagnostic challenge and delayed

presentation is common. Diagnosis is based on strong clinical suspicion. Upon diagnosis, surgical repair is necessary because of the possibility of life threatening complications such as diaphragmatic herniation and strangulation of abdominal organs may even occur late. Overlooked diaphragmatic injury has been associated with a mortality of 20-36%⁽⁴⁾. Unfortunately, over 90% of diaphragmatic injuries associated with blunt trauma are initially overlooked. Traditionally, surgery has been the treatment of choice, but unnecessary laparotomy can be up to 25% of morbidity⁽⁴⁾.

The current diagnostic tools include Computed tomography (CT scan) and minimally invasive surgical

Correspondence to: Opananon S, Division of Trauma Surgery, Department of Surgery, Faculty of Medicine Siriraj Hospital, Mahidol University, Bangkok 10700, Thailand. Phone: 0-2419-7727-9, Fax: 0-2419-7730, E-mail: anne_surgeon@hotmail.com

techniques (laparoscopy) in stable patients. Laparoscopy could provide more accurate diagnosis and treatment. Diagnostic laparoscopy (DL) was first reported in traumatic patients by Gazzaniga in 1975⁽⁵⁾. At present, many physicians recommend laparoscopy for both diagnosis and treatment in diaphragmatic injury. However, in Thailand, there have been only a few data on laparoscopic management in diaphragmatic injury patient.

The purpose of the present study was to analyze and determine the role of laparoscopy in the diagnosis and treatment of diaphragmatic injury patient at Siriraj Trauma Centre.

Material and Method

Between 2001 and 2008, twenty-four selected haemodynamically stable patients (23 men), with suspected traumatic diaphragmatic injury, were treated in the Division of Trauma Surgery, Department of Surgery, Faculty of Medicine Siriraj Hospital, Mahidol University, Thailand were identified. Nasogastric tube was placed. A plain radiographic film of the chest with external marker was obtained, in order to evaluate associated injury and rule out pneumo/hemothorax. Focus Assessment Sonography in Trauma patients (FAST) was performed routinely in all patients. They were prospectively evaluated with diagnostic laparoscopy to determine the presence of diaphragmatic injury and laparoscopic repair were undergone by a surgical trauma team. Patients with indication for exploratory laparotomy such as peritonitis or that refused treatment were excluded. Data collection included demographics, mechanism of injury, signs and symptoms, investigation, organ injury, anatomic site of injury, and laparoscopic data. Data was collected and analyzed to determine the clinical factors for the successful diagnosis and treatment. The Institutional Review Board of Faculty of Medicine Siriraj Hospital, Mahidol University approved the present study.

Data management was performed using SPSS® statistical software version 12.0.

Results

Of the 24 patients, 95.8% (23) were men. The mean age was 27.3 years (range, 14-54 yr.). Twenty-three patients (91.7%) were victims of penetrating injury (Table 1). The mean lowest preoperative systolic blood pressure was 126 ± 17 mm Hg (max 162, min 91). Five patients (20.8%) presented with tachypnea and decreased breath sound and they were immediately

managed by tube thoracostomy at the resuscitation area. Eighteen cases (75%) had normal chest radiograph. Chest x-ray (CXR) found diaphragmatic elevation in one patient (4.2%). Pneumo/hemothorax could be revealed in five patients (20.8%). One of these patients had open pneumothorax. Sixty percent (3/5) of patients with pneumo/hemothorax were also found to have diaphragmatic injuries (Table 2). One case was positive for FAST with minimal fluid at hepatorenal pouch. However, there was no diaphragmatic injury in this case.

All patients underwent diagnostic laparoscopy within 24 hours postinjury. Laparoscopy was performed under general anesthesia. Four patients with DI (16.7%) were left-sided and treated by laparoscopic repair (Fig. 1). In one patient with right-sided DI, video assisted thoracoscopic (VAT) repair was performed. All injuries were successfully managed laparoscopically. There was no procedure related complications. The patients were discharged 72 hours after the operation. All patients with DI were followed up in the outpatient trauma clinic at a week following discharge. All patients were doing well at follow-up period.

Discussion

DI is a marker of severe trauma. The mechanism could be penetrating or blunt. Most of the patients had penetrating injury in the present study. Traumatic DI is the frequent difficulty in making the diagnosis. Therefore, diagnosis is based on clinical suspicious cases. In Australia, the mortality rate associated with missed diagnosis is 20-36%^(4,6). Chest x-ray is basic imaging for evaluation of traumatic DI. Asymmetry of hemidiaphragm or changing diaphragmatic levels is often suspicious for traumatic DI. The presence of the

Table 1. The results of laparoscopic management in the patients with thoraco-abdominal injury (n = 24)

	No.	%
Diaphragmatic injury (DI)	5	20.8
Left-sided DI	4	16.7
Right-sided DI	1	4.2
Laparoscopic repair DI	4	16.7
VAT repair DI	1	4.2
Success rate	24	100.0
Complication	0	0.0
Discharged 72 hr after the operation	24	100.0

* VAT = video-assisted thoracoscopy

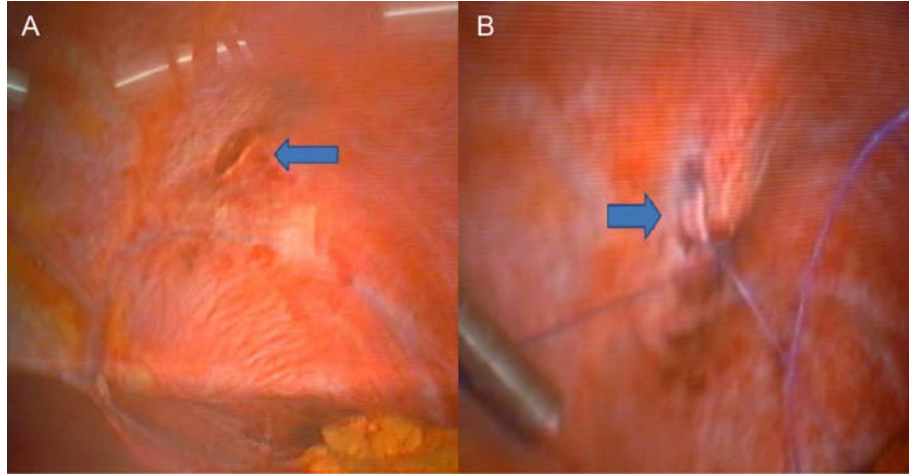


Fig. 1 A hole at left diaphragm (A) was successfully closed using full-thickness single sutures (B)

nasogastric tube above the diaphragm or bowel gas of hollow viscera in the chest on chest x-ray film is considered diagnostic by some⁽⁷⁾. Up to 60% of radiographic findings are nonspecific abnormalities such as rib fractures, pneumo/hemothorax, pulmonary contusion or negative finding⁽⁸⁻¹⁰⁾. In the review of Gelman et al, chest radiography is diagnostic or highly suggestive traumatic diaphragmatic injury in 64% of cases⁽¹¹⁾. However, 11.1% (2/18) of patients with a normal chest radiograph were found to have a diaphragmatic injury (Table 2). Chest x-ray revealed diaphragmatic elevation in one patient (7.1%) (Fig. 2).

Since its introduction by Root in 1965, diagnostic peritoneal lavage (DPL) has been widely used in the evaluation of the trauma patient⁽¹²⁾. Nevertheless, up to 25% of patients with a ruptured diaphragm have a negative DPL^(7,13,14). FAST is now

becoming standard of management in trauma patients and is even included as part of the ATLS course. Anyhow, there have been only a few published reports on the evaluation of diaphragmatic injury while performing the FAST examination. In the present study, positive FAST could not evaluate DI. CT of the abdomen is very accurate for solid organ injury or free intraperitoneal fluid but may miss diaphragmatic injury if there is no organ herniation.

Table 2. Comparisons of the clinical presentations of patients with and without diaphragmatic injuries (DI)

Clinical presentation	Total (cases)	With DI	Without DI
Mechanism of injury			
Penetrating injury	23	4	19
Blunt injury	1	1	0
Chest radiography			
Normal	18	2	16
Pneumo/hemothorax	5	3	2
Elevated diaphragm	1	1	0
Positive FAST	1	0	1

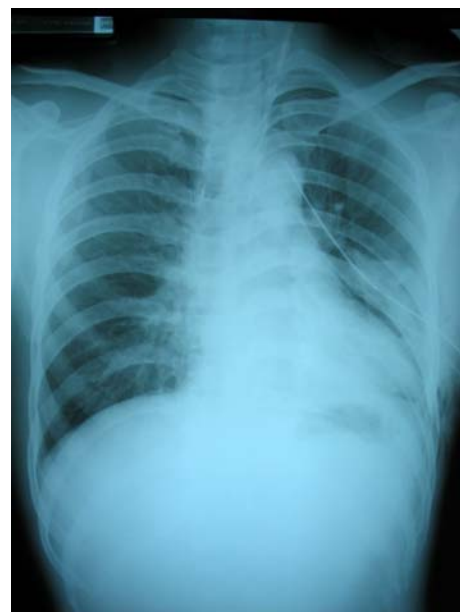

Fig. 2 CXR showed left pneumothorax and elevated left hemidiaphragm with chest drain inside

Exploratory laparotomy is indicated in unstable hemodynamic injured patients. Mandatory exploration has been used for managing the injured patient with an equivocal physical examination, but was non-therapeutic up to 25% and carries a morbidity of 20%⁽⁴⁾. Minimally Invasive Surgery has played only a small role in trauma surgery. To date, trauma surgeons undergo laparoscopy and video assisted thoracoscopy (VAT) in the selected hemodynamically stable, asymptomatic patients with suspected DI. Diagnostic laparoscopy (DL) provides an accurate means of diagnosing diaphragmatic injury and a simultaneous opportunity for repair. Diagnostic laparoscopy is also used for evaluation of other injured abdominal organs. Potential advantage of laparoscopy over standard open laparotomy is that the incisions are smaller, allowing less pain, quicker recovery time, and shorter postoperative hospital stays⁽¹⁵⁾.

Weinberg et al have described “awake” laparoscopy (AL) techniques, using local anesthesia with intravenous sedation⁽¹⁶⁾. Fifteen patients underwent AL without complications. AL negative group have short hospital stay and cost savings compared with the DL negative group under GA. However, in our centre, all cases underwent DL under general anesthesia due to careful diaphragmatic inspection. The left DI is affected more than the right due to the protective effect offered by the underlying liver and about 80% in the present series. Only one patient with right-sided DI with normal CXR was found. In one patient who lost consciousness from traumatic subarachnoid hemorrhage, CT incidentally revealed right DI (Fig. 3). VAT repair was performed in the presented case. VAT is useful minimally invasive method for assessment of the diaphragm, early evacuation of clotted hemothorax, and evaluation of ongoing bleeding^(17,18).

Laparoscopic suturing techniques are a challenge, especially for the inexperienced laparoscopic surgeon. The healing of the diaphragm when laparoscopic repair compared to open repair is not known. Murray et al described a pig model that had lacerated diaphragmatic injuries created. They were repaired using single-layer open repair, single-layer laparoscopic repair, or laparoscopic stapling. The gross integrity, histologic appearance, and tensile strength were assessed after a 6-week healing period. The results were similar⁽¹⁹⁾. In our trauma centre, the diaphragm was repaired by single-layer full-thickness technique. The patients recovered rapidly and were discharged 72 hours after the operation. The success

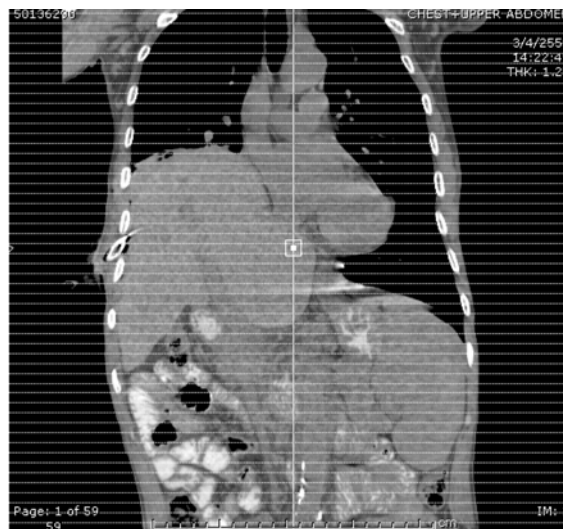


Fig. 3 CT scan showed right diaphragmatic injury in a 54-year-old man after a motor vehicle accident with traumatic subarachnoid hemorrhage

rate for diaphragmatic repairing by laparoscopy was 100%. There was no mortality associated with this procedure.

Conclusion

In summary, DI is frequently overlooked. The signs and symptoms of diaphragmatic rupture are nonspecific. Although laparoscopy has a role in a small and selected group of trauma patients, it is a safe and effective modality for evaluating injuries. This technique should be used more frequently in selected patients with thoracoabdominal injury. Laparoscopy may expand the diagnostic and therapeutic role in trauma patients. Left-sided DI can be repaired laparoscopically but right-sided DI proved difficult and may be better dealt thoracoscopically. However, successful management of these injuries depends on a high index of suspicion and the management of associated injuries.

References

1. Brandt ML, Luks FI, Spigland NA, DiLorenzo M, Laberge JM, Ouimet A. Diaphragmatic injury in children. *J Trauma* 1992; 32: 298-301.
2. Rodriguez-Morales G, Rodriguez A, Shatney CH. Acute rupture of the diaphragm in blunt trauma: analysis of 60 patients. *J Trauma* 1986; 26: 438-44.
3. Voeller GR, Reisser JR, Fabian TC, Kudsk K, Mangiante EC. Blunt diaphragm injuries. A

- five-year experience. *Am Surg* 1990; 56: 28-31.
4. Lindsey I, Woods SD, Nottle PD. Laparoscopic management of blunt diaphragmatic injury. *Aust NZ J Surg* 1997; 67: 619-21.
 5. Krausz MM, Abbou B, Hershko DD, Mahajna A, Duek DS, Bishara B, et al. Laparoscopic diagnostic peritoneal lavage (L-DPL): A method for evaluation of penetrating abdominal stab wounds. *World J Emerg Surg* 2006; 1: 3.
 6. Friese RS, Coln CE, Gentilello LM. Laparoscopy is sufficient to exclude occult diaphragm injury after penetrating abdominal trauma. *J Trauma* 2005; 58: 789-92.
 7. Blaivas M, Brannam L, Hawkins M, Lyon M, Sriram K. Bedside emergency ultrasonographic diagnosis of diaphragmatic rupture in blunt abdominal trauma. *Am J Emerg Med* 2004; 22: 601-4.
 8. Waldschmidt ML, Laws HL. Injuries of the diaphragm. *J Trauma* 1980; 20: 587-92.
 9. Laws HL, Hawkins ML. Diaphragmatic injury. In: *Advances in trauma*. Vol. 2. Chicago: Yearbook Medical Publishers; 1987: 207-27.
 10. Wise L, Connors J, Hwang YH, Anderson C. Traumatic injuries to the diaphragm. *J Trauma* 1973; 13: 946-50.
 11. Gelman R, Mirvis SE, Gens D. Diaphragmatic rupture due to blunt trauma: sensitivity of plain chest radiographs. *AJR Am J Roentgenol* 1991; 156: 51-7.
 12. Root HD, Hauser CW, Mckinley CR, Lafave JW, Mendiola RP Jr. Diagnostic Peritoneal lavage. *Surgery* 1965; 57: 633-7.
 13. Freeman T, Fischer RP. The inadequacy of peritoneal lavage in diagnosing acute diaphragmatic rupture. *J Trauma* 1976; 16: 538-42.
 14. Estrera AS, Landay MJ, McClelland RN. Blunt traumatic rupture of the right hemidiaphragm: experience in 12 patients. *Ann Thorac Surg* 1985; 39: 525-30.
 15. Ditmars ML, Bongard F. Laparoscopy for triage of penetrating trauma: the decision to explore. *J Laparoendosc Surg* 1996; 6: 285-91.
 16. Weinberg JA, Magnotti LJ, Edwards NM, Claridge JA, Minard G, Fabian TC, et al. Awake laparoscopy for the evaluation of equivocal penetrating abdominal wounds. *Injury* 2007; 38: 60-4.
 17. Smith RS, Fry WR, Tsoi EK, Morabito DJ, Koehler RH, Reinganum SJ, et al. Preliminary report on videothoracoscopy in the evaluation and treatment of thoracic injury. *Am J Surg* 1993; 166: 690-3.
 18. Smith RS. Cavitory endoscopy in trauma: 2001. *Scand J Surg* 2002; 91: 67-71.
 19. Murray JA, Cornwell EE 3rd, Velmahos GC, Rivkind AI, Hedman T, Abrahams JH, et al. Healing of traumatic diaphragm injuries: comparison of laparoscopic versus open techniques in an animal model. *J Surg Res* 2001; 100: 189-91.

**บทบาทของการรักษาผู้ป่วยที่สงสัยมีการบาดเจ็บของกะบังลมปอดจากอุบัติเหตุด้วยวิธีการผ่าตัด
ผ่านกล้อง: ประสบการณ์ของโรงพยาบาลระดับตติยภูมิ**

สุภาพร โอภาสานนท์, ธวัชชัย อัครวิพุธ, กฤษณ์ แก้วโรจน์, เลิศพงศ์ สมจรรย์

ภูมิหลัง: การรักษาผู้ป่วยที่สงสัยว่ามีการบาดเจ็บของกะบังลมปอดมีความท้าทายมาก การผ่าตัดส่องกล้องอาจมีบทบาทในการ ช่วยวินิจฉัยและให้การรักษาในรายที่สงสัยการบาดเจ็บของกะบังลมปอดที่มีสัญญาณชีพปกติ

วัตถุประสงค์: เพื่อศึกษาบทบาทของการผ่าตัดด้วยกล้องในการวินิจฉัย และให้การรักษาผู้ป่วยอุบัติเหตุที่สงสัยว่าได้รับการบาดเจ็บของกะบังลมปอด ในโรงพยาบาลศิริราช

วัสดุและวิธีการ: การศึกษาข้อมูลของผู้ป่วยที่เข้ารับการรักษาที่หน่วยศัลยศาสตร์อุบัติเหตุโรงพยาบาลศิริราช ระหว่างปี พ.ศ. 2544 ถึง พ.ศ. 2551 มีผู้ป่วยอุบัติเหตุ 24 ราย ที่สงสัยว่ามีการบาดเจ็บของกะบังลมปอด มีสัญญาณชีพปกติที่ได้รับการผ่าตัดผ่านกล้อง

ผลการศึกษา: มีผู้ป่วยในการศึกษานี้ ร้อยละ 95.8 เป็นเพศชาย อายุเฉลี่ย 27.3 ปี (อายุตั้งแต่ 14-54 ปี) โดยผู้ป่วย 23 คน ได้รับการบาดเจ็บจากการถูกแทง คิดเป็นร้อยละ 95.8 มีผู้ป่วย 5 คน (ร้อยละ 20.8) มาด้วยอาการหายใจเร็ว และฟังเสียงหายใจเบาลง พบลมและเลือดในช่องอกผู้ป่วย 5 คน (ร้อยละ 20.8) ภาพถ่ายรังสีทรวงอกพบกะบังลมปอดยกตัวสูงขึ้นในผู้ป่วย 1 ราย คิดเป็นร้อยละ 4.2 พบผู้ป่วย 5 ราย (ร้อยละ 20.8) ที่ได้รับการบาดเจ็บของกะบังลมปอดจากอุบัติเหตุโดยมีเพียง 1 ราย ที่พบการบาดเจ็บของกะบังลมปอดด้านขวา ผู้ป่วยรายนี้ได้รับการซ่อมแซมกะบังลมปอดโดยการผ่าตัดส่องกล้องทางทรวงอก ไม่พบภาวะแทรกซ้อน จากการรักษาวิธีนี้ผู้ป่วยฟื้นตัวอย่างรวดเร็ว และสามารถกลับบ้านได้ภายใน 72 ชั่วโมง หลังจากการผ่าตัด

สรุป: การผ่าตัดส่องกล้องมีบทบาททั้งในแง่ของการวินิจฉัยและการรักษาในผู้ป่วยอุบัติเหตุที่สงสัยว่ามีการบาดเจ็บของกะบังลมปอด และมีสัญญาณชีพปกติ โดยเฉพาะอย่างยิ่งในผู้ป่วยที่มีการบาดเจ็บของกะบังลมปอดข้างซ้าย
