

# Preliminary Report

## Result of Full Endoscopic Uniportal Lumbar Discectomy: Preliminary Report

Verapan Kuonsongtum MD\*,  
Sompoch Paiboonsirijit MD\*\*, Withawin Kesornsak MD\*,  
Voravut Chaiyosboorana MD\*\*\*, Pataravit Rukskul MD, MSc (Clinical Science), Dr Med\*\*\*\*,  
Sorayouth Chumnanvej MD\*\*\*\*\*, Sebastian Ruetten MD, PhD\*\*\*\*\*

\* Division of Neurosurgery, Faculty of Medicine, Ramathibodi Hospital, Mahidol University, Bangkok, Thailand

\*\* Full-Endoscopic Spine Surgery Clinic, Bangkok Hospital Medical Center, Bangkok, Thailand

\*\*\* Orthopaedics Department, Royal Thai Police General Hospital, Bangkok, Thailand

\*\*\*\* Division of Neurosurgery, Faculty of Medicine, Thammasat University, Pathumthani, Thailand

\*\*\*\*\* Neurosurgical Unit, Surgery Department, Somdej Pra Pin Klao Naval Hospital,

Naval Medical Department, Royal Thai Navy, Bangkok, Thailand

\*\*\*\*\* Department for Spine Surgery and Pain Therapy, Center for Orthopaedics and Traumatology,  
St. Anna-Hospital Herne, University of Witten/Herdecke, Germany

---

**Objective:** Several techniques of minimal invasive spinal surgery are now becoming common roles in the treatment of spinal diseases in many spinal centers. In the present report, the authors present a retrospective, cohort evaluation of 46 consecutive patients who underwent full endoscopic lumbar discectomy. The purpose of the present report was to present outcomes in this initial series of patients and to present outlines of the operative technique; the full endoscopic uniportal lumbar discectomy. The present research is the first preliminary report in Thailand to analyze and evaluate this new surgical technique.

**Material and Method:** Forty-six lumbar disc herniation operations were performed in two spinal centers between February and June 2008, using the full endoscopic uniportal with Vertebris<sup>®</sup> instrumentation system. The operations were carried out by interlaminar and transforaminal approach using an 8 mm-diameter uniportal endoscopy of Vertebris<sup>®</sup> instrumentation. The outcome was clinically assessed, on immediate post-operation and one month after surgery, by using Visual Analogue Scale (VAS), the Thai Version of the modified Oswestry disability index (ODI) questionnaire (version 1.0), and modified McNab criteria.

**Results:** Excellent and good outcome was achieved in 87.4% of patients from Modified McNab criteria. Forty-three patients (93.5%) had significant improvement of sciatic pain immediately after the operation. Eight postoperative complications were demonstrated and discussed.

**Conclusion:** Full endoscopic uniportal lumbar discectomy is a novel and effective minimally invasive spinal surgical technique. However, the technique requires surgical skill training and experience.

**Keywords:** Minimally invasive surgery, Lumbar discectomy, Full endoscopic uniportal discectomy, Visual analogue scale (VAS), Thai version of modified Oswestry disability index (ODI)

*J Med Assoc Thai* 2009; 92 (6): 776-81

Full text. e-Journal: <http://www.mat.or.th/journal>

---

Several techniques of minimal invasive spinal surgery are now becoming common roles in treatment of spinal diseases in a number of spinal centers. There are many studies that have supported the accomplishment of the operative treatment of lumbar

Correspondence to: Kuonsongtum V, Division of Neurosurgery, Faculty of Medicine, Ramathibodi Hospital, Bangkok 10400, Thailand. Email: [verapan.kuonsongtum@gmail.com](mailto:verapan.kuonsongtum@gmail.com)

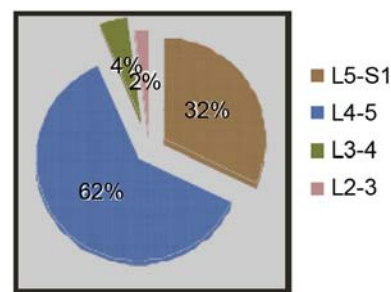
disc herniation. The estimated annual incidence of low back pain in Western countries is five cases per 1000 adults<sup>(1)</sup>. It is estimated that 70% to 80% of American adults will experience back pain at some point in their lives<sup>(2)</sup>. Back pain is the principal symptom prompting visits to orthopedic surgeons as well as neurosurgeons. About 54.8% of Thai people reported low back pain<sup>(3)</sup>. Lumbar spondylosis or degenerative lumbar disc

disease is a common cause of clinical low back pain. The outcome studies of lumbar disc surgery document an accomplishment rate between 49-90%, regarding to evaluation criteria used<sup>(4)</sup>. In recent years, the endoscopic methods have increasingly been applied in surgery, mainly spinal surgery. After the advent of advanced full endoscopic technique<sup>(5)</sup>, the most widely used for lumbar spine is the transforaminal and interlaminar approach. The advantages of this technique are less consecutive damage due to traumatization compared with the conventional disc operations, sufficient decompression under visual control and short operative time. In the present report, the authors would like to share their initial experience and review the current outcomes in posterior approach lumbar discectomy by using the full endoscopic uniportal instrument; Vertebris<sup>®</sup> instrumentation (Richard Wolf GmbH), innovated by Dr. S. Ruetten<sup>(5)</sup>. The present research is the first preliminary report in Thailand to analyze and evaluate this new surgical technique.

#### Material and Method

Between February and June 2008, the full endoscopic uniportal technique; Vertebris<sup>®</sup> instrumentation (Richard Wolf GmbH), innovated by Dr. S. Ruetten<sup>(5)</sup> was used in 46 lumbar discectomy operations in 46 patients. With the cooperation of two main spinal clinics in Bangkok, Thailand, the records of 29 consecutive patients were collected from the Division of Neurosurgery, Faculty of Medicine, Ramathibodi Hospital, and 17 consecutive patients from The Full Endoscopic Spine Surgery Clinic (FESS), Bangkok Hospital Medical Center. Forty-six operations had been performed entirely full endoscopic discectomy by using interlaminar and transforaminal approach. The group integrated 21 female and 25 male patients, aged between 21 and 58 years (averaged 42.04 years). The duration of low back pain symptoms varied from 1 to 48 months. There was one case of L2-L3 (2%), two cases of L3-L4 (4%), 29 cases of L4-L5 (62%), and 15 cases of L5-S1 (32%) level.

The authors performed two technical approaches; namely, the interlaminar approach (34 cases, 73.9%) and the transforaminal approach (12 cases, 26.1%). The patients, presented with radicular pain, unresponsive to appropriate conservative treatment for more than 3 months with progressive neurological deficit as well as lumbar MRI showed nerve root compressions, were included in the present study. All of the consecutive patients were diagnosed as sciatica pain with lumbar disc bulging or protusion.



**Fig. 1** Diagram displays the proportion of the lumbar spine levels which were collected

All of them were preoperatively considered to be operated with the full endoscopic lumbar discectomy. The pre-operative, immediate post-operative, and one-month evaluation were analyzed by using the specific outcome measurements; visual analogue scale (VAS) and Thai version of modified Oswestry disability index (ODI). Modified Macnab criteria was evaluated at 1 month post-operation.

#### Description of operative technique

##### Interlaminar approach

The operative technique was carried out in the prone position under general anesthesia from a posterior approach, identical to the mean used for microdiscectomy. The level of the spine to be operated on was verified under fluoroscopic guidance intraoperatively. A craniocaudal skin incision, 0.8 cm in length, was created at the desired level in midline through the lumbrosacral sheath then dilator insertion was done followed by the working channel probe into the intervertebral space. The localization of the interlaminar space confirmed with lateral X-ray. Next, identification of anatomical structures including lamina, the facet joint, and the interlaminar space should be verified. Before the vertebral canal is opened, spinal muscles covering the ligamentum flavum should be removed with rongeurs and coagulation. The ligamentum flavum was cut by micropunch. Then, proper clearing of the operative field, haemostasis, and examination of anatomical structures are very important. Especially repeated radiological verification of the position of the working channel probe insertion of the endoscope, are helpful. With good illumination, high magnification and visualization of structures on the screen, the surgeon could verify the anatomy and do the surgical dissection with a designed probe. Depending on anatomical conditions, if there is a

narrow interlaminar space, the adjacent lamina may be partially removed. The endoscope may be moved both along the long axis of the patient and in a lateromedial direction. The nerve root is mobilized using a probe and the rotation of the bevel tip of the working channel probe, then it is retracted medially. This is a critical moment of the operation because retraction of the nerve root requires gently and free of transposition of the nerve root. The surgeon should not explore the herniated disc before the most lateral aspect of the vertebral canal is exposed. Removal of the sequestered disc is identical to the mean using in microdiscectomy performed under the microscope exploration.

### Transforaminal approach

The operative technique is carried out under general anesthesia from a posterolateral approach, in prone position. The level of the spine to be operated on was verified under fluoroscopic guidance intraoperatively on the posterolateral side of the body. The appropriateness of spinal level set the correct direction of the endoscope in relation to the foramen. A transverse skin incision, 0.8 cm in length, was created at the desired level. The long needle was inserted posterolateral under intraoperative fluoroscopic guidance and pointed to the desired foramen. Then, the transforaminal dilator and the working channel probe were inserted respectively. Verification with anteroposterior and lateral X-ray was recommended at this step. Finally, at the foramen, the exiting nerve root was identified superiorly of the visual field and the intervertebral disc inferiorly. Removal of the sequestered disc does not differ significantly from the interlaminar approach.

### Results

According to Fig. 2, there was a significant difference between pre-operative VAS and immediate post-operative VAS ( $p < 0.05$ ). At one-month follow-up, there was a significant difference between pre-operative and one-month post-operative VAS and ODI ( $p < 0.05$ ). Forty-three patients (93.5%) had significant improvement of sciatic pain immediately after the operation. Thirty-seven patients (80.4%) showed excellent outcome and three patients (7%) were in good condition after surgery at one-month. These patients were discharged from the hospital on the second or third day after the operation. Two cases (4.3%) did not show up for postoperative follow-up and two cases (4.3%) showed fair outcome after surgery. Thirty-eight patients (82.6%) reported no post-operative complica-

tions and three of these patients (6.5%) had transient numbness postoperatively. However after a few weeks, they were completely recovered. Two patients (4.3%) had complete recovery immediately after the operation; nevertheless, they had recurrent sciatic pain one week after the operation. Both of them were investigated with MRI and large recurrent disc was revealed. They were subsequently re-operated by the full endoscopic uniportal discectomy and the VAS significantly decreased after surgery. One patient (2.2%) had persistent sciatic pain from retained disc. He underwent microdiscectomy successfully. Two patients (4.3%) had cauda equina syndrome, one from retained disc and prolonged retraction of thecal sac. Endoscopic discectomy was performed and the patient recovered. Another one was reported with dural tear and migrated nerve roots outside thecal sac. Microscopic repairing was performed and the patient recovered.

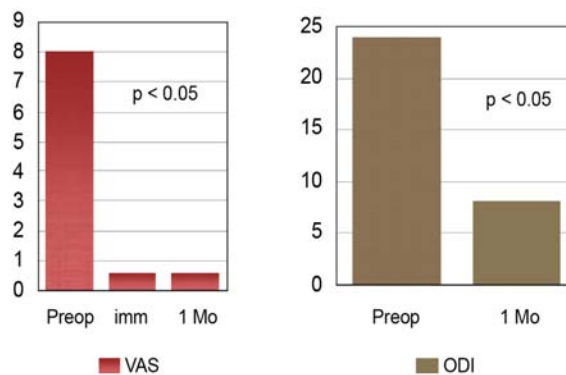


Fig. 2 Diagram displays the different of VAS and ODI between preoperation, immediate and one month postoperation

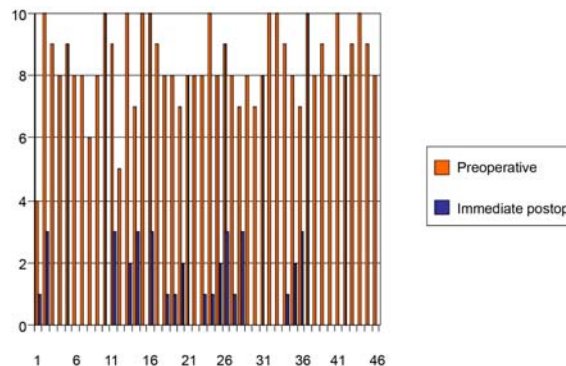
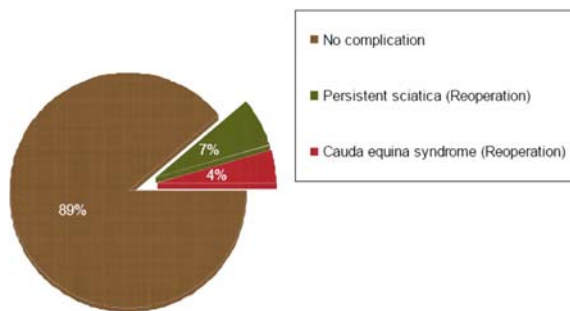


Fig. 3 Diagram displays the different of VAS between preoperation and immediate postoperation



**Fig. 4** Diagram displays the proportion of the post-operative complications

### Discussion

Full endoscopic uniportal techniques are progressively used in spine surgery, including lumbar disc full endoscopic uniportal surgery and cervical disc full endoscopic uniportal surgery<sup>(5-9)</sup>. This full endoscopic uniportal technique is the 6.9-mm in diameter percutaneous endoscopic with the rod lens optics and a 4.1-mm intraendoscopic working channel<sup>(5)</sup>. According to this technique, removal of free sequester minimizes tissue traumatization and shortens length of hospital stay. The significant concern in this full endoscopic uniportal technique is the precipitous learning curve, which means that the surgeons who performed such an operation for the first time must be fluent and recognize the specific spinal anatomy in order to avoid serious complications and improve operative safety. One study showed that it is necessary to perform about 30 microendoscopic discectomies to become competent in these procedures<sup>(10)</sup>. In the present report, the patients were operated on in two hospitals, Ramathobodi Hospital and Bangkok Hospital Medical Center, by the same surgical team. The authors reported 43 patients (93.5%) with significant improvement of sciatic pain immediately after operation with this technique. The rates of success and complication in the present report are not considerably different from the published complication rates of classic microdiscectomy even though the patients were operated on during the precipitous learning curve of the surgeons. Carragee et al reported eight cases of dural lacerations in a series of 187 operations (4.3%) and indicated that pain recurred in 22% of patients<sup>(11)</sup>. Ruetten et al reported the series of 331 patients; there were 82% having leg pain no longer, 13% having only occasional pain, and 2.4% being recurrent<sup>(5)</sup>. The authors' early

complications for interlaminar approach were caused from nerve root manipulation especially in a narrow interlaminar window. There were two cases with transient numbness and weakness. However, once the authors drilled the bone to widen the window, this problem was solved. There was one case of dural tear during retraction to the medial to find the disc fragment. The two cases of retained disc might be due to misinterpretation of the preoperative MRI image. The other case of transient numbness and weakness was from the transforaminal approach while applying the dilator. The direction was too lateral, so the dilator impacted the thecal sac. The authors instantly detected and corrected from lateral control under fluoroscopic guidance.

There were two cases of recurrent lumbar disc herniation after the first week of being symptom free. This might be from inadequate removal of intradiscal fragment, which was not from technical limitation. It depended on the surgeon's decision how much to remove of this intradiscal part.

In the authors' opinion, the full endoscopic uniportal lumbar discectomy is technically possible and adequate to solve the majority of lumbar disc herniation. Because the learning curve is steep, one should start with indicated cases, find their own limitations until this curve is done so that there are fewer complications and safer outcome.

### Conclusion

The full endoscopic uniportal technique is a novel and effective minimally invasive spinal surgical techniques. However, the technique requires surgical skill training and experience.

### References

1. Cherkin DC, Deyo RA, Loeser JD, Bush T, Waddell G. An international comparison of back surgery rates. *Spine* 1994; 19: 1201-6.
2. Frymoyer JW. Back pain and sciatica. *N Engl J Med* 1988; 318: 291-300.
3. Chaiwanichsiri D, Jiamworakul A, Jitapunkul S. Lumbar disc degeneration in Thai elderly: a population-based study. *J Med Assoc Thai* 2007; 90: 2477-81.
4. Barrios C, Ahmed M, Arroategui JI, Bjornsson A. Clinical factors predicting outcome after surgery for herniated lumbar disc: an epidemiological multivariate analysis. *J Spinal Disord* 1990; 3: 205-9.
5. Ruetten S, Komp M, Godolias G. A New full-endoscopic technique for the interlaminar operation of

- lumbar disc herniations using 6-mm endoscopes: prospective 2-year results of 331 patients. *Minim Invasive Neurosurg* 2006; 49: 80-7.
6. Ruetten S, Komp M, Merk H, Godolias G. Use of newly developed instruments and endoscopes: full-endoscopic resection of lumbar disc herniations via the interlaminar and lateral transforaminal approach. *J Neurosurg Spine* 2007; 6: 521-30.
  7. Ruetten S, Komp M, Merk H, Godolias G. A new full-endoscopic technique for cervical posterior foraminotomy in the treatment of lateral disc herniations using 6.9-mm endoscopes: prospective 2-year results of 87 patients. *Minim Invasive Neurosurg* 2007; 50: 219-26.
  8. Ruetten S, Komp M, Merk H, Godolias G. Full-endoscopic interlaminar and transforaminal lumbar discectomy versus conventional microsurgical technique: a prospective, randomized, controlled study. *Spine* 2008; 33: 931-9.
  9. Ruetten S, Komp M, Merk H, Godolias G. Full-endoscopic cervical posterior foraminotomy for the operation of lateral disc herniations using 5.9-mm endoscopes: a prospective, randomized, controlled study. *Spine* 2008; 33: 940-8.
  10. Nowitzke AM. Assessment of the learning curve for lumbar microendoscopic discectomy. *Neurosurgery* 2005; 56: 755-62.
  11. Carragee EJ, Han MY, Suen PW, Kim D. Clinical outcomes after lumbar discectomy for sciatica: the effects of fragment type and anular competence. *J Bone Joint Surg Am* 2003; 85-A: 102-8.



---

## เทคนิควิธีการผ่าตัดส่องกล้องเพื่อรักษาอาการปวดหลังจากโรคหมอนรองกระดูกสันหลังระดับเอวกดทับเส้นประสาท

วีระพันธ์ ควرتทรงธรรม, สมโภชน์ ไพบูลย์ศิริจิต, วิธวิทย์ เกสรศักดิ์, วรวิทย์ ชัยยศบูรณะ, ภัทรวิทย์ รักษากุล, สรยุทธ ชำนาญเวช, Sebastian Ruetten

**วัตถุประสงค์:** ปัจจุบันมีเทคนิคหลายวิธีในการรักษาอาการปวดหลังจากโรคหมอนรองกระดูกสันหลังระดับเอวกดทับเส้นประสาทด้วยการผ่าตัดแบบบาดเจ็บน้อย และกำลังเข้ามามีบทบาทสำคัญในการรักษาโรคของกระดูกสันหลังในหลายสถาบัน การศึกษานี้เป็นการศึกษาแบบย้อนหลัง โดยประเมินจากข้อมูลของผู้ป่วย 46 ราย ที่ได้ ทำการผ่าตัดด้วยวิธีส่องกล้องซึ่งเป็นเทคนิคใหม่ ในบริเวณกระดูกสันหลังส่วนล่าง เป้าหมายของการศึกษานี้เพื่อที่จะแสดงให้เห็นถึงประสิทธิผลการรักษา และประเมินผลของการผ่าตัด เทคนิคใหม่นี้ซึ่งเป็นการผ่าตัดแบบบาดเจ็บน้อย รายงานการศึกษานี้จะเป็นการรายงานครั้งแรกในประเทศไทยสำหรับการรักษาด้วยเทคนิคใหม่ของการผ่าตัดกระดูกสันหลังด้วยการส่องกล้อง

**วัสดุและวิธีการ:** ศึกษาผู้ป่วย 46 รายที่มีอาการหมอนรองกระดูกกดทับเส้นประสาทที่รวบรวมจาก 2 สถาบัน ในระหว่าง เดือนกุมภาพันธ์ พ.ศ. 2551 ถึงเดือนมิถุนายน พ.ศ. 2551 ซึ่งได้รับการรักษาโดยวิธีการผ่าตัดด้วยวิธีส่องกล้องระบบของ vertebrae โดยการผ่าตัดโดยผ่านเข้าทาง lamina หรือ ผ่านทางช่องของเส้นประสาทไขสันหลัง โดยใช้อุปกรณ์ผ่านเข้าขนาดเล็กที่มีความกว้างของช่องทางเข้าเพียง 8 มิลลิเมตร โดยประเมินคุณภาพการรักษาดิตตามการรักษาผู้ป่วยหลังผ่าตัดทันที และที่ 1 เดือนหลังผ่าตัดรักษาโดยใช้ Visual Analogue Scale (VAS), แบบสอบถามภาษาไทย ฉบับประยุกต์เวอร์ชัน 1.0 จาก Oswestry disability index (ODI) และ modified McNab criteria

**ผลการศึกษา:** จากการประเมินโดยการใช้ Modified McNab criteria พบว่าผลการรักษาในระดับดี และระดับดีมาก 84.7% และพบว่ามีความแตกต่างอย่างมีนัยสำคัญในการประเมินด้วย VAS และ modified ODI จากการศึกษานี้พบว่า มีภาวะแทรกซ้อนหลังผ่าตัดในผู้ป่วย 8 รายซึ่งจะได้รายงานและอภิปรายต่อไป

**สรุป:** การรักษาอาการปวดหลังจากโรคหมอนรองกระดูกสันหลังกดทับเส้นประสาทด้วยวิธีผ่าตัดส่องกล้องมีประสิทธิภาพและบาดเจ็บน้อย อย่างไรก็ตามเทคนิคใหม่นี้จำเป็นต้องใช้ระยะเวลาในการฝึกฝนทักษะเพื่อให้มีความชำนาญ และต้องการประสบการณ์ของศัลยแพทย์

---