

Incidence of Osteonecrosis from Histopathological Study Following Fracture Neck of Femur

Voranuch Thanakit MD*, Ugyen Thinley MD**,
Kiat Witoonchart MD**, Phairat Thuvasethakul MD**

* Department of Pathology, Faculty of Medicine, Chulalongkorn University, Bangkok, Thailand

** Institute of Orthopedics, Lerdsin General Hospital, Bangkok, Thailand

This prospective study was aimed to evaluate the incidence of osteonecrosis in Thai patients with fracture neck of femur. Forty-three patients who had sustained fracture were enrolled in the present study. The overall incidence of osteonecrosis was 72.1%. Incidence of osteonecrosis was 53.3% among patients who underwent surgery within 1 week after injury and 82.1% among those who underwent surgery after that time but there was no statistical difference (p -value = 0.07). Regarding displacement of fracture, the present study found the incidence of osteonecrosis was 100% among patients with undisplaced (Garden type 1 and 2) fractures and 60.0% and 76.9%, respectively among those with displaced fractures (Garden type 3 and 4). Most histological changes according to Ficat and Arlet Method of undisplaced fractures were stage 1 and 2 and the displaced fracture was stage 2. It reveals a high rate of osteonecrosis following fracture neck of femur but mostly in early reversible change. There was no significant statistical difference regarding age, duration, type of fracture, and co-morbidity.

Keywords: Osteonecrosis, Fracture neck of femur

J Med Assoc Thai 2009; 92 (6): 842-8

Full text. e-Journal: <http://www.mat.or.th/journal>

Osteonecrosis (ON) of femoral head is a condition that often leads to progressive collapse of the femoral head. It is believed to be the result of insult to blood supply to the head of femur. The causes may be either extravascular or intravascular. Largely, the causes of this condition can be divided into traumatic and non-traumatic. Osteonecrosis of the femoral head following trauma almost always involves displaced fracture of the femoral neck or hip dislocation. Following displaced fracture of the neck of femur, segmental collapse due to osteonecrosis occurs in about 16% to 30%⁽¹⁾ whereas in non-displaced fractures the risk is half that of displaced fractures. In displaced fracture of the neck of femur the incidence of osteonecrosis depends on fracture type, time until reduction and accuracy of reduction, procedure type, fixation type and surgical technique⁽¹⁻³⁾. Nevertheless, there is a wide variation in reported rates of osteonecrosis in various studies which may be caused by bias in patient

selection, variable follow-up periods and differing criteria used for diagnosis of osteonecrosis. In different studies, the authors used different methods to detect the evidence of osteonecrosis and these studies were mostly performed in patients who underwent reduction and internal fixation following the fracture. Mostly of the evaluation methods were imaging modalities which give only indirect evidence of osteonecrosis. These modalities include plain roentgenography, magnetic resonance imaging, bone scintigraphy using radioactive substances, injection of dyes, angiography^(4,5), and laser doppler study. Nevertheless, these give only the indirect evidence of osteonecrosis whereas histopathological examinations will give the direct evidence of cellular changes since injury of osteonecrosis. There are only a few studies in which histological study was done and these were performed in femoral heads obtained either from necropsy or from the operation. To the authors' knowledge there is was no such histopathological examination performed on the Thai population. So the present study was carried out to find out the incidence of osteonecrosis

Correspondence to: Thanakit V, Department of Pathology Chulalongkorn University, Bangkok 10330, Thailand. Phone: 0-2256-4235. E-mail: voranewt@yahoo.com

of femoral head following fracture of the neck of femur in elderly Thai patients who received arthroplasty. The clinical information including age, sex, the fracture type and displacement, and the duration until the treatment were also studied. The relationship between these factors and osteonecrosis was examined that may find more lines of management for elderly patients with fracture neck of femur.

Material and Method

From October 2005 to December 2006, the total of forty-three femoral heads was obtained when the arthroplasty was performed for the patients with fracture of the neck of femur. The history regarding the date of injury, co-morbidities prior to injury were obtained at the time of admission. The patients who had the history of cancer or the radiographic features suggestive of pathologic fracture were excluded from the present study. The present study was approved by the Ethics Committee of the Lerdsin General Hospital. There were 33 female patients and 10 male patients among those included in the present study. The age of the patients ranged between 53 and 94 years (mean age, 75 years). The patients were divided into two groups according to the age; Over 70, less than 70 years, and more than 70 years. The fractures were divided into four groups according to the magnitude of displacement using Garden staging of the fracture^(1,2).

The side of involved hip was noted during the collection of the femoral head. The cartilage from the inferior surface of the heads was sliced so as to help identify different quadrants-superior, inferior, lateral, medial, anterior and posterior-of the femoral heads. Microscopic examination was then done to find out the changes of osteonecrosis. When the osteonecrosis was detected the staging of the changes was done according to Ficat and Arlet method as follows^(6,7),

Stage 1 = Disappearance of the hematopoietic marrow, separation of the lipocytes by edema or hemorrhage, and presence of foam cell

Stage 2 = Necrotic of fatty marrow

Stage 3 = Medullary and trabecular necrosis

Stage 4 = Complete necrosis with dense medullary fibrosis and formation of new bone in apposition to the dead bone

Statistical analysis

The analysis was done to find out the incidence of osteonecrosis, the relationship between the incidence and the age and sex of the patients, the

incidence and the fracture type, fracture displacement and the time since injury. The regression multivariate analysis was also done to determine the effects of variables to the occurrence of osteonecrosis following fracture of the neck of femur. The SPSS version 11.5 was used for the statistical calculation. The p-value of < 0.05 was considered as statistically significant.

Results

The authors found that 31 of 43 patients (72.1%) developed osteonecrosis (Table 1). The 31 cases of osteonecrosis consisted of 23 women and 8 men, with a mean age of 75 years (range 53-94 years). Odds Ratio of female: male = 0.575 (p-value = 0.69) and the ratio is 2.75:1. No significant difference between age of patient was noted (8/11 cases for age \leq 70 years, 23/32 cases for age > 70 years) (p-value = 0.71).

According to the duration since injury that divided patients into those sustained injury one week or less before surgery and those more than one week. The authors found no significant difference in opportunity to developing osteonecrosis between the two groups when divided as time since injury (8/15 cases, 53.3% with osteonecrosis within 1 week and 23/28 cases, 82.1% with osteonecrosis more than 1 week) (p-value = 0.07), Table 2.

Each specimen with fracture displacement regarding Garden classification, Osteonecrosis was found in Type I (1/1,100%) and Type II (1/1,100%). The authors found that 9 out of 15 cases of Garden type III had osteonecrosis (60.0%) and 6 cases without evidence of osteonecrosis (40.0%). Regarding Garden type IV, 20 out of 26 cases had osteonecrosis (76.9%) and 6 cases without osteonecrosis (23.1%), Table 3.

The histological stage of osteonecrosis was examined according to fracture displacement (Garden classification). There was only one patient with Garden Type I and Type II and the histological stage was stage 1 in both patients (Fig. 1A, B). Garden Type III had 1 in 9 cases in stage 1 (11.1%), 6 in 9 cases in stage 2 (66.6%), and 2 in 9 cases in stage 3 (22.2%), (Fig. 1C). No case was found in stage 4. Garden Type IV had 4 in 20 cases in stage 1 (20%), 13 in 20 cases in stage 2 (65%), 2 in 20 cases in stage 3 (10%), and 1 in 20 cases in stage 4 (5%) (Fig. 1D, Table 4).

The co-morbidity consisted of age-related disease like hypertension and diabetes mellitus in most of the patients but there were some patients with CNS conditions who were on medications at the time of admission. The analysis of effects of various co-morbid conditions (20 out of 24 cases with underlying

Table 1. Summary of clinical information and histological finding

Pt. No.	Age (years)	Sex	Fx type	Duration since injury	Quadrant involved	Stage of ON	Underlying disease
1	83	F	IV	8	SL	2	-
2	83	M	IV	27	SL	2	HT
3	68	F	IV	3	SL, M	2	Parkinsonism
4	89	F	IV	8	SL	1	-
5	73	F	IV	8	-	-	Hyperthyroidism
6	68	F	II	12	A, S, M	2	-
7	81	F	IV	120	All	4	-
8	76	F	IV	4	-	-	-
9	53	F	III	4	-	-	Seizures
10	72	M	III	9	-	-	-
11	72	F	IV	4	-	-	-
12	77	F	III	12	SL	2	-
13	75	F	III	18	SL	2	HT
14	82	M	III	3	-	-	-
15	66	F	III	8	-	-	-
16	91	F	IV	12	SL, M	2	Dementia
17	54	M	IV	16	P, M, A	3	-
18	72	F	IV	2	SL, A	2	DM
19	73	F	IV	5	M, L	1	HT
20	66	M	IV	10	M, S	2	-
21	82	F	IV	11	SL, A	2	Psychosis
22	70	F	III	14	S, A	2	DM, HT
23	72	F	IV	17	-	-	HT
24	68	F	IV	9	M, S, A	2	-
25	76	M	III	18	S, A	3	DM
26	81	F	IV	8	SL, M	2	HT
27	65	F	III	14	SL, A, P	2	-
28	78	F	IV	2	SL	1	DM + HT
29	79	F	III	3	-	-	-
30	84	F	IV	12	S, A, M	3	HT
31	74	M	IV	6	SL, A	2	HT
32	69	F	IV	10	-	-	-
33	76	F	III	4	S, M	1	-
34	78	F	IV	13	SL, M, A	2	DM
35	75	M	III	20	SL, A	3	Psychosis
36	88	F	IV	16	S, A, M	2	Dementia
37	55	F	III	4	P, M	2	-
38	94	M	I	15	S, A, P	1	DM
39	81	F	IV	8	M	2	Epilepsy
40	87	M	III	15	S, A, P	2	-
41	86	F	III	6	-	-	DM, HT
42	69	F	IV	5	-	-	-
43	73	F	IV	5	P	1	HT

A = anterior, L = lateral, M = medial, P = posterior, S = superior, SL = superolateral

disease with osteonecrosis) and patients without underlying disease (11/20 cases with osteonecrosis) did not show any significant difference between the conditions (Chi-square = 2.96, p-value = 0.08).

When the authors looked into the area of involvement there were 26 (60.5%) femoral heads in which osteonecrosis was detected either in superolateral or superior quadrant. From the total of 43 heads,

Table 2. Relationship between age, sex, duration since injury and osteonecrosis

Patient	With osteonecrosis	Without osteonecrosis	Total (case)	
Sex				
Female	23	10	33	
Male	8	2	10	
Total	31	12	43	Odds Ratio = 0.575 95% CI: 0.10 < OR < 3.20 p-value = 0.69
Age				
≤ 70years	8	4	12	
> 70 years	23	8	31	
Total	31	12	43	Odds Ratio = 0.695 95% CI: 0.16 < OR < 2.95 p-value = 0.71
Duration				
≤ 1 week	8	7	15	
> 1 week	23	5	28	
Total	31	12	43	p-value = 0.07

Table 3. Relationship between fracture displacement and osteonecrosis

Garden type	No. of specimen	With Osteonecrosis (%)	Without Osteonecrosis (%)
I	1	1 (100)	0 (0)
II	1	1 (100)	0 (0)
III	15	9 (60.0)	6 (40.0)
IV	26	20 (76.9)	6 (23.1)

Table 4. Relationship between fracture displacement with osteonecrosis and histologic stage

Garden type	Histologic stage, case (%)			
	1	2	3	4
I	1 (100)	-	-	-
II	-	1 (100)	-	-
III	1 (11.1)	6 (66.7)	2 (22.2)	-
IV	4 (20.0)	13 (65.0)	2 (10.0)	1 (5.0)
Total (case)	6	20	4	1

17 heads had involvement of superolateral quadrant which accounts for 39.5%. Involvement of other quadrants like anterior, medial or posterior was found only in combination with the involvement of other quadrants. Isolated involvement was found only in superolateral quadrant.

Multiple regression analysis of age, sex and fracture type did not show any effect on the risk of developing osteonecrosis.

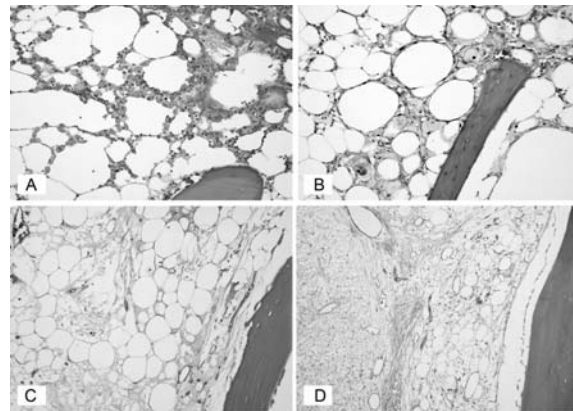


Fig. 1 (A) Stage 1: Fat cells are separated by the areas of hemorrhage and foam cells
(B) Stage 2: Necrosis of fatty marrow and separated by foam cells
(C) Stage 3: Empty of osteocyte in lacuna and necrosis of fatty marrow
(D) Stage 4: Medullary fibrosis

Discussion

In the present study the overall incidence of osteonecrosis was 72.1% (31 out of 43 cases) but for the group of patients who sustained injury more than one week the osteonecrosis rate increased to 82.1%. The incidence of osteonecrosis is marked varied in many reports. The highest incidence was 84% after displaced fracture of femoral neck⁽⁸⁾.

In the present study gender did not seem to influence the rate of osteonecrosis with any statistically significant difference but females seem to have a

slightly higher risk of osteonecrosis (2.87:1). Barnes et al⁽⁹⁾ and Gonzalez del Pino et al⁽¹⁰⁾ stated that there is more of a tendency to report osteonecrosis in female patients than in male patients.

When the effect of age was considered, there was no significant difference between the two groups (≤ 70 years and > 70 years) (p -value = 0.71). According to Catto⁽¹¹⁾, total or partial necrosis of the femoral head occurred 83% of patients at 13 days after the fracture of the neck of femur. Time since fracture is also considered to be one factor which increases the risk of developing osteonecrosis. In the present study, the authors found no statistically significant difference between the two groups of less than one week and more than one week duration after they had sustained fracture of the neck of femur. The difference was still not statistically significant and it may be because of the small sample size in the present study.

Fracture displacement is considered to be one important factor for the development of osteonecrosis. The displacement of fracture leads to direct injury or kinking of the superior retinacular vessel which supplies the upper half to 2/3 of the femoral head⁽¹²⁾ and thereby lead to osteonecrosis of the head. In the present study there was just one patient each with Garden type I and II and both these patients had evidences of osteonecrosis but the histological stage was I and 2. This result did not imply the true situation since there was a very small number of cases. Because closed reduction and internal fixation is usually the first choice of treatment for these two groups. Therefore, the heads are unavailable for histological examination. While the Garden type III had osteonecrosis 60.0% and increase to 76.9% in Garden type IV.

Most surgeons believe that the closed reduction and internal fixation is the procedure of choice in younger patients (less than 65 years) with displaced fractures (Garden III or IV). For patients over eighty years old with Garden III or IV fractures, almost all surgeons prefer arthroplasty. Opinions of surgeons vary widely in their preference for the treatment of patients between 65 and 80 years old with displaced fractures^(9,13,14). The risk of increased need for the second surgery because of high rate of osteonecrosis and non-union is the reason for surgeons to prefer arthroplasty for the elderly patients with displaced fractures^(10,13). In another study, Haidukewych et al⁽¹⁵⁾ found that the osteonecrosis was the main reason for the conversion to total hip arthroplasty even in patients between the ages 15 years and 50 years after internal fixation of the fracture of the neck of femur.

The incidence of revision surgery after displaced femoral neck fractures treated with internal fixation varies between 20% and 36%, avascular necrosis being responsible for 11% to 19%⁽¹⁶⁾. Traumatic osteonecrosis of the femoral head represents the most common femoral head osteonecrosis. The etiology of traumatic osteonecrosis is due to ischaemia as a result of blood flow interruption. According to Kenzora et al⁽⁵⁾, the term avascular necrosis should be reserved exclusively for this post traumatic group. The upper half to upper 2/3 of the femoral head is supplied by the lateral epiphyseal artery which is a terminal branch of medial circumflex femoral artery. The branches run along the Weitbrecht's retinaculum at the neck of femur⁽¹⁶⁾. Displacement of the fracture of the neck of femur less than half the greater diameter of the head results in severe disruption in the retinacular vessels resulting in osteonecrosis⁽¹⁷⁾. Angiographic studies, laser doppler hemodynamic studies and studies using injection techniques supported the theory of this low intramedullary blood flow. In our study, 17 heads out of 43 (39.5%) had involvement of superolateral quadrant and 26 out of 43 (60.5%) femoral heads had evidences of osteonecrosis either in superolateral or superior quadrant which corresponds to the area supplied by lateral retinacular branch of medial circumflex femoral artery.

The classic histological change is pending on time, most of femoral heads exhibit fibrin and hemorrhage within 24 hours after injury. Foamy macrophages in damaged marrow, loss of lipocytes nuclei occurred about the fourth day after fracture. Osteocyte death is slower and usually discerned about 2 weeks afterwards. It had complete loss about three or four weeks⁽⁹⁾. The necrosis of hematopoietic marrow, total loss of lipocytes of fatty marrow, necrotic of marrow blood vessels, and complete absence of cellular reaction, and osteocytes loss are indicated of ischemic process. These changes are also concordant to Ficat and Arlet histological staging of osteonecrosis. To avoid the under diagnosis of osteonecrosis from identification of dead bone, the initial identified necrosis of hematopoietic cells and fat cells is assessed. It was claimed that the replacement by foamy macrophages was an early reversible change but bone necrosis is an irreversible change⁽¹⁸⁾. According to the present result, each case from selected cases of the Garden Type I showed histological stage I (100%) and Garden type II showed histological stage II (100%) which demonstrated the early change of osteonecrosis. However, this sample size is very small. The majority

change of Garden type III and type IV was stage 2 (66% and 60%, respectively) while the medullary and trabecular necrosis (histological stage 3) was 22% and 15% in type III and type IV, respectively.

The co-morbidities of the patients were the chronic conditions of elderly patients and there was no significant difference in the rate of osteonecrosis between the groups.

In conclusion, the present study found that the rate of osteonecrosis in the elderly Thai population following fracture neck of femur was about 72.1% which is close to the European reports⁽⁹⁾. Delay in treatment more than one week increased the rate of osteonecrosis to 82.1%. Considering the high rate of osteonecrosis and the risk of non-union, which was not considered in the present study, an arthroplasty may be better than the internal fixation for this group of patients as treatment of choice for fracture of the neck of femur.

The strength of the present study is that the authors used direct evidence of cellular changes of osteonecrosis for the diagnosis. It is the first such study of the Thai population and one of the few studies available in the literature. Gender, age, time since injury, and type of fracture does not have any significant influence osteonecrosis.

References

1. Leighton RK. Fractures of the neck of the femur. In: Bucholtz RW, Heckman JD, Court-Brown C, editors. Rockwood and Green's fractures in adults. 6th ed. Philadelphia: Lippincott Williams & Wilkins; 2005: 1784-6.
2. LaVelle DG. Fractures of hip. In: Canale ST, editor. Campbell's operative orthopaedics. 9th ed. Philadelphia: Mosby; 1998: 2918-9.
3. Bachiller FG, Caballer AP, Portal LF. Avascular necrosis of the femoral head after femoral neck fracture. Clin Orthop Relat Res 2002; 87:109.
4. Brunner S, Christiansen J, Kristensen JK. Arteriographic prediction of femoral head viability in medial femoral neck fractures. Acta Chir Scand 1967; 133: 449-54.
5. Kenzora JE, Steele RE, Yosipovitch ZH, Glimcher MJ. Experimental osteonecrosis of the femoral head in adult rabbits. Clin Orthop Relat Res 1978; 8:46.
6. Kim YH, Kim JS. Histologic analysis of acetabular and proximal femoral bone in patients with osteonecrosis of the femoral head. J Bone Joint Surg Am 2004; 86-A: 2471-4.
7. Ficat RP, Arlet J. Treatment of bone ischemia and necrosis. In: Hungerford DS, editor. Ischemia and necrosis of bone. Baltimore: Williams and Wilkins; 1980: 171-82.
8. Lowell JD. Results and complications of femoral neck fractures. Clin Orthop Relat Res 1980; 162:72.
9. Barnes R, Brown JT, Garden RS, Nicoll EA. Subcapital fractures of the femur. A prospective review. J Bone Joint Surg Br 1976; 58: 2-24.
10. Gonzalez dP, Knapp K, Gomez CF, Benito M. Revascularization of femoral head ischemic necrosis with vascularized bone graft: a CT scan experimental study. Skeletal Radiol 1990; 19: 197-202.
11. Catto M. A histological study of avascular necrosis of the femoral head after transcervical fracture. J Bone Joint Surg Br 1965; 47: 749-76.
12. Trueta J, Harrison MH. The normal vascular anatomy of the femoral head in adult man. J Bone Joint Surg Br 1953; 35-B: 442-61.
13. Bhandari M, Devereaux PJ, Tornetta P 3rd, Swiontkowski MF, Berry DJ, Haidukewych G, et al. Operative management of displaced femoral neck fractures in elderly patients. An international survey. J Bone Joint Surg Am 2005; 87: 2122-30.
14. Raaymakers EL. Fractures of the femoral neck: a review and personal statement. Acta Chir Orthop Traumatol Cech 2006; 73: 45-59.
15. Haidukewych GJ, Rothwell WS, Jacofsky DJ, Torchia ME, Berry DJ. Operative treatment of femoral neck fractures in patients between the ages of fifteen and fifty years. J Bone Joint Surg Am 2004; 86-A: 1711-6.
16. Arnoldi CC, Linderholm H, Mussbichler H. Venous engorgement and intraosseous hypertension in osteoarthritis of the hip. J Bone Joint Surg Br 1972; 54: 409-21.
17. Lu-Yao GL, Keller RB, Littenberg B, Wennberg JE. Outcomes after displaced fractures of the femoral neck. A meta-analysis of one hundred and six published reports. J Bone Joint Surg Am 1994; 76: 15-25.
18. Vigorita VJ, Ghelman B. Osteonecrosis. In: Vigorita VJ, editor. Orthopaedic pathology. Philadelphia: Lippincott Williams & Wilkins; 1999: 490-99.

อุบัติการณ์เกิดกระดูกตายโดยการตรวจทางฮิสโตโลยีหลังกระดูกหักบริเวณคอกระดูกพีเมอร์

วรรณช ธนาภิจ, อุแก่น ทินเลย์, เกียรติ วิฑูรชาติ, ไพรัช ฤๅเศรฐกุล

วัตถุประสงค์ของการศึกษาไปข้างหน้านี้เพื่อหาอัตราการเกิดกระดูกตายในผู้ป่วยไทยที่หักกระดูกพีเมอร์ตายหลังกระดูกหักบริเวณคอของพีเมอร์ ผู้ป่วยที่ทำการศึกษาจำนวน 43 คนที่เกิดกระดูกหักบริเวณคอของพีเมอร์มีอุบัติการณ์การเกิดกระดูกตาย 72.1% พบอัตราหักกระดูกตาย 53.3% ในผู้ป่วยที่กระดูกหักและผ่าตัดในช่วง 1 สัปดาห์ หรือ ก่อนหน้านั้นและเป็น 82.14% ในผู้ป่วยที่ได้รับการผ่าตัดหลัง 1 สัปดาห์ แต่ไม่มีความแตกต่างอย่างมีนัยสำคัญ ($p\text{-value} = 0.07$) รายงานนี้พบอัตราการเกิดกระดูกตาย 100% ในผู้ป่วยที่กระดูกหักแต่ไม่เคลื่อนที่ (Garden ชนิด 1 และ 2) พบ 60.0% และ 76.9% ในผู้ป่วยที่กระดูกหักและเคลื่อนที่ (Garden ชนิด 3 และ 4) ฮิสโตโลยีที่พบส่วนมาก ของหักกระดูกที่ตายอ้างอิงตามวิธี Ficat and Arlet ของกระดูกที่หักแต่ไม่เคลื่อนที่ เป็นระยะที่ 1 และ 2 ส่วนของกระดูกที่หักและเคลื่อนที่เป็นระยะที่ 2 การศึกษานี้พบอัตราการเกิดกระดูกตายในอัตราที่ค่อนข้างสูง แต่การเปลี่ยนแปลงส่วนใหญ่เป็นระยะเริ่มต้นซึ่งอาจกลับเป็นปกติได้ ไม่พบความแตกต่างอย่างมีนัยสำคัญเมื่อทำการศึกษาแยกตามอายุ, ระยะเวลาที่เกิดอุบัติเหตุจนถึงวันผ่าตัด, ชนิดการหักของกระดูกและโรคที่เกิดร่วม
