

Tissue Imprint for Intra-operative Evaluation of Musculoskeletal Tumors

Taweechok Wisanuyotin MD*, Jumpol Mitchai MD**,
Winai Sirichativapee MD*, Weerachai Kosuwon MD*,
Chat Sumnanoont MD*, Polasak Jeeravipoolvarn MD*

* Department of Orthopaedics, Faculty of Medicine, Khon Kaen University, Khon Kaen, Thailand

** Department of Pathology, Faculty of Medicine, Khon Kaen University, Khon Kaen, Thailand

Objective: To evaluate the usefulness of an intra-operative tissue imprint as a role to provide a provisional diagnosis in patients with musculoskeletal tumors.

Material and Method: 118 patients underwent surgical treatment for musculoskeletal tumors. Tissue imprints from suspected tissues were conducted in all of the patients and the results were compared with the final permanent section.

Results: The usefulness of the imprint slides (i.e., the diagnostic yield) was 88.14%. The respective, overall sensitivity, specificity, accuracy, positive and negative predictive value was 93.75%, 100%, 96.15%, 100% and 90.90%.

Conclusion: Tissue imprinting is a useful method for intra-operative evaluation of adequacy and provides a provisional diagnosis of the musculoskeletal tumors lesions.

Keywords: Bone neoplasms, Cytodiagnosis, Musculoskeletal tumors, Intra-operative period

J Med Assoc Thai 2009; 92 (5): 654-9

Full text. e-Journal: <http://www.mat.or.th/journal>

Intra-operative diagnosis is one of the important steps in the management of patients with musculoskeletal tumors in order to ensure the tissue taken from the lesion can be diagnosed and to prevent the need for further biopsy. Frozen sections have been used for these aims but that method has some disadvantages such as time, expense and unavailability at some hospitals⁽¹⁾.

Tissue imprint preparation has been used extensively for diagnosis of many tumors such as breast cancer, lymph node metastasis and thyroid nodules⁽²⁻¹⁰⁾. It has many advantages such as its being a simple procedure, less expensive and faster than frozen section procedure. The disadvantage is it is more difficult to interpret than frozen section for non-cytology-trained pathologists⁽⁹⁾. The respective accuracy, sensitivity and specificity of tissue imprint method is similar to a frozen section⁽⁶⁾.

Correspondence to: Wisanuyotin T, Department of Orthopaedics, Faculty of Medicine, Khon Kaen University, Khon Kaen 40002, Thailand. Phone: 043-348-398, E-mail: tawwis@kku.ac.th

To the authors' knowledge, the usefulness of tissue imprint method for intra-operative evaluation of musculoskeletal tumors has not been reported. The authors, therefore, performed this present study in order to assess the usefulness of tissue imprint method for intra-operative evaluation of musculoskeletal tumors, in particular with diagnostic accuracy and yield.

Material and Method

A prospective study was performed in 118 consecutive patients with bone or soft tissue tumors of the extremities who were to have biopsies. All of the patients had been treated at the Musculoskeletal Tumors Clinic, Srinagarind Hospital, Khon Kaen University between April 2006 and September 2007.

All of the patients had been operated for either incisional or excisional biopsy. If the specimen was large enough to be bisected, the cut surface of the tumor was imprinted on two glass slides. In cases where small amounts of tissue were obtained, all of the tissue was touched to the glass slides. The slides were fixed in 95% alcohol then stained by Hematoxylin and Eosin.

The specimens were also sent for permanent section procedure to establish the final diagnosis. The imprint slides and the permanent sections were analyzed by one musculoskeletal pathologist (JM) to compare the reading result between the tissue imprint and the final histopathology regarded as the gold standard.

The imprint slides were reported as diagnosable or non-diagnosable. A non-diagnostic slide meant that there was inadequate tissue for evaluation (*i.e.*, no cell or only red blood cells seen). In a diagnostic slide, the benign or malignant lesions were classified.

Statistical analysis

The usefulness of the imprint slides (*i.e.*, the diagnostic yield) was: [the number of patients whose diagnostic slides could be analyzed / the total number of patients] x 100%.

Among the diagnostic slides, the diagnostic accuracy (*i.e.*, sensitivity, specificity, positive and negative predictive value) were all calculated.

Results

Among the 118 patients (55 males and 63 females), the mean age was 32.29 years (range, 4 to 77). A definite diagnosis of benign lesions occurred in 47 patients over against malignant lesions in 71 patients (Table 1).

There were diagnostic slides for 104 of the 118 patients; thus, the diagnostic yield was 88.14%. Of the 14 cases in the non-diagnostic slides group, the causes of non-diagnosis were acellular or hypocellular (13 cases; 3 osteosarcomas, 3 liposarcomas, 2 infection and a case each of plasma myeloma, lipoma, schwannoma, myxoma and chondroblastoma) and hemorrhage background (1 case of aneurysmal bone cyst).

There was agreement between the imprint slides and the final diagnosis in 100 cases (*viz.*, 60 true positives and 40 true negatives) (Table 2). In 4 of the false negatives, the imprint slides were classified as benign but the respective final diagnosis was

Table 1. Tissue imprint results and final histopathology diagnoses of the 118 patients

Malignant	Number	Diagnostic slides		Non-diagnostic slides
		Correct	Incorrect	
Bone				
Osteosarcoma	23	17	3	3
Chondrosarcoma	2	2		
Metastasis	26	26		
PNET	2	2		
Lymphoma	3	3		
Plasma myeloma	3	1	1	1
Chordoma	1	1		
MFH	2	2		
Soft tissue				
Liposarcoma	4	1		3
Rhabdomyosarcoma	1	1		
Synovial sarcoma	3	3		
Leiomyosarcoma	2	2		
Aneurysmal bone cyst	3	2		1
Giant cell tumor	13	13		
Infection/Inflammation	12	10		2
Fibrous dysplasia	2	2		
Chondroblastoma	2	1		1
Soft tissue				
Lipoma	1	1		
Schwannoma	4	3		1
Fibromatosis	2	2		
Synovial chondromatosis	1	1		
Hemangioma	4	4		
Giant cell tumor of tendon sheath	1	1		
Myxoma	1			1

Table 2. Summary of the result of diagnostic imprint slide related to the final diagnosis

	Final pathological report	
	Malignant	Benign
Diagnostic slide		
Malignant	60	0
Benign	4	40
Non-diagnostic slide	7	7

malignant (*i.e.*, 3 osteosarcomas and one case of plasma myeloma). There were no false positives.

The respective overall sensitivity, specificity, accuracy, positive and negative predictive value was 93.75%, 100%, 96.15%, 100% and 90.90%.

Discussion

Tissue imprint preparation is the study of the cytology of tumors achieved by touching the specimen to a glass slide. This method is widely used for intra-operative diagnosis for many types of soft tissue tumors as it has a high sensitivity and specificity (*i.e.*, between 80 and 100 percent⁽²⁻¹⁰⁾). In musculoskeletal tumors, however, a cytological study has been limited to only aspiration cytology and used in the pre-operative period for diagnostic purposes⁽¹¹⁻¹⁵⁾. In the present study, the authors used imprint cytology as a method for intra-operative diagnosis of musculoskeletal tumors because it is safer and faster than the conventional frozen section method.

Ghandur-Mnaymneh and Paz⁽⁴⁾ reported the use of tissue imprint for rapid intra-operative diagnosis of metastatic lymph node disease. They found that tissue imprint method had an accuracy of 99% compared to 98.7% for a frozen section. They recommended that tissue imprint method replace the conventional frozen section technique and be used as the sole method of rapid intra-operative diagnosis of metastatic lymph node disease.

Shah et al⁽¹⁵⁾ reported the respective diagnostic yield of the frozen section and fine needle aspiration of musculoskeletal tumors was 93.4% and 85.71%. Rikard Wedin et al⁽¹³⁾ studied the cytological diagnosis of skeletal lesions in 110 patients based on fine needle aspiration biopsy and reported a diagnostic yield of 93%.

In the present study, the diagnostic yield was 88.14% as 14 of the 118 patient imprint slides (11.86%)

could not be evaluated because of inadequate tissue. The main reason for having a non-diagnostic slide was insufficient cells (in 13 of 14 cases), which may be because of insufficient pressure being applied while imprinting the specimen on the glass slide or because of morphological heterogeneity of the musculoskeletal tumors^(1,11) and thus the biopsied material was not representative.

The authors excluded the non-diagnostic slides before calculating diagnostic accuracy. The

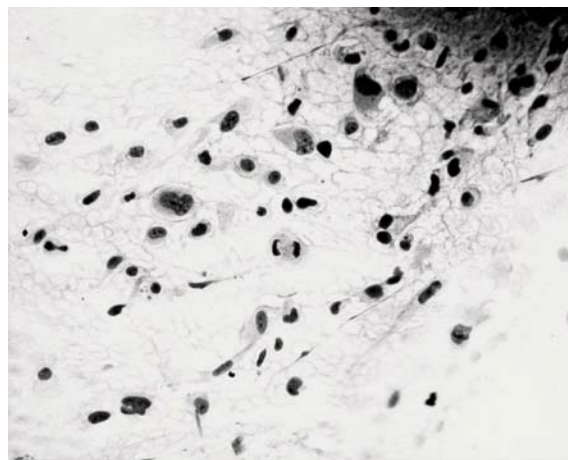


Fig. 1 Imprint of osteosarcoma of bone shows mesenchymal cells with prominent atypia and mitotic figures (Hematoxylin and eosin x400)

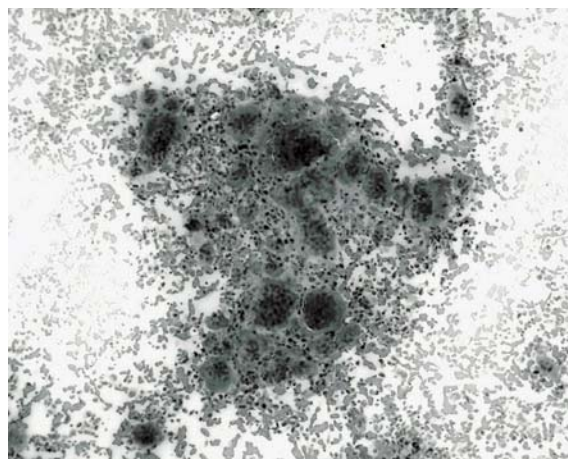


Fig. 2 Imprint of giant cell tumor of bone shows coherent cell clusters of multinucleated giant cells and dispersed single cells. The multinucleated giant cells contain a variable number of nuclei with benign appearances (Hematoxylin and eosin x400)

authors found no false positive which suggests that a diagnosis of malignancy by the tissue imprint method is reliable. There were 4 cases of false negatives (3.85%) in 3 cases of osteosarcoma and 1 case of plasma myeloma. In all 4 cases, only benign cells were found in the imprint slides. The reason for these false negatives may be sampling errors.

The overall accuracy rate in the present study was 96.15% which is similar to other studies⁽¹¹⁻¹⁷⁾. The overall sensitivity and specificity were 93.75% and 100%

which compares favorably with the frozen section method^(1,15). In the present study, however, the authors did not directly compare between the tissue imprint and frozen section method. The high specificity of the tissue imprint method in the present study was similar to other reports using cytology diagnosis which had 100% specificity for a malignant diagnosis^(14,17).

In diagnostic slides, despite a clear cytological morphology (Fig. 1-6), the authors could not give an exact diagnosis as per the specific type of bone and



Fig. 3 Imprint of fibromatosis shows proliferating of fibroblasts with uniform, elongated nuclei and inconspicuous nucleoli (Hematoxylin and eosin x100)

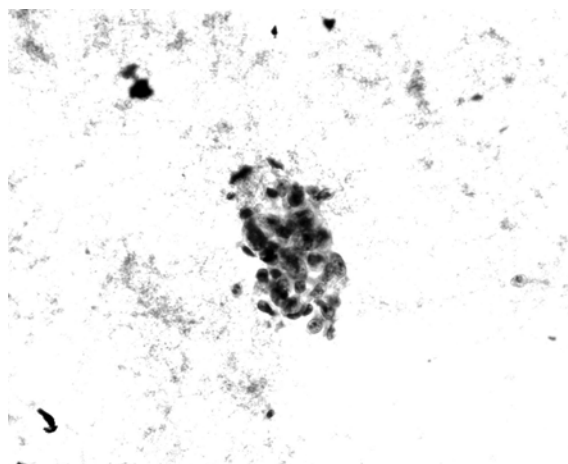


Fig. 4 Imprint of metastatic adenocarcinoma shows a cluster of atypical, pleomorphic tumor cells with irregular nuclei and prominent nucleoli (Hematoxylin and eosin x400)

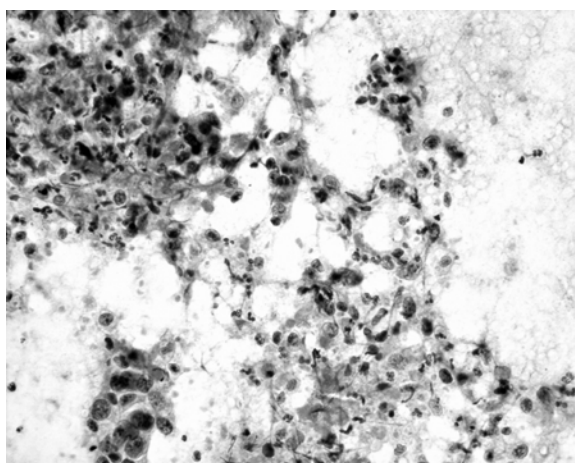


Fig. 5 Imprint of metastatic adenosquamous carcinoma show atypical, pleomorphic tumor cells with epithelial features, irregular nuclei and prominent nucleoli (Hematoxylin and eosin x400)

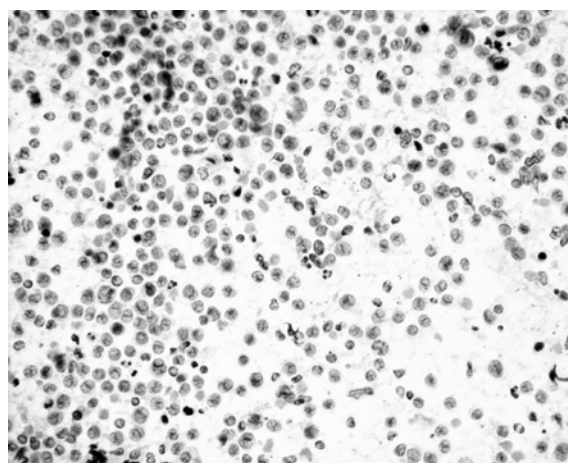


Fig. 6 Imprint of round cell neoplasm shows malignant cells with single round nuclei, evenly dispersed chromatin and inconspicuous nucleoli. Mitotic figures are present (Hematoxylin and eosin x400)

soft tissue tumors. The present study classified the diagnostic imprint slide as either benign or malignant since only the cells could be seen and the authors did not do an immunohistochemistry study.

To establish the diagnosis of malignancy, the malignant cells must be found as described by Tribe⁽⁵⁾ and one or more of the following criteria identified: (i) the cells must be larger than benign cells, (ii) pleomorphism, (iii) increase nuclear-cytoplasmic ratio, (iv) numerous or prominent nucleoli and (v) mitoses. However, to identify all of these findings accurately, an experienced musculoskeletal pathologist is needed⁽⁹⁾.

In the present study, the authors found that it was difficult to provide the provisional diagnosis of some specific type of malignancy such as in liposarcoma, osteosarcoma and plasma myeloma. So in these suspected cases, frozen section should be used in conjunction with tissue imprint to enhance the efficiency of intra-operative evaluation⁽¹⁰⁾.

The tissue imprint method has some advantages over the frozen section in that it is less time-consuming and is cost-reducing. In the present study, it took under 5 minutes to complete the imprint slide compared to the 20 minutes required to do the frozen section method. The cost of the frozen section method is also greater than the tissue imprint method (1600 Baht vs. 60 Baht.)

Another advantage of the tissue imprint method has to do with the small fragments of tissue obtained. With this method, the specimens were not lost as in the frozen sections procedure and could be preserved for a permanent section.

In summary, the tissue imprint method is useful for intra-operative diagnosis of musculoskeletal tumors. The authors can use this method to check the adequacy of specimens, provide rapid, accurate, reliable and provisional diagnosis, suitable for the current economic status.

Acknowledgments

The authors wish to thank the Faculty of Medicine, Khon Kaen University for its support and Mr. Bryan Roderick Hamman for assistance with the English-language presentation.

References

1. Ashford RU, McCarthy SW, Scolyer RA, Bonar SF, Karim RZ, Stalley PD. Surgical biopsy with intra-operative frozen section. An accurate and cost-effective method for diagnosis of musculoskeletal sarcomas. *J Bone Joint Surg Br* 2006; 88: 1207-11.
2. Ademiluyi SA, Akinyanju OO, Mordi VP. Evaluation of lymph node imprint in rapid diagnosis of lymph node biopsy specimens. *J Clin Pathol* 1986; 39: 688-9.
3. Hahn PF, Eisenberg PJ, Pitman MB, Gazelle GS, Mueller PR. Cytopathologic touch preparations (imprints) from core needle biopsies: accuracy compared with that of fine-needle aspirates. *Am J Roentgenol* 1995; 165: 1277-9.
4. Ghandur-Mnaymneh L, Paz J. The use of touch preparations (tissue imprints) in the rapid intra-operative diagnosis of metastatic lymph node disease in cancer staging procedures. *Cancer* 1985; 56: 339-44.
5. Tribe CR. Cytological diagnosis of breast tumours by the imprint method. *J Clin Pathol* 1965; 18: 31-9.
6. Suen KC, Wood WS, Syed AA, Quenville NF, Clement PB. Role of imprint cytology in intra-operative diagnosis: value and limitations. *J Clin Pathol* 1978; 31: 328-37.
7. Stewart CJ, Coldewey J, Stewart IS. Comparison of fine needle aspiration cytology and needle core biopsy in the diagnosis of radiologically detected abdominal lesions. *J Clin Pathol* 2002; 55: 93-7.
8. Deo S, Samaiya A, Jain P, Asthana S, Anand M, Shukla NK, et al. Sentinel lymph node biopsy assessment using intraoperative imprint cytology in breast cancer patients: results of a validation study. *Asian J Surg* 2004; 27: 294-8.
9. Perez N, Vidal-Sicart S, Zanon G, Velasco M, Santamaria G, Palacin A, et al. A practical approach to intraoperative evaluation of sentinel lymph node biopsy in breast carcinoma and review of the current methods. *Ann Surg Oncol* 2005; 12: 313-21.
10. Orki A, Tezel C, Kosar A, Ersev AA, Dudu C, Arman B. Feasibility of imprint cytology for evaluation of mediastinal lymph nodes in lung cancer. *Jpn J Clin Oncol* 2006; 36: 76-9.
11. Kreicbergs A, Bauer HC, Brosjo O, Lindholm J, Skoog L, Soderlund V. Cytological diagnosis of bone tumours. *J Bone Joint Surg Br* 1996; 78: 258-63.
12. Howard CB, Einhorn M, Dagan R, Yagupski P, Porat S. Fine-needle bone biopsy to diagnose osteomyelitis. *J Bone Joint Surg Br* 1994; 76: 311-4.
13. Wedin R, Bauer HC, Skoog L, Soderlund V, Tani E. Cytological diagnosis of skeletal lesions. Fine-needle aspiration biopsy in 110 tumours. *J Bone Joint Surg Br* 2000; 82: 673-8.
14. El Khoury GY, Terepka RH, Mickelson MR, Rainville KL, Zaleski MS. Fine-needle aspiration

- biopsy of bone. J Bone Joint Surg Am 1983; 65: 522-5.
15. Shah MS, Garg V, Kapoor SK, Dhaon BK, Gondal R. Fine-needle aspiration cytology, frozen section, and open biopsy: relative significance in diagnosis of musculoskeletal tumors. J Surg Orthop Adv 2003; 12: 203-7.
16. Yao L, Nelson SD, Seeger LL, Eckardt JJ, Eilber FR. Primary musculoskeletal neoplasms: effectiveness of core-needle biopsy. Radiology 1999; 212: 682-6.
17. Carrino JA, Khurana B, Ready JE, Silverman SG, Winalski CS. Magnetic resonance imaging-guided percutaneous biopsy of musculoskeletal lesions. J Bone Joint Surg Am 2007; 89: 2179-87.

การตรวจชิ้นเนื้อในขณะผ่าตัดเนื้องอกระบบโครงร่างด้วยวิธี tissue imprint

ทวีโชค วิชาญโยธิน, จุมพล มิตรชัย, วินัย ศิริชาติวาปี, วีระชัย ไควสุวรรณ, ชัช สุมนานนท์, พลศักดิ์ จีระวิพลวรรณ

วัตถุประสงค์: เพื่อต้องการประเมินผลการตรวจชิ้นเนื้อในขณะผ่าตัดเนื้องอกระบบโครงร่าง ด้วยวิธี tissue imprint ว่าสามารถบอกลักษณะของเนื้องอกที่เพียงพอต่อการวินิจฉัยเบื้องต้นได้หรือไม่

วัสดุและวิธีการ: ผู้ป่วยเนื้องอกระบบโครงร่าง 118 คน ซึ่งได้รับการผ่าตัดนำชิ้นเนื้อออกมาตรวจ ได้รับการตรวจโดยวิธี tissue imprint เพื่อดูว่าชิ้นเนื้อที่ได้นั้นเพียงพอต่อการวินิจฉัยหรือไม่ และสามารถบอกการวินิจฉัยเบื้องต้นได้หรือไม่ โดยนำผลที่ได้จากวิธี tissue imprint เทียบกับวิธีตรวจมาตรฐานทางพยาธิวิทยา

ผลการศึกษา: การตรวจด้วยวิธี tissue imprint สามารถอ่านผลได้ 88.14%, ความไว 93.75%, ความจำเพาะ 100%, ความถูกต้อง 96.15%, positive predictive value 100%, negative predictive value 90.90%

สรุป: การตรวจชิ้นเนื้อในขณะผ่าตัดเนื้องอกระบบโครงร่างด้วยวิธี tissue imprint มีประโยชน์ สามารถนำมาใช้ในการประเมินดูว่าชิ้นเนื้อที่ได้นั้นเพียงพอต่อการวินิจฉัยหรือไม่ และสามารถบอกการวินิจฉัยเบื้องต้นได้โดยมีความถูกต้องและแม่นยำสูง สามารถทำได้เร็วและประหยัด