

Case Report

Primary Torsion of the Greater Omentum: Report of a Case

Sathon Thum-Ummuaysuk MD*

*Department of Surgery, Faculty of Medicine, Naresuan University, Phitsanulok, Thailand

This is a case report of primary omental torsion that occurred in a 21-year-old man who presented with right lower quadrant abdominal pain. His provisional diagnosis was appendicitis. He was explored for appendicitis but the finding was twisted omentum.

Keyword: Omentum, Torsion abnormality

J Med Assoc Thai 2009; 92 (5): 691-3

Full text. e-Journal: <http://www.mat.or.th/journal>

Omental torsion is a rare disease and there is no published medical report in Thailand. This can mimic other conditions and rarely be diagnosed before surgery. This paper presents a case of right lower quadrant pain that was finally diagnosed as torsion of the omentum. A review of the literature about this condition was also included.

Case Report

A 21-year-old Thai male patient presented with abdominal pain for four days. The pain was constant and localized at the right lower quadrant of the abdomen. He had no nausea or vomiting. He had a good appetite, normal bowel habit, and no urinary symptom. One day prior to admission, the pain progressed and he was brought to the hospital. He denied the history of trauma or heavy exertion after meals. His blood pressure was stable. He had no fever. Abdominal examination revealed tenderness and guarding at RLQ with positive Rovsing sign. He had normal bowel sound. Rectal examination revealed no abnormality. The complete blood count showed leukocytosis with neutrophil predominant. Urinary analysis was normal. He was provisionally diagnosed with appendicitis. After discussion, he underwent appendectomy. The exploration was done through a right lower transverse incision. There was the necrotic

mass of twisted, ischemic omentum with narrow pedicle at the right lower side of abdomen (Fig. 1). The appendix was normal. There was no Meckel diverticulum, intraperitoneal fluid, or any adhesion band. The patient recovered with no complication. He was discharged on day 3. The pathologic results were hemorrhagic infarction of the omentum (Fig. 2). The appendix was normal

Discussion

Torsion of the omentum is the condition, in which the organ twists on its long axis causing impaired blood supply. This is a rare condition, fewer than 300 cases being reported in the English literature with the first in 1899 by Eitel^(1,2). This condition is male predominant. Most patients are middle-aged adults with one literature reported the age between 41.3 + 16.8 years⁽³⁾. It is classified as primary and secondary. Primary or idiopathic torsion of the omentum is a rare condition, without any other coexisting condition. Secondary torsion is more common and is associated with abdominal pathology. The most common pathology is inguinal hernia. Other causes include tumors, cysts, internal or external herniation, foci of intraabdominal inflammation, and post surgical wounds or scarring⁽⁴⁾. Primary omental torsion is unipolar, where one end of the omentum remains fixed while the other end is free. In contrast, secondary omental torsion is bipolar with the free end attached either to adhesions or to some pathological conditions⁽³⁾. The cause of primary omental torsion is obscure but there are several

Correspondence to: Thum-Ummuaysuk S, Department of Surgery, Faculty of Medicine, Naresuan University, Phitsanulok 65000, Thailand. Phone: 055-261-900 ext. 5018, Fax: 055-261-923

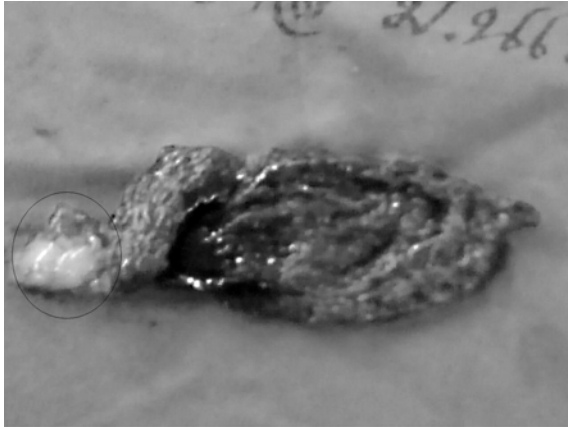


Fig. 1 Omental infarction: circle shows point of torsion

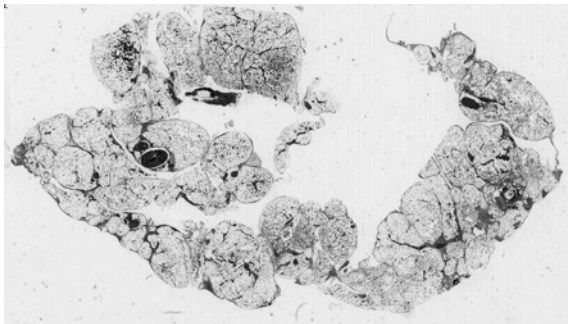


Fig. 2 Pathological finding: Hemorrhagic infarction of the omentum

predisposing and precipitating factors. The predisposing factors can be anatomical variation of the omentum including tongue like projections from free edge of the omentum, bifid omentum, accessory omentum, and obesity associated with irregular distribution of fat within the omentum, and narrow omental pedicle^(4,5). Another factor is venous redundancy relative to the omental arterial blood supply, allowing venous kinking and offering a fixation point around which an omental segment can twist⁽⁵⁾. The precipitating factors include local trauma, occupational vibration associated omental damage, and conditions that induce omental displacement, such as hyperperistalsis following a heavy meal, change in body position, increased intra-abdominal pressure resulting from heavy exercise, coughing, sneezing or excessive straining^(5,6).

The torsion is usually in a clockwise direction. At first, venous return is compromised and the distal omentum becomes congested and edematous.

Hemorrhagic extravasation leads to an accumulation of serosanguineous fluid in peritoneal cavity, which was not found in the present case. After that, arterial occlusion leads to acute hemorrhagic infarction and omental necrosis⁽⁴⁾. There is a previous report that omental torsion can be spontaneously reduced⁽⁷⁾.

The majority of omental torsions are located at the right side of the abdomen. This may be because the right side of the omentum is longer, heavier, and more mobile than the left side⁽⁸⁾. Left side torsion is extremely rare. In most cases, the omental torsion occurs in the greater omentum but one literature has reported that omental torsion can occur in the lesser omentum⁽⁸⁾.

The diagnosis of omental torsion is rarely made preoperatively. The accuracy rate of preoperative diagnosis is about 0.6-4.8%⁽⁴⁾. This may be due to non-specific symptoms. The most frequent presentation is pain at the right iliac fossa⁽¹⁾. The pain is sudden, constant, non-radiating, and gradually progressive in severity. Some patients had a history of repeated abdominal pain suggesting recurrent torsion. Pain may be localized to other parts of the abdomen such as epigastrium or left lower quadrant depending on the location of the affected segments. Nausea, vomiting, and anorexic symptoms are uncommon presentations, being less than 50% of the cases. Body temperature may be normal or slightly elevated. The mass can be palpated in 1/3 of the patients. One-third to one-half of the patients had leukocytosis.

The differential diagnosis of omental torsion includes acute appendicitis, acute cholecystitis, cecal diverticulitis, and appendagitis. Sigmoid diverticulitis and appendagitis are the differential diagnosis for left side omental torsion. Imaging study may be performed to rule out other conditions of abdominal pain. In omental torsion, ultrasonography reveals focal area of increase echogenicity in the omentum. Computed tomography scan may show findings such as, a whirling mass of fatty and fibrous tissue around a vascular pedicle, a spiral fat pattern, a fatty mass with a whirling pattern, a circumscribed fatty mass with hyperattenuated streaks, a concentric distribution of fibrous folds⁽⁹⁾.

Treatment of torsion of omentum is resection of the affected segment. Patients undergoing surgical resection rapidly recover and have little or no morbidity. Conservative treatment has been reported in some literatures, being recommended after working up by imaging evaluation to rule out other pathologies. However, since there is a necrotic tissue left in the

abdominal cavity, these patients require prolonged use of analgesia due to persistent pain and some patients may suffer from other complications such as abscess formation⁽¹⁰⁾.

Thus, omental torsion can be recognized in the patient that presents with right lower quadrant pain with good appetite and no gastrointestinal symptoms. Serosanguineous fluid may not be present in torsion omentum.

References

1. Loh MH, Chui HC, Yap TL, Sundfor A, Tan CE. Omental infarction-a mimicker of acute appendicitis in children. *J Pediatr Surg* 2005; 40: 1224-6.
2. Eitel GG. Rare omental torsion. *NY Med Rec* 1899; 55: 715-6.
3. Karayiannakis AJ, Polychronidis A, Chatzigianni E, Simopoulos C. Primary torsion of the greater omentum: report of a case. *Surg Today* 2002; 32: 913-5.
4. Kargar S, Fallahnejad R. Primary torsion of the lesser sac omentum. *The Internet Journal of Surgery* [serial on the Internet]. 2006 [cited 2009 Feb 3]; 7(2):1-4. Available from: <http://www.ispub.com/ostia/index.php?xmlFilePath= journals/ijsvol7n2/omentum.xml>
5. Jeganathan R, Epanomeritakis E, Diamond T. Primary torsion of the omentum. *Ulster Med J* 2002; 71: 76-7.
6. Naffaa LN, Shabb NS, Haddad MC. CT findings of omental torsion and infarction: case report and review of the literature. *Clin Imaging* 2003; 27: 116-8.
7. Sarac AM, Yegen C, Aktan AO, Yalin R. Primary torsion of the omentum mimicking acute appendicitis: report of a case. *Surg Today* 1997; 27: 251-3.
8. Hirano Y, Oyama K, Nozawa H, Hara T, Nakada K, Hada M, et al. Left-sided omental torsion with inguinal hernia. *World J Gastroenterol* 2006; 12: 662-4.
9. Tamamoto F, Ishizaki H, Takanashi T, Shimoji K, Okamura T, Yoshimura T, et al. Omental torsion with right-sided inguinal hernia. *Radiat Med* 2005; 23: 566-9.
10. Helmrath MA, Dorfman SR, Minifee PK, Bloss RS, Brandt ML, DeBaakey ME. Right lower quadrant pain in children caused by omental infarction. *Am J Surg* 2001; 182: 729-32.

Primary torsion of the greater omentum : รายงานผู้ป่วย 1 ราย

สธน ธรรมอำานวยสุข

รายงานผู้ป่วย *primary omental torsion* ในผู้ป่วยชายไทยอายุ 21 ปี มาโรงพยาบาลด้วย อาการปวดท้องด้านขวาล่าง หลังจากซักประวัติ ตรวจร่างกาย และส่งตรวจเลือดและ ปัสสาวะแล้วแพทย์ให้การวินิจฉัยว่าเป็นไส้ติ่งอักเสบจึงได้นำผู้ป่วยไปผ่าตัดเพื่อนำไส้ติ่งออก แต่ผลปรากฏว่าไส้ติ่งปกติและพบว่ามีการ หมุนบิดตัวของ *omentum* บริเวณช่องท้องด้านขวาล่าง ได้ทำการรักษาโดยการตัด *omentum* ส่วนที่บิดตัวและไส้ติ่งออก