

# Case Report

## Non-Hodgkin Lymphoma with Adrenal Insufficiency: A Case Report and Literature Review

Tada Kunavisarut MD\*,  
Wanee Nitiyanant MD\*, Sorranart Muangsomboon MD\*\*,  
Trongtum Tongdee MD\*\*\*, Noppadol Siritanratkul MD\*\*\*\*

\* Division of Endocrinology and Metabolism, Department of Medicine, Faculty of Medicine Siriraj Hospital, Mahidol University, Bangkok, Thailand

\*\* Department of Pathology, Faculty of Medicine Siriraj Hospital, Mahidol University, Bangkok, Thailand

\*\*\* Department of Radiology, Faculty of Medicine Siriraj Hospital, Mahidol University, Bangkok, Thailand

\*\*\*\* Division of Hematology, Department of Medicine, Faculty of Medicine Siriraj Hospital, Mahidol University, Bangkok, Thailand

---

A 62-year-old Thai man was admitted because of nausea and vomiting with incidentally detected bilateral adrenal enlargement. The basal cortisol was low and ACTH level was elevated. CT guided percutaneous needle biopsy of adrenal gland showed a diffuse infiltration of medium to large atypical lymphoid cells of B-cell immunophenotype, which are diagnostic for a diffuse large B-cell lymphoma. Involvement by large B-cell lymphoma was documented in bone marrow biopsy as well. The findings confirmed the diagnosis of primary adrenal insufficiency caused by large B-cell lymphoma involving both adrenal glands.

**Keywords :** Lymphoma, Non-Hodgkin, Adrenal Insufficiency

**J Med Assoc Thai 2009; 92 (5): 687-90**

**Full text. e-Journal:** <http://www.mat.or.th/journal>

---

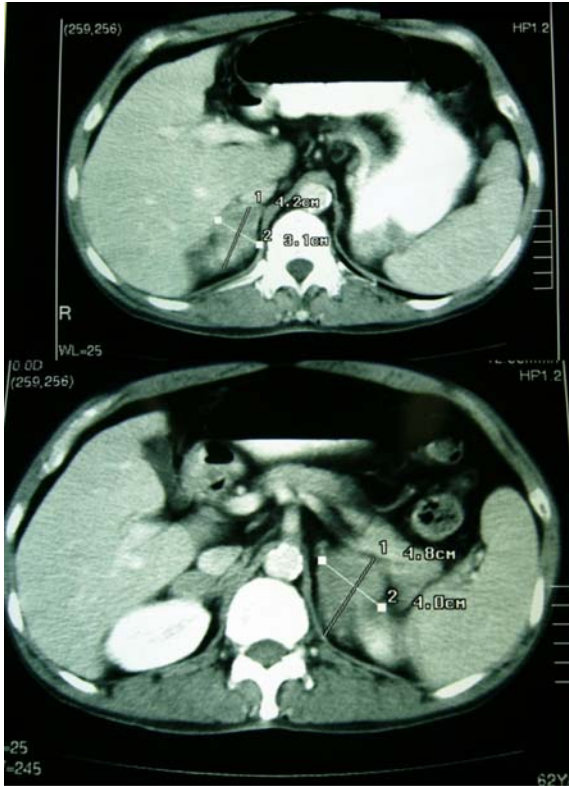### Case Report

A 62-year-old man was admitted because of nausea, vomiting, and bilateral adrenal mass. The patient was well until approximately one year ago, when he was found to have hypertension. Amlodipine 5 mg/day was started but discontinued several months later. One month prior to admission, he had abdominal discomfort, nausea, and was admitted to a local hospital. He had un-estimated weight loss in last 3 months. The laboratory work-up from local hospital showed AST 92 U/L, ALT 67 U/L, alkaline phosphatase 122 U/L, serum Na 108 mEq/L, K 4.5 mEq/L, Cl 87 mEq/L, and CO<sub>2</sub> 20 mEq/L. An ultrasound of the abdomen revealed a diffuse increased echogenicity of liver parenchyma and a well-defined hypochoic lesion size 3 x 3.2 x 3.4 cm between spleen and left upper pole of kidney. A computed tomography (CT) of the abdomen showed well defined smooth contour irregular enhancing hypodense mass in both suprarenal regions, 4.1 x 3.1 cm

on the right side and 4.8 x 4.0 cm on the left side, without calcification (Fig. 1). No intra-abdominal lymphadenopathy was detected. Chest X-ray revealed right hilar adenopathy, but no definite pulmonary infiltration. He smoked cigarettes 2 packs/day for 30 years. He had a history of heavy alcohol drinking for 30 years. He denied usage of herbal medicine. His father had lung cancer. His mother had hypertension and diabetes. On physical examination, his body temperature was 37°C, the pulse 80 beats/minute, and respiratory rate 18 breaths/minute. The blood pressure was 110/80 mmHg on supine and 100/75 mmHg upon sitting. He looked well and was in no acute distress. There was no increased pigmentation of the skin. Few patches of hyperpigmentation were found at right buccal mucosa. No cushingoid appearance was detected. There was no palpable lymph node. He had clubbing of fingers. The heart and lungs were normal. The abdomen was flat without palpable mass. His complete blood count revealed hemoglobin 12.4 g/dL, hematocrit of 35.8%, white blood cell count of 5.6 x 10<sup>9</sup>/L with 72% PMN; 12% lymphocytes; 10% monocytes;

---

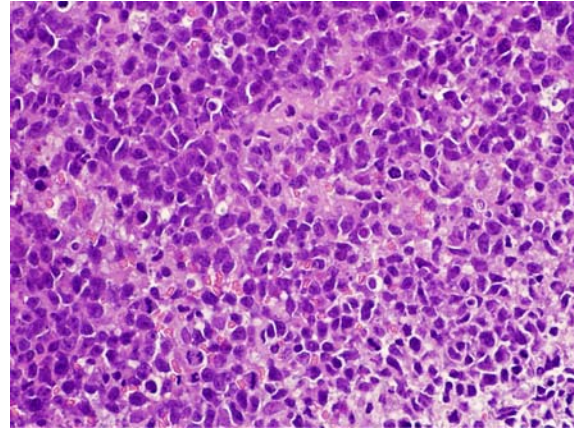
Correspondence to: Kunavisarut T, Division of Endocrinology and Metabolism, Department of Medicine, Faculty of Medicine Siriraj Hospital, Mahidol University, Bangkok 10700, Thailand.



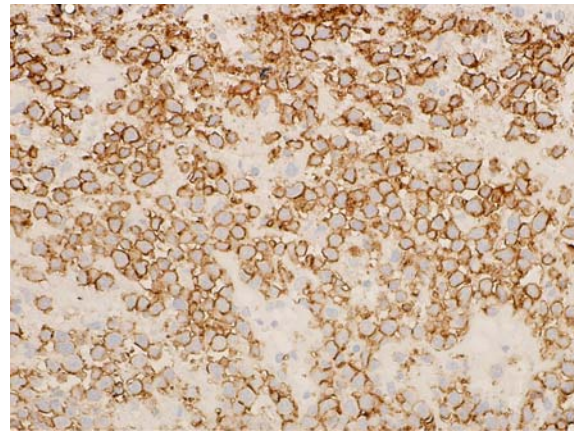
**Fig. 1** Computed tomographic scan of abdomen showing masses in both adrenal glands

6% eosinophils and platelet count of  $153 \times 10^9/L$ . The blood chemistries showed Na 124 mEq/L, K 5 mEq/L, Cl 93 mEq/L,  $CO_2$  22 mEq/L, BUN 6 mg/dL, Cr 0.7 mg/dL, plasma glucose 105 mg/dL, AST 46 U/L, ALT 38 U/L, GGT 155 U/L, alkaline phosphatase 89 U/L, albumin 3.9 g/dL, globulin 2.8 g/dL, total bilirubin 1 mg/dL, direct bilirubin 0.1 mg/dL, and LDH 501 U/L.

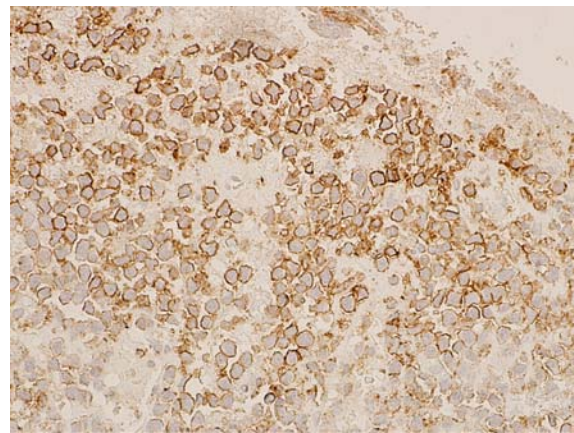
Morning serum cortisol at 8.00 a.m was 2.5 mcg/dL (8-28 mcg/dL). A 250 mcg ACTH stimulation test was done. The serum cortisol level at 0, 30, and 60 minutes were 2.58, 5.24, 2.37 mcg/dL, respectively. Basal ACTH level was 229.1 pg/mL (10-60 pg/mL). CT guided percutaneous needle biopsy of the left adrenal gland showed a diffuse infiltration of medium to large atypical lymphoid cells (Fig. 2), which were CD20+ (Fig. 3); CD45+ (Fig. 4) but CD3 -, AE1/AE3 - and TTF-1. The staining for mycobacterium and fungus of the adrenal gland were negative. The bone marrow biopsy showed four lymphoid aggregates with few medium to large lymphoid cells among small lymphoid cells. Immunostaining for CD20 demonstrated



**Fig. 2** Histologic appearance of biopsy specimen of the adrenal gland showing infiltration of medium to large atypical lymphoid cells (H&E stain, x600)



**Fig. 3** Positive CD20 staining of malignancy cells (x600)



**Fig. 4** Positive CD45 staining of malignancy cells (x600)

a small number of large B-cells admixed with many small B-cell. The contrast-enhanced CT chest revealed an enlarged right hilar adenopathy size 1.4 x 1.2 cm. Following hydrocortisone replacement therapy, his clinical condition and laboratory improved. Rituximab, cyclophosphamide, doxorubicin, vincristine, and prednisolone were started.

### Discussion

The patient was found to have bilateral adrenal mass in the process of work up for gastrointestinal symptoms. His clinical features and laboratory findings indicated the presence of primary adrenal insufficiency. Adrenal masses are found in 3.4% of individuals undergoing abdominal computed tomography (CT)<sup>(1)</sup>. In these patients, adenomas accounted for 41%, metastasis 19%, adrenocortical carcinoma 10%, myelolipoma 9%, pheochromocytoma 8%, and other lesions comprise the remainder<sup>(2)</sup>. Bilateral adrenal masses are found in about 10-15% of cases of adrenal incidentaloma. When the masses are bilateral, the likely diagnosis include metastatic disease, congenital adrenal hyperplasia, lymphoma, infection (e.g., tuberculosis, fungal), hemorrhage, ACTH dependent Cushing's syndrome, and pheochromocytoma<sup>(2)</sup>.

Redman et al<sup>(3)</sup> found that metastatic disease from lung and breast was common primary cancers. In the present study, 33% of patients with radiologic evidence of bilateral adrenal metastasis had adrenal insufficiency as confirmed by the cosyntropin stimulation test. Destruction of approximately 90% of the adrenal cortex is necessary before adrenal insufficiency becomes apparent<sup>(4)</sup>.

Approximately 10-25% of cases with non-Hodgkin lymphoma have an extranodal in origin<sup>(5)</sup>. There are two types of adrenal involvement in lymphoma, the primary adrenal lymphoma (PAL) which defined as disease arising in, and confined to the adrenal glands only<sup>(6)</sup> and non-Hodgkin lymphoma with adrenal involvement. Adrenal insufficiency is common in bilateral primary adrenal non-Hodgkin lymphoma, occurring in half of the reported cases. PAL is an extremely rare disease. Seventy cases have been reported in the English literature<sup>(7)</sup>. A diagnosis of PAL should be considered in a patient presenting with bilateral adrenal masses without nodal and other organ involvement<sup>(8)</sup>. Diagnosis of PAL did not fit with the presented patient since he had hilar lymphadenopathy and bone marrow involvement by malignant lymphoma.

Non-Hodgkin lymphoma with adrenal involvement occurs in 4% of cases assessed by CT. In most of the patients, lymphoma are diffuse rather than nodular<sup>(9)</sup>. At postmortem examination, 24.9% of the lymphoma patients have lymphoma at adrenal gland<sup>(10)</sup>. Adrenal involvement in patients with non-Hodgkin lymphoma may present at the time of initial assessment and usually occur in advanced disease and elderly<sup>(11)</sup>. In addition, adrenal involvement by lymphoma usually associated with retroperitoneal lymph node as well as ipsilateral kidney involvement<sup>(12,13)</sup>. In contrast to PAL, clinical and biochemical evidence of adrenal insufficiency is rare<sup>(14)</sup>. Gamelin et al reported in 1991 that adrenal insufficiency might be underestimated in patients with non-Hodgkin lymphoma. The authors found that eight out of 127 patients (6.3%) with non-Hodgkin lymphoma had adrenal enlargement. The involvement was bilateral in five cases. A clinical primary adrenal insufficiency confirmed by endocrine function test affects four of the five patients with bilateral adrenal involvement<sup>(15)</sup>. Seidenwurm et al suggested that patients with adrenal metastatic lesions require immediate replacement therapy to avoid the catastrophic consequences of Addisonian crisis<sup>(16)</sup>. Chemotherapy remained the main treatment in non-Hodgkin lymphoma patients. Some case reports have described the recovery of adrenal function after chemotherapy<sup>(17)</sup>.

The authors concluded that this patient had an uncommon clinical presentation of diffuse large B-cell lymphoma stage IVA with bilateral adrenal involvement and primary adrenal insufficiency.

### References

1. Herrera MF, Grant CS, van Heerden JA, Sheedy PF, Ilstrup DM. Incidentally discovered adrenal tumors: an institutional perspective. *Surgery* 1991; 110: 1014-21.
2. Nawar R, Aron D. Adrenal incidentalomas-a continuing management dilemma. *Endocr Relat Cancer* 2005; 12: 585-98.
3. Redman BG, Pazdur R, Zingas AP, Lored R. Prospective evaluation of adrenal insufficiency in patients with adrenal metastasis. *Cancer* 1987; 60: 103-7.
4. Kung AW, Pun KK, Lam K, Wang C, Leung CY. Addisonian crisis as presenting feature in malignancies. *Cancer* 1990; 65: 177-9.
5. Rudders RA, Ross ME, DeLellis RA. Primary extranodal lymphoma: response to treatment and factors influencing prognosis. *Cancer* 1978;

- 42:406-16.
6. Ellis RD, Read D. Bilateral adrenal non-Hodgkin's lymphoma with adrenal insufficiency. *Postgrad Med J* 2000; 76: 508-9.
  7. Kumar R, Xiu Y, Mavi A, El Haddad G, Zhuang H, Alavi A. FDG-PET imaging in primary bilateral adrenal lymphoma: a case report and review of the literature. *Clin Nucl Med* 2005; 30: 222-30.
  8. Choi CH, Durishin M, Garbadawala ST, Richard J. Non-Hodgkin's lymphoma of the adrenal gland. *Arch Pathol Lab Med* 1990; 114: 883-5.
  9. Paling MR, Williamson BR. Adrenal involvement in non-Hodgkin lymphoma. *AJR Am J Roentgenol* 1983; 141: 303-5.
  10. Rosenberg SA, Diamond HD, Jaslowitz B, Craver LF. Lymphosarcoma: a review of 1269 cases. *Medicine (Baltimore)* 1961; 40: 31-84.
  11. Levy NT, Young WF Jr, Habermann TM, Strickler JG, Carney JA, Stanson AW. Adrenal insufficiency as a manifestation of disseminated non-Hodgkin's lymphoma. *Mayo Clin Proc* 1997; 72: 818-22.
  12. Pagliuca A, Gillett DS, Salisbury JR, Basu RN, Mufti GJ. Bilateral adrenal lymphoma presenting as Addison's disease. *Postgrad Med J* 1989; 65: 684-6.
  13. Glazer HS, Lee JK, Balfe DM, Mauro MA, Griffith R, Sagel SS. Non-Hodgkin lymphoma: computed tomographic demonstration of unusual extranodal involvement. *Radiology* 1983; 149: 211-7.
  14. Park CK, Miller C, Lawrence G. Addison's disease from non-Hodgkin's lymphoma with normal-size adrenal glands. *J Clin Oncol* 2007; 25: 2322-4.
  15. Gamelin E, Beldent V, Rousselet MC, Rieux D, Rohmer V, Ifrah N, et al. Non-Hodgkin's lymphoma presenting with primary adrenal insufficiency. A disease with an underestimated frequency? *Cancer* 1992; 69: 2333-6.
  16. Seidenwurm DJ, Elmer EB, Kaplan LM, Williams EK, Morris DG, Hoffman AR. Metastases to the adrenal glands and the development of Addison's disease. *Cancer* 1984; 54: 552-7.
  17. Carey RW, Harris N, Kliman B. Addison's disease secondary to lymphomatous infiltration of the adrenal glands. Recovery of adrenocortical function after chemotherapy. *Cancer* 1987; 59: 1087-90.

---

## โรคมะเร็งต่อมน้ำเหลืองและต่อมหมวกไตพร้อมชนิดปฐมภูมิ: รายงานผู้ป่วย 1 ราย

ธาดา คุณาวิศรุต, วรณิ นิธิยานันท์, สรนาท เมืองสมบุรณ์, ตรงธรรม ทองดี, นพดล ศิริธนารัตนกุล

ชาย อายุ 62 ปี มีอาการคลื่นไส้ อาเจียน และการตรวจทางรังสีวินิจฉัยพบต่อมหมวกไต 2 ข้างมีขนาดโตขึ้น ผลตรวจทางห้องปฏิบัติการพบว่าระดับ คอर्टิซอลในเลือดต่ำ และระดับคอर्टิโคโทรปินสูงกว่าปกติ การตรวจชิ้นเนื้อจากต่อมหมวกไตพบมะเร็งต่อมน้ำเหลืองชนิดบีเซลล์ ซึ่งยืนยันด้วยการย้อมอิมมูโนฮิสโตเคมี การตัดไขกระดูกมาตรวจพบมะเร็งต่อมน้ำเหลืองชนิดเดียวกัน การตรวจทั้งหมดบ่งชี้ว่าเป็นมะเร็งต่อมน้ำเหลืองที่แพร่กระจายไปยังต่อมหมวกไตทั้ง 2 ข้าง และทำให้เกิดต่อมหมวกไตพร่องฮอร์โมนชนิดปฐมภูมิ