

# Core Out Fistulectomy, Anal Sphincter Reconstruction and Primary Repair of Internal Opening in the Treatment of Complex Anal Fistula

Paiboon Jivapaisarnpong MD\*

\* Division of Colorectal Surgery, Department of Surgery, Rajavithi Hospital, College of Medicine, Rangsit University, Bangkok, Thailand

---

**Objective:** To determine the surgical technique “core out fistulectomy with anal sphincter reconstruction and primary closure of internal opening” in the treatment of trans-sphincteric fistula (high type or long tract) or supra-sphincteric fistula in terms of fistula healing, morbidity, recurrence and anal continence.

**Material and Method:** Between January 2004 and December 2005, 33 patients were enrolled in the present study. There were 30 males and 3 females with median age 42 (range 19-73) years. Most patients were high trans-sphincteric type (94%). The patients who had intersphincteric fistula, short tract trans-sphincteric fistula, fecal incontinence, or anal sphincter impairment were excluded.

**Results:** The median operative time was 35 (range 20-90) minutes. Median follow up was 14 (range 6-20) months. The median healing time was 4 weeks (range: 2 to 5 weeks) with minimal disturbance over patient life. There was one postoperative perianal hematoma treated by nonoperative mean and four cases of recurrent fistulas (cured by second operation) with no continence disturbance noted during the follow-up period.

**Conclusion:** Core out fistulectomy with anal sphincter reconstruction and primary closure of internal opening is an effective procedure to be considered in the treatment of trans-sphincteric fistula (high type or long tract) with a satisfactory result while preserving both internal and external sphincters.

**Keywords:** Anal canal, Fecal incontinence, Reconstructive surgical procedures, Rectal fistula, Surgical flaps, Surgery

*J Med Assoc Thai* 2009; 92 (5): 638-42

Full text. e-Journal: <http://www.mat.or.th/journal>

---

The main principles of management of anal fistula are closure of internal opening of fistula tract, drainage of infection or necrotic tissue, and eradication of fistulous tract with preservation of sphincter function<sup>(1)</sup>. The appropriate type of surgery (simple fistulotomy, fistulectomy, seton placement, advancement flap, fibrin glue or anal plug) is determined by the course of the fistula tracts and continence status. Most of the anal fistulas have been conventionally treated by either fistulotomy or fistulectomy, which have proven to be effective<sup>(2)</sup>. In trans-sphincteric fistula (high type or long tract), fistulotomy, or fistulectomy create an extensive surgical anal wound and need sphincterotomy, which can produce fecal incontinence

in varied degree. The seton technique is a complicated procedure and prolonged healing time<sup>(3)</sup>, fibrin glue, and anal plug are new techniques that need further evaluation of their effectiveness. Nowadays sphincter-saving procedure is popularized due to minimal complication and no functional detriment<sup>(4)</sup>. Core out fistulectomy<sup>(5,6)</sup> combining anal sphincter reconstruction and primary repair of internal opening is one of sphincter saving procedures that need no sphincterotomy so minimal risk of fecal incontinence and short period of wound care are obtained.

## Material and Method

Between January 2004 and December 2005, 33 consecutive patients with high trans-sphincteric (n = 31) and suprasphincteric (n = 2) fistulas undergoing “core out fistulectomy with anal sphincter reconstruction

Correspondence to: Jivapaisarnpong P, Division of Colorectal surgery, Department of Surgery, Rajavithi Hospital, Rajavithi Rd, Rajathevi, Bangkok 10400, Thailand.

and primary closure of internal opening” were included in a prospective study. Thirty males and three females with a median age of 42 (range 19-73) years were included. Clinical outcome was assessed in terms of fistula healing, morbidity, recurrence, and anal continence.

#### **Exclusion criteria**

Intersphincteric type fistula, superficial or short tract of trans-sphincteric type, impaired anal sphincter, or fecal incontinence.

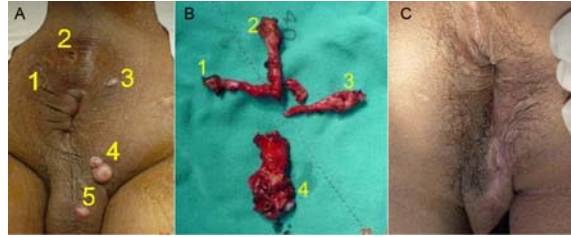
#### **Definition**

- Primary closure of internal opening may be performed by direct appositional suture, anorectal mucosal flap, endorectal advancement flap (full flap), or anocutaneous flap.
- Anal sphincter reconstruction: 2 layers closure of internal sphincter and external sphincter defect.
- Core out fistulectomy or partial fistulectomy

#### **Surgical technique**

The operation was performed under regional anesthesia, in the prone jackknife position. Betadine was routinely injected through the external opening to identify the internal opening. If the internal opening or fistula tract could not be identified and in case of suspected secondary tract, with anal sinus, methylene blue was used to mark the tract.

The external opening was circumscribed and dissected along with fistulous tract by either electric cautery or Metzenbaum scissors. The dissection was carried down deep through the external anal sphincter and internal anal sphincter as far as possible. Then anorectal mucosa flap was developed in a U-shape by mobilized 3 to 4 cm proximally with the apex of the flap just distal to dentate line including internal opening of the fistula (in some cases, the internal opening were excised directly without flap). The internal opening of the fistula was dissected to join the previous dissected fistulectomy tube, and all of the fistulous tract was removed. The anal wound was closed layer by layer. External anal sphincter and internal anal sphincter were closed with interrupted absorbable sutures. The tip of the flap containing the fistulous opening was excised, then the flap was advanced and sutured to the anoderm below the level of the internal opening (simple appositional suture of the anal wound in cases without flap). The perianal skin wound was opened for drainage.



**Fig. 1** Core out fistulectomy case  
A) anal fistula with 5 external openings and 3 internal openings  
B) specimens  
C) complete healing

#### **Results**

There were 30 (91%) men and three (9%) women with a median age of 42 years (range 19-73 years). The common anal fistula type was high trans-sphincteric fistula in 31 patients with deep postanal abscess in two patients and two patients were suprasphincteric fistula. The age distribution and male predominance (90%) seen in this series are similar to most other series<sup>(2,7)</sup>. There was one external opening and tract in 23 (70%) patients, two in seven (21%) and multiple in three (9%) (Fig. 1). In nine (29%) of the 31 patients in the trans-sphincteric group and in one (50%) of the two patients in the suprasphincteric group had more than one external opening and tract. The internal opening was located at dentate line in all.

Anorectal mucosal flap closure of internal opening was undergone in 21 cases, and the remaining 12 cases were closed by simple appositional suture (without flap). The median operative time was 35 (range 20-90) minutes. One patient developed post-operative perianal hematoma successfully treated by conservative treatment without other complications.

The median follow up duration was 14 (range 6-20) months. The median healing time was 4 weeks (range 2-5 weeks). There were no fecal incontinence but anal fistula recurred in four cases. None healing fistula with persistent anal discharge developed in two patients due to suture line dehiscence or wound infection. Two patients recurred at 5 and 7 weeks later due to missed diagnosis of secondary tract and deep post anal abscess. The recurrent cases were more common in simple appositional closure of internal opening than anorectal advancement flap closure that occurred in three (75%) of total four cases. In recurrent cases, two patients underwent repeat same surgical technique and the other two patients therapy were

changed to drainage seton treatment. All of these patients were healed.

### Discussion

Fistulotomy or fistulectomy is a common procedure performed by most surgeons. Low type of anal fistula responds well to these techniques. However, management of complicated anal fistula with fistulotomy or fistulectomy and the cutting-seton technique, which divides a portion of the internal sphincter and external anal sphincter, have been reported a high rate of incontinence and prolonged healing time.

Aguilar et al (1985)<sup>(8)</sup> has advocated preservation of the sphincter muscle by extrasphincteric

fistulectomy, closure of the sphincteric defect, and endorectal mucosal advancement flap closure of internal opening. The purpose of this technique is to close the internal opening, thus prevent the egress of contamination from the rectum. If the internal opening can be healed, the fistula will heal. He reported the recurrence rate in 1.5% of 189 patients with 10% deterioration in anal continence. After that, many authors reported a good result of success rate 75-95% and the recurrence rate of 1-30% (Table 2).

This technique has a fairly high initial recurrence rate due to surgical wound infection that an abscess can reform and disrupt the suture line, causing a recurrence of the fistula, so it is important to ensure adequate drainage of the fistula through the

**Table 1.** Demographics of anal fistula's patients

Characteristics	Value	
Age:	Median 42 years (range 19-73 years)	
Gender:	Male 30, female 3	
External opening:	Single opening	23 patients
	Two openings	7 patients
	Multiple openings	3 patients
Type :	Transsphincteric type	31 patients
	- multiple / horseshoe type	10 patients
	- with perianal abscess in	2 patients
	Suprasphincteric type	2 patients
Location of internal opening:	Anterior	11 patients
	Posterior	22 patients

**Table 2.** Results of endorectal advancement flap

Author	Patients (n)	Success %	Recurrence %	Incontinence %	Follow-up (months)
Aguilar et al <sup>(8)</sup> 1985	189	ns	1.5	10	8 m-7 yr
Acanthasiadis et al <sup>(12)</sup> 1994	224	ns	10.7	21	1-7.5 yr
Ozuner et al <sup>(13)</sup> 1996	101	94	29	ns	12
Grolub et al <sup>(14)</sup> 1997	164	ns	3.28	ns	ns
Tocacelli et al <sup>(15)</sup> 1997	36	ns	8.2	0	ns
Miller et al <sup>(6)</sup> 1998	26	77	ns	0	ns
Schouten et al <sup>(16)</sup> 1999	44	75	23	35	12
Ortiz et al <sup>(5)</sup> 2000	103	93	ns	8	12
Gustafsson et al <sup>(4)</sup> 2002	42	55	24	42	12
Mizrahi et al <sup>(17)</sup> 2002	94	74	15.7	9	40.3
Lasheen et al <sup>(18)</sup> 2003	50	98	2	0	22
Uribe et al <sup>(19)</sup> 2007	56	ns	7.1	21.4	43.8
Dubskyt et al <sup>(20)</sup> 2008	54	ns	24	11.1	ns

ns: not state

external opening. This was happened in two (50%) of four failure cases in this report due to missed diagnosis of deep postanal abscess with inadequate drainage and was changed to drainage seton treatment. The other two cases, suture leakage caused by tension of the suture line that performed direct appositional suture technique had to have repeated surgery. Although the direct appositional closure is safe and effective<sup>(9)</sup>, it is inferior to flap closure<sup>(10,11)</sup>.

There was minimal morbidity with one perianal hematoma and no patients presented with perianal soiling or incontinence for gas in this report with mucosal advancement flap closure. Although endorectal advancement flap preserves continence functions, and prevents deformity of the anal verge, many authors have reported a wide range of incontinence 0-42%. Endorectal advancement flap is a full thickness flap, which includes internal anal sphincter, the division of internal anal sphincter, might be a factor to decrease in continence. Manometric results in this technique suggest that this is associated with an impaired internal anal sphincter function<sup>(4)</sup>.

### Conclusion

Core out fistulectomy with anal sphincter reconstruction and primary closure of internal opening is a safe and effective procedure for high trans-sphincteric fistula. It has good functional outcomes and no disturbance of continence. This should be considered in the treatment of high trans-sphincteric fistula.

### References

1. McCourtney JS, Finlay IG. Setons in the surgical management of fistula in ano. *Br J Surg* 1995; 82: 448-52.
2. Seow-Choen F, Nicholls RJ. Anal fistula. *Br J Surg* 1992; 79: 197-205.
3. Williams JG, MacLeod CA, Rothenberger DA, Goldberg SM. Seton treatment of high anal fistulae. *Br J Surg* 1991; 78: 1159-61.
4. Gustafsson UM, Graf W. Excision of anal fistula with closure of the internal opening: functional and manometric results. *Dis Colon Rectum* 2002; 45: 1672-8.
5. Ortiz H, Marzo J. Endorectal flap advancement repair and fistulectomy for high trans-sphincteric and suprasphincteric fistulas. *Br J Surg* 2000; 87: 1680-3.
6. Miller GV, Finan PJ. Flap advancement and core fistulectomy for complex rectal fistula. *Br J Surg* 1998; 85: 108-10.
7. Marks CG, Ritchie JK. Anal fistulas at St Mark's Hospital. *Br J Surg* 1977; 64: 84-91.
8. Aguilar PS, Plasencia G, Hardy TG Jr, Hartmann RF, Stewart WR. Mucosal advancement in the treatment of anal fistula. *Dis Colon Rectum* 1985; 28: 496-8.
9. Athanasiadis S, Helmes C, Yazigi R, Kohler A. The direct closure of the internal fistula opening without advancement flap for transsphincteric fistulas-in-ano. *Dis Colon Rectum* 2004; 47: 1174-80.
10. Thomson WH, Fowler AL. Direct appositional (no flap) closure of deep anal fistula. *Colorectal Dis* 2004; 6: 32-6.
11. Athanasiadis S, Nafe M, Kohler A. Transanal rectal advancement flap versus mucosa flap with internal suture in management of complicated fistulas of the anorectum. *Langenbecks Arch Chir* 1995; 380: 31-6.
12. Athanasiadis S, Kohler A, Nafe M. Treatment of high anal fistulae by primary occlusion of the internal ostium, drainage of the intersphincteric space, and mucosal advancement flap. *Int J Colorectal Dis* 1994; 9: 153-7.
13. Ozuner G, Hull TL, Cartmill J, Fazio VW. Long-term analysis of the use of transanal rectal advancement flaps for complicated anorectal/vaginal fistulas. *Dis Colon Rectum* 1996; 39: 10-4.
14. Golub RW, Wise WE Jr, Kerner BA, Khanduja KS, Aguilar PS. Endorectal mucosal advancement flap: the preferred method for complex cryptoglandular fistula-in-ano. *J Gastrointest Surg* 1997; 1: 487-91.
15. Toccaceli S, Minervini S, Salvio A, Zarba ME, Mazzocchi P, Lepiane P, et al. Fistulectomy with closure by first intention in the treatment of perianal fistulae. *Minerva Chir* 1997; 52: 377-81.
16. Schouten WR, Zimmerman DD, Briel JW. Transanal advancement flap repair of transsphincteric fistulas. *Dis Colon Rectum* 1999; 42: 1419-22.
17. Mizrahi N, Wexner SD, Zmora O, Da Silva G, Efron J, Weiss EG, et al. Endorectal advancement flap: are there predictors of failure? *Dis Colon Rectum* 2002; 45: 1616-21.
18. Lasheen AE. Partial fistulectomy and fistular wall flap for the treatment of high perianal fistulas. *Surg Today* 2004; 34: 977-80.
19. Uribe N, Millan M, Minguez M, Ballester C, Asencio F, Sanchiz V, et al. Clinical and manometric results of endorectal advancement flaps for complex anal fistula. *Int J Colorectal Dis*

2007; 22: 259-64.  
20. Dubsky PC, Stift A, Friedl J, Teleky B, Herbst F.  
Endorectal advancement flaps in the treatment of

high anal fistula of cryptoglandular origin:  
full-thickness vs. mucosal-rectum flaps. Dis  
Colon Rectum 2008; 51: 852-7.

---

การผ่าตัด “Core out fistulectomy, anal sphincter reconstruction and primary repair of internal opening” ที่ใช้ในการรักษา complex anal fistula

ไพบูลย์ จิระไพศาลพงศ์

**จุดประสงค์:** เพื่อศึกษาวิธีการผ่าตัด core out fistulectomy, anal sphincter reconstruction and primary repair ในการรักษา complex anal fistula ผลแทรกซ้อน อัตราการเกิดโรคซ้ำ และผลการกลับอุจจาระ

**วัสดุและวิธีการ:** ตั้งแต่เดือนมกราคม พ.ศ. 2547 จนถึงเดือนธันวาคม พ.ศ. 2548 มีผู้ป่วยจำนวนทั้งสิ้น 33 คน เป็นเพศชาย 30 คน เพศหญิง 3 คน อายุเฉลี่ย 42 ปี (19-73 ปี) ส่วนใหญ่เป็น high trans-sphincteric fistula และมี internal opening ที่ posterior midline โดยตัดผู้ป่วยที่เป็นชนิด intersphincteric fistula, short tract trans-sphincteric fistula หรือผู้ที่มีปัญหาในการกลับอุจจาระออกจากการศึกษา

**ผลการศึกษา:** การผ่าตัดใช้เวลาประมาณ 35 นาที (20-90 นาที) จากการติดตามผู้ป่วยนานเฉลี่ย 14 เดือน (6-20 เดือน) พบว่าแผลหายภายใน 4 สัปดาห์ (2-5 สัปดาห์) โดยมีความยุ่งยากในการดูแลแผลน้อยมาก มีผลแทรกซ้อน เกิด perianal hematoma 1 ราย และเกิดโรคซ้ำ 4 ราย ผู้ป่วยทั้งหมดนี้ไม่พบว่ามีปัญหาในการกลับอุจจาระ

**สรุป:** การผ่าตัดวิธีนี้เป็นวิธีที่ให้ผลการรักษา high type anal fistula ที่ได้ผลดี เกิดผลแทรกซ้อนต่ำและไม่เกิดปัญหาในการกลับอุจจาระ

---