

Enhancing Limb Salvage by Non-Mobilized Peripheral Blood Angiogenic Cell Precursors Therapy in Patients with Critical Limb Ischemia[†]

Pramook Mutirangura MD*,
Chanean Ruangsetakit MD*, Chumpol Wongwanit MD*,
Khamin Chinsakchai MD*, Yael Porat PhD**,
Adina Belleli PhD**, David Czeiger MD***

[†] *ClinicalTrials.gov ID: NCT00523731*

* *Vascular Surgery Unit, Department of Surgery, Faculty of Medicine Siriraj Hospital, Mahidol University, Bangkok, Thailand*

** *Theravita Ltd. Nes Ziona, Israel*

*** *Ben-Gurion University, Beer Sheva, Israel*

Background: Stem cell therapy has been proposed to enhance the salvage of critically ischemic limbs.

Objective: Assess the efficacy and safety of the implantation of non-mobilized peripheral blood angiogenic cell precursors (NMPB-ACPs) in patients with critical limb ischemia (CLI) who were poor candidates for standard revascularization treatment options.

Material and Method: Six patients with CLI due to the infrapopliteal artery occlusive disease were included in the present study. Intramuscular injections of NMPB-ACPs were administered in the ischemic limbs. The efficacy was evaluated by clinical outcomes, ankle brachial index, toe brachial index, and computerized tomographic angiography.

Results: There was no evidence of local or systemic complication related to the procedure. Five patients (83.3%) had clinically significant improvement of adequate circulation at the distal limb for the complete healing. Four of them had complete healing of ischemic ulcers and stumps of toe amputation. However, one patient with adequate granulation tissue at the stump of the left first toe amputation subsequently suffered from severe foot infection originating from the other toes and eventually underwent below knee amputation. There was no improvement of circulation at the distal limb after the administration of NMPB-ACPs in one patient (16.7%) who eventually underwent major amputation.

Conclusion: The preliminary result of NMPB-ACPs therapy may be safe and provide benefits in the improvement of circulation in patients with CLI. A larger controlled trial is required to ascertain these preliminary results.

Keywords: Arterial occlusive diseases, Critical illness, Ischemia, Lower extremity, Peripheral blood stem cell transplantation, Stem cells

J Med Assoc Thai 2009; 92 (3): 320-7

Full text. e-Journal: <http://www.mat.or.th/journal>

Critical limb Ischemia (CLI) is a serious problem of peripheral arterial occlusive disease due to the high tendency of major limb loss⁽¹⁻³⁾. The comorbidities of

ischemic heart disease and cerebrovascular disease are commonly associated with this problem; resulting in high mortality and disability during the management⁽⁴⁻⁶⁾. The primary treatments including arterial bypass surgery, intervention and endovascular procedures may not succeed in many patients due to their poor distal artery run off and extensive calcification in lower extremity arteries. Major amputation therefore

Correspondence to: Mutirangura P, Vascular Surgery Unit, Department of Surgery, Faculty of Medicine Siriraj Hospital, Mahidol University, Bangkok 10700, Thailand. Phone: 0-2411-1808, Fax: 0-2412-9160. E-mail: pramook_siriraj@hotmail.com, sipmt@mahidol.ac.th

is inevitable in this situation⁽⁷⁻⁸⁾. Autotransplantation of bone marrow cell^(9,10) and granulocyte colony stimulating factor-mobilized peripheral blood mononuclear cell demonstrated the improvement of circulation in critically ischemic limbs⁽¹¹⁻¹⁵⁾.

The authors recently reported the generation of enriched population of angiogenic progenitor cells from human peripheral blood without the stimulation of bone marrow by granulocyte colony stimulating factor (G-CSF), called non-mobilized peripheral blood angiogenic cell precursors (NMPB-ACPs)⁽¹⁶⁾. Bone marrow (BM) -derived stem/progenitor cells can be obtained by direct aspiration from the bone marrow, a procedure that entails pain and discomfort and requires the use of anesthesia. An alternative method of obtaining cells from the BM by pre-treating the patient with G-CSF to induce migration of BM cells to the peripheral blood (mobilized peripheral blood) might result in increased blood viscosity, metabolic demand, and platelet counts⁽¹⁷⁻²⁰⁾. To circumvent the risks and discomfort caused by either method. The authors opted to use cells harvested from non-mobilized peripheral blood as the raw material for ACP generation.

These cells simultaneously expressed Ulex-lectin and uptake of acetylated low density lipoprotein (Ac-LDL) as well as markers CD34, CD133, vascular endothelial growth factor (VEGF) receptor 2 (also known as kinase domain region [KDR), Tie-2, CD144, von Willebrand factor (vWF), and CD31. They also secreted interleukine-8 (IL-8), VEGF, and angiogenin, and formed tube-like structures *in vitro*⁽¹⁶⁾. However, the clinical potential of these cells is yet to be determined.

The objective of the present pilot study was to assess the safety and efficacy of intra-muscular injections of NMPB-ACPs in patients with critical limb ischemia who were unresponsive to intensive medical therapy and unsuitable for revascularization procedure.

Material and Method

A pilot non-randomized, open-label study was carried out in six patients with the permission of the Ethics Committee, Faculty of Medicine Siriraj Hospital, Mahidol University, Bangkok, Thailand. The patients under the age of 85 years old with the symptoms of critical limb ischemia (Fontaine stage III and IV)⁽¹⁾ such as ischemic rest pain, ischemic non-healed ulcer and digital gangrene together with hemodynamic assessment indicating limb threatening ischemia such as ankle brachial index (ABI) below 0.4, or toe brachial index (TBI) below 0.24 were enrolled in the present study⁽²¹⁻²³⁾. The computerized tomographic angiography

(CTA) also demonstrated the site of arterial occlusion at the infrapopliteal level with poor distal artery run off. The patients suffering from stroke, valvular heart diseases, cardiomyopathy, malignant diseases, chronic infectious diseases such as AIDS and hepatitis as well as those receiving blood transfusion within 4 weeks preceding the recruitment were excluded from the present study.

Cell Culture: Two hundred and fifty milliliters of blood were taken from the peripheral vein of the patients in the present study, stored in a container at the temperature of 2°C-8°C and transported to the manufacturing facility in Israel. The isolation and incubation of autologous ACPs were performed by Theravita Co Ltd (Israel). Low-density synergetic cell populations (SCPs) were isolated as described previously⁽¹⁶⁾. To generate NMPB-ACPs, SCPs were cultured at a concentration of 1.5-3.0 x 10⁶ cells/ml in *X-vivo* 15 serum-free medium (Cambrex, East Rutherford, NJ) supplemented with 10% autologous human serum, 1-10 ng/ml VEGF(R&D Systems, Minneapolis, MN) and 5 IU/ml heparin (Kamada, Beit-Kama, Israel). The process of obtaining the stem cell was performed for five days.

Flow Cytometry: Prior to implantation, the NMPB-ACPs were harvested for analysis. The cells were incubated in the dark, on ice, for 30 minutes, with specific fluorochrome-conjugated CD34-APC (BD Biosciences, San Jose, CA) and CD31-PE (eBioscience, San Diego, CA), or with isotype-matched non-specific controls. To assess the cells potential to uptake Ac-LDL, NMPB-ACPs were loaded with 0.8 mg/ml DiO-Ac-LDL (BTI, Stoughton, MA, USA) for 15 minutes at 37°C. Exclusion of dead cells from the final analysis was performed using 7-amino actinomycin D ([7-AAD], eBioscience) staining. Cell suspension triplicates of 500,000 cells each was stained, assessed by fluorescence-activated cell-sorting ([FACS], FACSCalibur, Becton Dickinson) and analyzed by Cell Quest Pro software (Becton Dickinson). For each replication, at least 30,000 cells were acquired. The percentage of each marker was determined in each test tube. In addition, the mean and% coefficient of variance (%CV) were calculated for each marker. The results were reported as mean ± standard error (SE) of the percentage of stained cells. The number of stained cells was calculated by multiplying the number of harvested cells with the staining percentages obtained using the FACS.

ELISA assay for the detection of Interleukine-8 secretion: Samples of culture medium were

collected from cells on the harvesting day. Secretion of the chemokines Interleukine-8 ([IL-8], also known as the chemokine CXCL8) to the culture medium, was tested using commercial ELISA Kit (R&D systems Inc. MN, USA). Triplicates of standard curve consisting of seven dilutions and tested samples, each at four dilutions, were analyzed. The intensity of the color proportional to the IL-8 amount was measured using a microplate reader (Multiskan EX) and Ascent Software for Multiskan (Thermo Fisher Scientific, Inc, MA, USA). IL-8 concentration was determined relative to the standard curve samples. The final concentration was expressed as IL-8 secreted per total cell dose.

The injection procedure was done in a prone position with local anesthesia, sedation together with the monitoring of vital signs, electrocardiography and oxygen saturation. The injection was performed into calf muscles at 30 sites with one milliliter of stem cell suspension for each site, which was 1.5 centimeter apart. After the procedure, the patient was observed in hospital for monitoring hemodynamic status and systemic adverse events. Laboratory studies of hematology, kidney, and liver function including the level of serum myoglobin were completely assessed before and after the procedure. The hemodynamic assessment of limb ischemia was performed by ABI and TBI at 1 and 3 months after the treatment. The increase of 0.15 of segmental pressure index was considered significant improvement^(24,25). The CTA was repeated 3 months post procedure. The assessment of the degree of collateral circulation and the evidence of recanalization of the distal artery in CTA⁽²⁶⁾ was performed by the radiologist who was blinded to the present study. The primary end points of the clinical efficacy assessment were absolute disappearance of rest pain and complete healing of ischemic ulcer and stump of digital amputation. The follow up period was at least 3 months post treatment.

Results

Six male patients with the mean age of 65.5 ± 14.7 (range 38.6-83.8) years were enrolled in the present study. The clinical presentations were digital gangrene in four patients and ischemic ulcer in three patients (one patient had both gangrene and ulcer). One patient also had limited intermittent claudication with 100 meter maximal walking distance (Table 1). All six patients in the present study were classified as Fontaine stage IV⁽¹⁾. The average duration of clinical presentations was 5.0 ± 1.8 (range 3.1-7.1) months. The risk factors of atherosclerosis detected in this group were diabetes

mellitus in four (66.7%) patients, hypertension in three (50%) patients, heavy smoking in three (50%) patients and hypercholesterolemia in one (16.7%) patient. Ischemic heart disease was found in three (50%) patients and two (33.3%) of them had previous coronary bypass surgery. Prior to the present study, one patient had below the knee amputation on the contralateral limb 5 years ago and the fifth toe amputation on the affected limb one year ago. All six patients had TBI below 0.24 and two patients had ABI at and below 0.4 (Table 1). CTA of the lower extremities also demonstrated poor distal artery run off which caused the patients to be unsuitable for revascularization. Prior to the enrollment in the present study, ischemic ulcer and distal gangrene in these patients were treated for at least two months without any improvement. Toe amputations were planned without the promisingly complete healing process. Below the knee amputations were expected in all of them.

There was no change of hemodynamic status after taking 250 milliliters of peripheral blood from the patients in the process of NMPB-ACPs production. The harvested cells, $54.5 \times 10^6 \pm 10.2 \times 10^6$ (mean \pm SE, $n = 6$) in number, were administered by thirty intramuscular injections into the gastrocnemius muscle of the ischemic limb. The NMPB-ACPs were harvested after culturing exhibited high viability levels of $97.7\% \pm 0.6\%$ (mean \pm SE, $n = 6$). Flow cytometry (FACS) assessment showed the expression of the stem cell markers CD34 in $19.0\% \pm 2.4\%$ (mean \pm SE, $n = 6$) of the cells, concomitant expression of CD31, uptake of Ac-LDL in $33.2\% \pm 7.4\%$ (mean \pm SE, $n = 6$) of the cells and IL-8 ng/dose in $189.7\% \pm 158.0\%$ (mean \pm SE, $n = 6$) of the cells (Fig. 1).

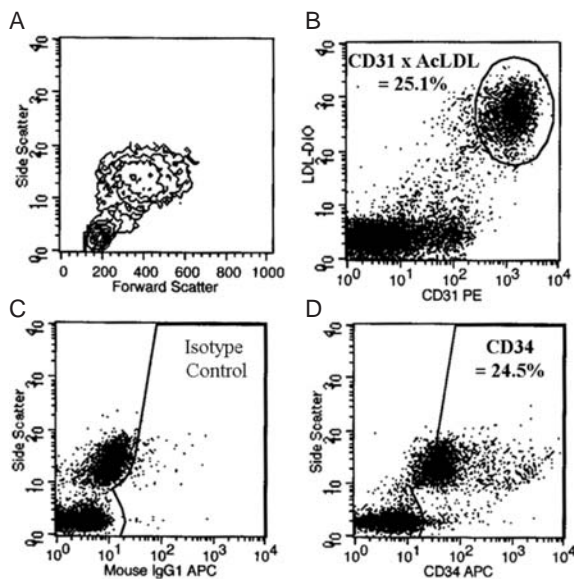
In the immediate follow-up after the intramuscular injection of NMPB-ACPs, five patients were hemodynamically stable. One patient developed the symptoms of dyspnea during the night. These symptoms were caused by fluid overload with immediate response to diuretic therapy. Elevated cardiac enzymes were detected even though the patient had no symptom of angina. He refused to undergo the invasive evaluation of ischemic heart disease. There were no abnormalities in the laboratory tests of hematology, kidney and liver function including the level of serum myoglobin. In the present study, five patients (83.3%) had clinically significant improvement of circulation at the distal limb adequate for the complete healing (Table 1). Two of them had the complete healing of ischemic ulcer. Another two with digital gangrene underwent toe amputation with

Table 1. Clinical outcomes, ankle brachial index (ABI), toe brachial index (TBI) and computerized tomographic angiography (CTA) at baseline and follow-up

No.	Clinical outcomes		ABI			TBI			CTA at 3 month follow-up visit	
	Baseline	3-6 months	Baseline	1 month	3 months	Baseline	1 month	3 months	Increased collateral circulation	Recanalisation
1	Non-healed ischemic ulcer at left 1 st toe	Complete ulcer healing	0.77	0.92*	0.85	0.00**	0.42*	0.49*	+	+
2	Rest pain and digital gangrene at right 1 st toe	Complete healing of toe amputation	1.08	1.09	0.92	0.22	0.20	0.46*	+	+
3	Digital gangrene at right 2 nd toe	Complete healing of toe amputation	0.70	0.70	0.90*	0.10	0.10	0.10	-	-
4	Non-healed Ischemic ulcer at left 1 st toe and limited intermittent claudication (100 meters)	Complete ulcer healing Improvement of intermittent claudication	0.55	0.80*	0.89*	0.22	0.38*	0.38*	-	+
5	Digital gangrene at left 1 st toe	Significant improvement of granulation tissue at base of toe stump but underwent BKA after infection due to poor compliance	0.40	0.40	NP	0.00**	0.00**	NP	NP	NP
6	Ischemic ulcer and digital gangrene at left 5 th toe	No improvement which might relate to congestive heart failure and finally underwent BKA	0.26	0.31	0.31	0.20	0.21	0.21	-	-

* The increase of 0.15 of segmental pressure index was considered significant improvement

** No flow, NP: not performed, BKA: below knee amputation



NMPB: ACPs: non-mobilized peripheral blood angiogenic cell precursors, AC-LDL: acetylated low density lipoprotein, FACS: fluorescence-activated cell-sorting

Fig. 1 Representative illustration of flow cytometry (FACS) analysis performed on harvested NMPB-ACPs from one patient. (A) Cells size (assessed by Forward Scatter) and granularity (assessed by Side Scatter); (B) Concomitant expression of anti-CD31 and uptake of AC-LDL; (C and D) Matched isotype control antibodies and specific anti-CD34 expression

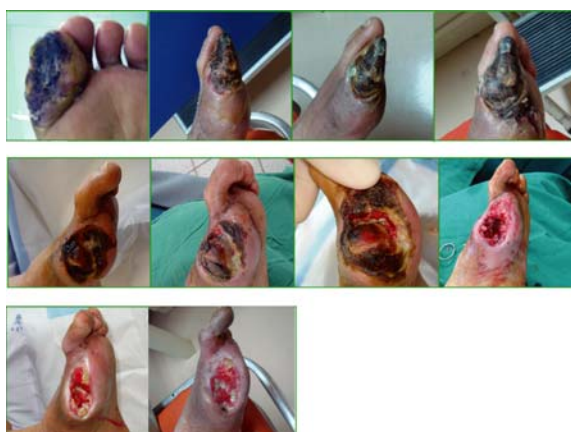

Fig. 2 The progression of left 1st toe status after the injection of NMPB-ACPs in the fifth patient demonstrating the adequacy of granulation tissue at the base of amputated wound for complete healing

the complete healing of the stump. Among these patients, one also had an improvement of intermittent claudication from 100 to 400 meters within three months and no symptom after six months. One patient had significant improvement of healing with the adequate granulation tissue at the base of the first toe stump (Fig. 2). Due to poor compliance and severe foot infection originated from the second and third toes with septicemia, this patient subsequently underwent below the knee amputation. On the contrary, one patient (16.7%) had no improvement after the administration of NMPB-ACPs. The ischemic process of the affected limb was progressively worse, requiring below the knee amputation (Table 1). All patients survived the 6-month follow up period.

In hemodynamic assessment during the 3-month follow up, two patients had an improvement in both ABI and TBI, one patient improved only in ABI and another only in TBI. However, two patients had no improvement in ABI or TBI. The CTA at three months post treatment demonstrated the recanalization of distal artery in three patients and the increase of collateral circulation in two of them (Table 1). Fig. 3 demonstrated the increase of collateral circulation and recanalization of the distal artery after the administration of NMPB-ACPs.

Discussion

Despite technical advance in intervention and surgical revascularization procedures, a substantial number of patients with peripheral arterial occlusive disease and critical limb ischemia remain in whom major amputation has to be considered the only final option⁽⁷⁾. However, there were several studies of auto-transplantation of bone marrow origin cells^(9,10) and G-CSF mobilized peripheral blood mononuclear cells in patients with critical limb ischemia demonstrating the improvement of ischemic status⁽¹¹⁻¹⁵⁾. Subsequently, these therapeutic modalities may enhance the opportunity of limb salvage in those patients. Due to the harmful effect of G-CSF to cardiac patients⁽²⁰⁾, the use of peripheral blood as raw material to provide angiogenic cell precursors without the stimulation of bone marrow by injection of G-CSF is simpler, safer, and more suitable for the elderly patient with high-risk comorbidities.

The present study illustrated that direct intramuscular injection of NMPB-ACPs had improved the distal circulation in five patients (83.3%) with a critically ischemic limb by achieving complete ulcer or toe stump healing in four (66.7%) patients and

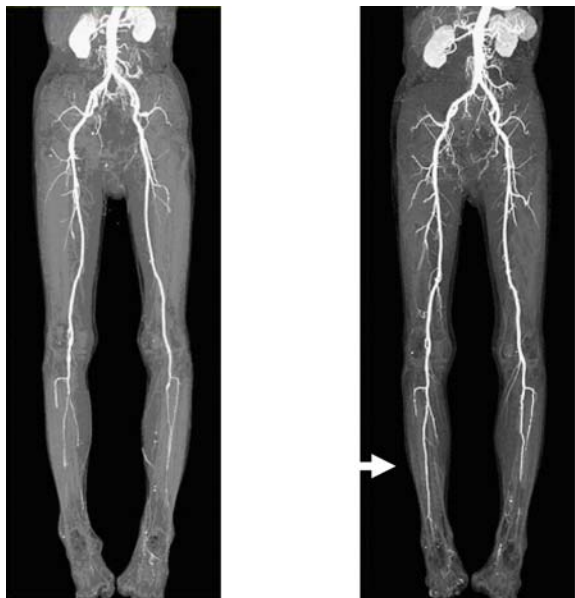


Fig. 3 Demonstration of the increase of collateral circulation and recanalization of the distal artery before and after the administration of NMPB-ACPs in the second patient (Arrow: recanalisation of right peroneal artery)

providing the adequate granulation tissue at the base of first toe stump in one (16.7%) patient (Fig. 2). These results indicated the efficiency of NMPB-ACPs in critical limb ischemia. Due to poor compliance and subsequently extensive foot infection, below the knee amputation was inevitable in the latter patient resulting in the incomplete assessment of the healing process. The successful outcome was supported by the improvement of ABI and/or TBI in four patients who had complete ulcer and/or toe stump healing and the evidence of CTA improvement in three patients with increased collateral circulation and/or the recanalization in the distal artery. However, there was no improvement of distal circulation in one patient (16.7%) who had dyspnea due to fluid overload after the injection. This clinical result was also confirmed by no change of ABI and TBI and no change in the degree of collateral circulation and recanalization in CTA. The compromised cardiac status may play a role of the proliferation of injected progenitor cells. In addition, this patient had the most severe ischemia in this group suffering from both ischemic ulcer and digital gangrene. The ABI and TBI of this patient were also the lowest in this group. It is worth identifying the level of ischemia

at which NMPB-ACPs is unable to improve the circulation. There was no abnormality in the laboratory study of hematology, kidney, and liver function as well as the level of serum myoglobin in all patients after the treatment, indicating that the injection of NMPB-ACPs was safe for patients with critical limb ischemia.

In conclusion, intramuscular injection of NMPB-ACPs may provide safety, and feasibility for the enhancement of limb salvage in patients with critical ischemic limb. The real efficacy of NMPB-ACPs for ischemic limb requires randomized control trials in a larger series of such patients.

Acknowledgments

The authors thank Professor V. Thamlikitkul for his advice and assistance, Associate Professor P. Vessakosol (PhD) and S. Tunpornpituk in the preparation of this manuscript.

References

1. Norgren L, Hiatt WR, Dormandy JA, Nehler MR, Harris KA, Fowkes FG, et al. Inter-society consensus for the management of peripheral arterial disease. *Int Angiol* 2007; 26: 81-157.
2. Critical limb ischaemia: management and outcome. Report of a national survey. The Vascular Surgical Society of Great Britain and Ireland. *Eur J Vasc Endovasc Surg* 1995; 10: 108-13.
3. Mutirangura P, Ruangsetakit C, Wongwanit C, Sermsathanasawadi N, Chinsakchai K. Atherosclerosis obliterans of the lower extremities in Thai patients. *J Med Assoc Thai* 2006; 89: 1612-20.
4. Hertzner NR, Beven EG, Young JR, O'Hara PJ, Ruschhaupt WF 3rd, Graor RA, et al. Coronary artery disease in peripheral vascular patients. A classification of 1000 coronary angiograms and results of surgical management. *Ann Surg* 1984; 199: 223-33.
5. Gentile AT, Taylor LM Jr, Moneta GL, Porter JM. Prevalence of asymptomatic carotid stenosis in patients undergoing infrainguinal bypass surgery. *Arch Surg* 1995; 130: 900-4.
6. Turnipseed WD, Berkoff HA, Belzer FO. Post-operative stroke in cardiac and peripheral vascular disease. *Ann Surg* 1980; 192: 365-8.
7. Nehler MR, Hiatt WR, Taylor LM Jr. Is revascularization and limb salvage always the best treatment for critical limb ischemia? *J Vasc Surg* 2003; 37: 704-8.
8. Nehler MR, Wolford H. Natural history and nonoperative treatment of chronic lower extremity

- ischemia. In: Rutherford RB, editor. *Vascular surgery*. 6th ed. Philadelphia: Elsevier Saunders; 2005: 1083-5.
9. Saigawa T, Kato K, Ozawa T, Toba K, Makiyama Y, Minagawa S, et al. Clinical application of bone marrow implantation in patients with arterio-sclerosis obliterans, and the association between efficacy and the number of implanted bone marrow cells. *Circ J* 2004; 68: 1189-93.
 10. Tateishi-Yuyama E, Matsubara H, Murohara T, Ikeda U, Shintani S, Masaki H, et al. Therapeutic angiogenesis for patients with limb ischaemia by autologous transplantation of bone-marrow cells: a pilot study and a randomised controlled trial. *Lancet* 2002; 360: 427-35.
 11. Arai M, Misao Y, Nagai H, Kawasaki M, Nagashima K, Suzuki K, et al. Granulocyte colony-stimulating factor: a noninvasive regeneration therapy for treating atherosclerotic peripheral artery disease. *Circ J* 2006; 70: 1093-8.
 12. Fadini GP, Avogaro A. Autologous transplantation of granulocyte colony-stimulating factor-mobilized peripheral blood mononuclear cells improves critical limb ischemia in diabetes. *Diabetes Care* 2006; 29: 478-9.
 13. Lenk K, Adams V, Lurz P, Erbs S, Linke A, Gielen S, et al. Therapeutical potential of blood-derived progenitor cells in patients with peripheral arterial occlusive disease and critical limb ischaemia. *Eur Heart J* 2005; 26: 1903-9.
 14. Kawamura A, Horie T, Tsuda I, Abe Y, Yamada M, Egawa H, et al. Clinical study of therapeutic angiogenesis by autologous peripheral blood stem cell (PBSC) transplantation in 92 patients with critically ischemic limbs. *J Artif Organs* 2006; 9: 226-33.
 15. Ishida A, Ohya Y, Sakuda H, Ohshiro K, Higashiesato Y, Nakaema M, et al. Autologous peripheral blood mononuclear cell implantation for patients with peripheral arterial disease improves limb ischemia. *Circ J* 2005; 69: 1260-5.
 16. Porat Y, Porozov S, Belkin D, Shimoni D, Fisher Y, Belleli A, et al. Isolation of an adult blood-derived progenitor cell population capable of differentiation into angiogenic, myocardial and neural lineages. *Br J Haematol* 2006; 135: 703-14.
 17. Losordo DW, Schatz RA, White CJ, Udelson JE, Veereshwarayya V, Durgin M, et al. Intramyocardial transplantation of autologous CD34+ stem cells for intractable angina: a phase I/IIa double-blind, randomized controlled trial. *Circulation* 2007; 115: 3165-72.
 18. Fukumoto Y, Miyamoto T, Okamura T, Gondo H, Iwasaki H, Horiuchi T, et al. Angina pectoris occurring during granulocyte colony-stimulating factor-combined preparatory regimen for autologous peripheral blood stem cell transplantation in a patient with acute myelogenous leukaemia. *Br J Haematol* 1997; 97: 666-8.
 19. Hill JM, Syed MA, Arai AE, Powell TM, Paul JD, Zalos G, et al. Outcomes and risks of granulocyte colony-stimulating factor in patients with coronary artery disease. *J Am Coll Cardiol* 2005; 46: 1643-8.
 20. Matsubara H. Risk to the coronary arteries of intracoronary stem cell infusion and G-CSF cytokine therapy. *Lancet* 2004; 363: 746-7.
 21. Yao ST. Haemodynamic studies in peripheral arterial disease. *Br J Surg* 1970; 57: 761-6.
 22. Vollrath KD, Salles-Cunha SX, Vincent D, Towne JB, Bernhard VM. Noninvasive measurement of toe systolic pressure. *Bruit* 1980; 4: 27-30.
 23. Zierler RE, Sumner DS. Physiologic assessment of peripheral arterial occlusive disease. In: Rutherford RB, editor. *Vascular surgery*. 6th ed. Philadelphia: Elsevier Saunders; 2005: 197-222.
 24. Baker JD, Dix DE. Variability of Doppler ankle pressures with arterial occlusive disease: an evaluation of ankle index and brachial-ankle pressure gradient. *Surgery* 1981; 89: 134-7.
 25. Johnston KW, Hosang MY, Andrews DF. Reproducibility of noninvasive vascular laboratory measurements of the peripheral circulation. *J Vasc Surg* 1987; 6: 147-51.
 26. Sun Z. Diagnostic value of color duplex ultrasonography in the follow-up of endovascular repair of abdominal aortic aneurysm. *J Vasc Interv Radiol* 2006; 17: 759-64.

การฉีดเซลล์ต้นแบบของหลอดเลือดในผู้ป่วยที่มีภาวะขาขาดเลือดในชั้นวิกฤตเพื่อการเพิ่มประสิทธิภาพในการเก็บรักษาขา

ประมุข มุทิตางกูร, เจเนียน เรืองเศรษฐกิจ, ชุมพล ว่องวานิช, คามิน ชินศักดิ์ชัย, Yael Porat, Adina Belleli, David Czeiger

ภูมิหลัง: เพื่อศึกษาประสิทธิภาพและความปลอดภัยของการใช้เซลล์ต้นแบบของหลอดเลือด ที่สกัดจากเลือดของผู้ป่วย ในการรักษาผู้ป่วยที่มีภาวะขาขาดเลือดชั้นวิกฤต

วัตถุประสงค์และวิธีการ: การศึกษาี้กระทำในผู้ป่วย 6 รายที่มีการอุดตันของหลอดเลือดแดงของขา ในระดับน่องร่วมกับมีการขาดเลือดในชั้นวิกฤตและไม่สามารถรักษาโดยการผ่าตัด เปลี่ยนทางเดินหลอดเลือดแดง หรือ การขยายหลอดเลือดแดงที่มีการตีบแคบผ่านทางสายสวนได้ ภาวะทั้งหมดเหล่านี้ ได้รับการตรวจยืนยันโดยการวัดค่าดัชนีความดันโลหิตบริเวณข้อเท้าและนิ้วเท้า พร้อมทั้งการตรวจสภาพหลอดเลือดแดงของขาด้วยเครื่องเอกซเรย์คอมพิวเตอร์ 3 มิติ การรักษากระทำโดยการฉีดเซลล์ต้นแบบของหลอดเลือดเข้าไปในกล้ามเนื้อน่องของขาที่มีการขาดเลือด เซลล์ต้นแบบของหลอดเลือดนี้ สกัดมาจากเลือดที่ดูดมาจากหลอดเลือดดำ บริเวณแขนของผู้ป่วย โดยไม่มีการใช้สารกระตุ้นไขกระดูกเพื่อสร้างเซลล์ต้นแบบชนิดต่าง ๆ ประสิทธิภาพของการรักษาประเมินโดยอาศัยการเปลี่ยนแปลงของลักษณะทางคลินิก ได้แก่ ผู้ป่วยหายจากอาการปวดเท้าในขณะพัก และการหายสนิทของแผลขาดเลือดบริเวณเท้า ร่วมกับผลการเปลี่ยนแปลงของการตรวจพิเศษต่าง ๆ ดังกล่าวข้างต้น ในช่วงเวลา 1 เดือน และ 3 เดือนภายหลัง การรักษา

ผลการศึกษา: พบว่าผู้ป่วยทั้ง 6 ราย ไม่มีภาวะแทรกซ้อนเฉพาะที่และทั่วร่างกายใด ๆ ที่เกี่ยวข้องกับการฉีดเซลล์ต้นแบบของหลอดเลือด ผู้ป่วย 5 ราย (ร้อยละ 83.3) มีลักษณะทางคลินิกของการเพิ่มเลือด บริเวณแผลขาดเลือดอย่างเพียงพอที่จะทำให้แผลหายได้ ในจำนวนดังกล่าวที่มีผู้ป่วย 4 รายที่มีการหายสนิทของแผลขาดเลือด หรือขาดแผลผ่าตัดจากการตัดนิ้วเท้าที่มีการเน่าตาย ส่วนผู้ป่วย 1 ราย ถึงแม้จะตรวจพบปริมาณของเลือดเพิ่มขึ้นอย่างเพียงพอต่อการหายของแผล แต่เกิดการติดเชื้ออย่างรุนแรงจากนิ้วเท้าอื่น และลุกลามอย่างรวดเร็วขึ้นมาบริเวณเท้า ร่วมกับการเกิดภาวะติดเชื้อทั่วร่างกายทำให้ผู้ป่วยถูกตัดขาในระดับน่อง ซึ่งมีผลให้ไม่สามารถทำการประเมินการหายสนิทของแผลบริเวณนิ้วเท้าภายหลังการรักษาได้อย่างสมบูรณ์ นอกจากนี้ผู้ป่วย 1 ราย ที่เหลือ (ร้อยละ 17.7) พบว่าไม่มีการเพิ่มปริมาณเลือดอย่างเพียงพอที่จะทำให้แผลหายได้ และถูกตัดขาในระดับน่อง

สรุป: การศึกษาโดยใช้เซลล์ต้นแบบของหลอดเลือดฉีดเข้าไปในขาที่มีการขาดเลือดชั้นวิกฤตในกลุ่มผู้ป่วยนี้มีความปลอดภัย และมีส่วนสำคัญในการเพิ่มเลือดและเก็บรักษาขาที่ไม่สามารถรักษาได้โดยวิธีการเพิ่มเลือดอื่น ๆ
