

Visual Electrophysiology in Congenital Nystagmus with Normal Fundus

Thammanoon Surachatkumtonekul MD*,
Ngamkae Ruangvaravate MD*, Chuenchanok Sriyakul MD*

* Department of Ophthalmology, Faculty of Medicine Siriraj Hospital, Mahidol University, Bangkok, Thailand

Objective: To identify the ophthalmic causes of congenital nystagmus with normal eye examination by visual electrophysiologic tests.

Material and Method: Medical records of patients who presented with nystagmus and no other neurological sign before 6 months of age with normal eye examination, between February 2004 and February 2005, were reviewed. Complete ophthalmic examination and visual electrophysiologic tests were performed to identify the ophthalmic causes of congenital nystagmus.

Results: Thirty-four patients had met the criteria. Leber's congenital amaurosis was diagnosed in 13 patients (38.2%) by non-recordable electroretinography (ERG) and normal visual evoked potential (VEP). Idiopathic infantile nystagmus was diagnosed in 12 patients (35.3%) by normal ERG and VEP. Achromatopsia was diagnosed in 8 patients (23.5%) by flat retinal cone ERG but normal rod ERG and VEP. Rod-cone dystrophy was diagnosed in one patient (3%) by abnormal rod and cone ERG.

Conclusion: Visual electrophysiologic study is helpful to identify the ophthalmic causes of congenital nystagmus. Leber's congenital amaurosis is a common cause in congenital nystagmus.

Keywords: Congenital nystagmus, Visual electrophysiology, Electroretinogram (ERG), Visual evoked potentials (VEP)

J Med Assoc Thai 2009; 92 (2): 224-8

Full text. e-Journal: <http://www.mat.or.th/journal>

Congenital nystagmus is an involuntary, conjugate, oscillation of the eyes. It may appear as a pendular or jerk nystagmus. Nystagmus is rarely noted at birth. It usually presents between 8 and 12 weeks of age. In a large proportion of congenital nystagmus patients, there was abnormality of anterior visual pathway, which included cornea, anterior segment, lens, vitreous, retina, and optic disc. Therefore, some cases of congenital nystagmus can be diagnosed by routine eye examination^(1,2).

Some congenital nystagmus patients had normal eye examination, so the authors could not identify the cause of nystagmus by taking history and complete ophthalmic examination. Visual electrophysiology tests may be the diagnostic tools for

these nystagmus patients. Electroretinography (ERG) assists in diagnosis of nystagmus associated with retinal disease such as Leber's congenital amaurosis, congenital stationary night blindness, and achromatopsia⁽³⁾. Visual evoked potentials (VEP) demonstrate abnormal decussation of optic nerve fibers in albinism patients^(4,5).

Material and Method

The present study was approved by Siriraj Medical Ethics Committee. Retrospective medical charts were reviewed between February 2004 and February 2005. All patients who presented with horizontal nystagmus before the age of 6 months were included in the present study. They underwent complete ophthalmological and neurological examinations. The cycloplegic refractions were performed in all cases. All patients had normal ophthalmological and neurological examinations except horizontal nystagmus.

Correspondence to: Surachatkumtonekul T, Department of Ophthalmology, Faculty of Medicine Siriraj Hospital, Mahidol University, Bangkok 10700, Thailand. Phone: 0-2419-8033, Fax: 0-2411-1906. E-mail: sitsr@mahidol.ac.th

Exclusion criteria are patients who had abnormalities of ophthalmological examination other than horizontal nystagmus, abnormality of neurological examination, did not have visual electrophysiology testings performed, had latent nystagmus, or did not have their ophthalmological examinations completed in the medical records.

Visual electrophysiological examinations were performed under sedation by choral hydrate (50-70 mg/kg) in uncooperative children and pupils were dilated in all patients. Electroretinography (ERG) was performed by skin electrodes attached to both lower lids and reference electrode was attached to the central part of the forehead. The ground electrode was placed at scalp midline-anteriorauricular line. Skin electrodes were used in both children and adult.

ERG was tested following recommendation by International Society for Clinical Electrophysiology of Vision (ISCEV). White flash stimulation intensity setting 16, frequency 2 Hz stimulated cone function called "Photopic White". This stimulation created both "a" and "b" waves. White flash intensity setting 8, frequency 30 Hz stimulation called "Flickering ERG" was used for testing cone function. To test rod function, patients were dark adapted by staying in a dark room for 30 minutes and then blue flash frequency 2 Hz stimulation was performed. The test showed only a large b wave called "Scotopic ERG". Patients remained in the dark room and the authors used single bright-white flash frequency 2 Hz to stimulate all photoreceptors called "Mesopic ERG", which has small wavelets of oscillatory potential (OP wave) in the ascending limb of a wave. Mesopic ERG represented the electrical responses from both rod and cone cells from the entire retina except ganglion cell layers.

Normal values of ERG study in Siriraj Hospital by using skin electrode: Photopic white ERG; a wave amplitude > 14 μ v, b wave amplitude > 31 μ v, Flickering ERG; b wave amplitude > 27 μ v, Scotopic ERG; b wave amplitude > 38 μ v, Mesopic ERG; a wave amplitude > 58 μ v, b wave amplitude > 115 μ v.

Visual evoked potentials (VEP) were recorded by skin electrode. Ground electrode was attached at the scalp midline-anteriorauricular line. Active electrodes were attached to the posterior scalp. Reference electrode was attached at mid forehead. Stimuli for VEP testing were pattern VEP and flash VEP. Pattern VEP was used in co-operative patients by using black and white checkerboard stimulation: the black turned to white and white turned to black by frequency 2 Hz. Flash VEP was stimulated by white

flash frequency 2 Hz. VEP was evaluated in latency (time from stimulation to peak response) and amplitude of peak response (P100).

Normal values of VEP of Siriraj Hospital: Pattern VEP; latency < 100 msec, amplitude > 5 μ v. Flash VEP; latency < 120 msec, amplitude > 10 μ v.

Results

Medical records were reviewed between February 2004 and February 2005. Sixty-eight patients who presented with nystagmus before the age of 6 months and 39 patients who had normal eye examination were found. Thirty-four patients met the criteria (Table 1). Thirteen patients (38.2%) were diagnosed as Leber's congenital amaurosis by non-recordable ERG in all stimuli (Fig. 1.1) and VEP revealed normal to mild decreased amplitude in P100. Nine male and four female cases ranged in age between 4 months and 29 years old. Range of visual acuity was from not fix and follow to 6/18. Cycloplegic refractions were minus 7.25 diopters to plus 4.0 diopters (spherical equivalence).

Eight patients (23.5%) were diagnosed as Achromatopsia. Seven male cases and one female case ranged from 3 to 23 years of age. Patients who had a history of photophobia and visual acuity ranged from fix and follow to 6/60. There were seven patients who had hyperopia with astigmatism. Cycloplegic refractions were plus 2.5 diopters to plus 5.25 diopters (spherical equivalence) in seven cases. One case had astigmatism minus 3.0 diopters in 180 degrees in both eyes. ERG revealed absence of cone function with normal rod function (Fig. 1.2). VEP P100 amplitudes were normal to slightly decreased.

One patient (3%) in the present study was diagnosed with rod-cone dystrophy. He was 5 years old. His best corrected visual acuity was 6/18-2, 6/24-1. Cycloplegic refraction was hyperopia (plus 1.50 diopters in right eye and plus 3.50 diopters minus 0.75 axis 25° in left eye). Visual field testing by Goldmann

Table 1. Causes of congenital nystagmus with normal fundus

Diseases	Number (cases)	%
Leber's congenital amaurosis (LCA)	13	38.2
Idiopathic infantile nystagmus (IIN)	12	35.3
Achromatopsia	8	23.5
Rod cone dystrophy	1	3
Total	34	100

was normal. The ERG amplitudes were decreased in all stimuli. Rod function was more decreased than cone function (Fig. 1.3). VEP was normal in latency and amplitude of P100.

Twelve patients (35.3%) were diagnosed as idiopathic infantile nystagmus from normal ERG and VEP (Fig. 1.4). Six male and six female cases ranged in age from 2 to 29 years old. Visual acuities ranged from not fix and follow to 6/12. Cycloplegic refractions were minus 6.5 diopters to plus 4.5 diopters (spherical equivalence). All patients had normal ophthalmological and neurological examinations.

Discussion

From sixty-eight patients, 29 cases (42.6%) with congenital nystagmus had the causes identified from complete ophthalmological examination (e.g. anterior segment disorders 8 cases, albinism 5 cases, foveal hypoplasia 2 cases, retinal disorders 5 cases, optic nerve lesions 7 cases and congenital infection 2 cases). Five patients were excluded from the present

study because of incomplete medical records or no visual electrophysiological testing. Thirty-four patients of congenital nystagmus with normal fundus and no neurological abnormality were diagnosed as congenital nystagmus but the authors still do not know the exact pathology. The visual electrophysiology could identify the retinal causes in 22 patients (64.7%) from 34 patients. Twelve patients (35.3%) with normal ERG and VEP were diagnosed as idiopathic infantile nystagmus syndrome.

The skin electrode visual electrophysiology is easily performed and cheap. The electrodes can be applied to the skin or scalp by first aid tape. This is a non invasive procedure and gives reliable results^(1,6-8).

Leber's congenital amaurosis was the most common cause of congenital nystagmus with normal fundus in the present study. These patients had extinguished ERG and normal VEP. This finding corresponded with previous studies^(1,3,9). Some Leber's congenital amaurosis had mild decreased amplitude P100 of VEP, which may be explained from severe

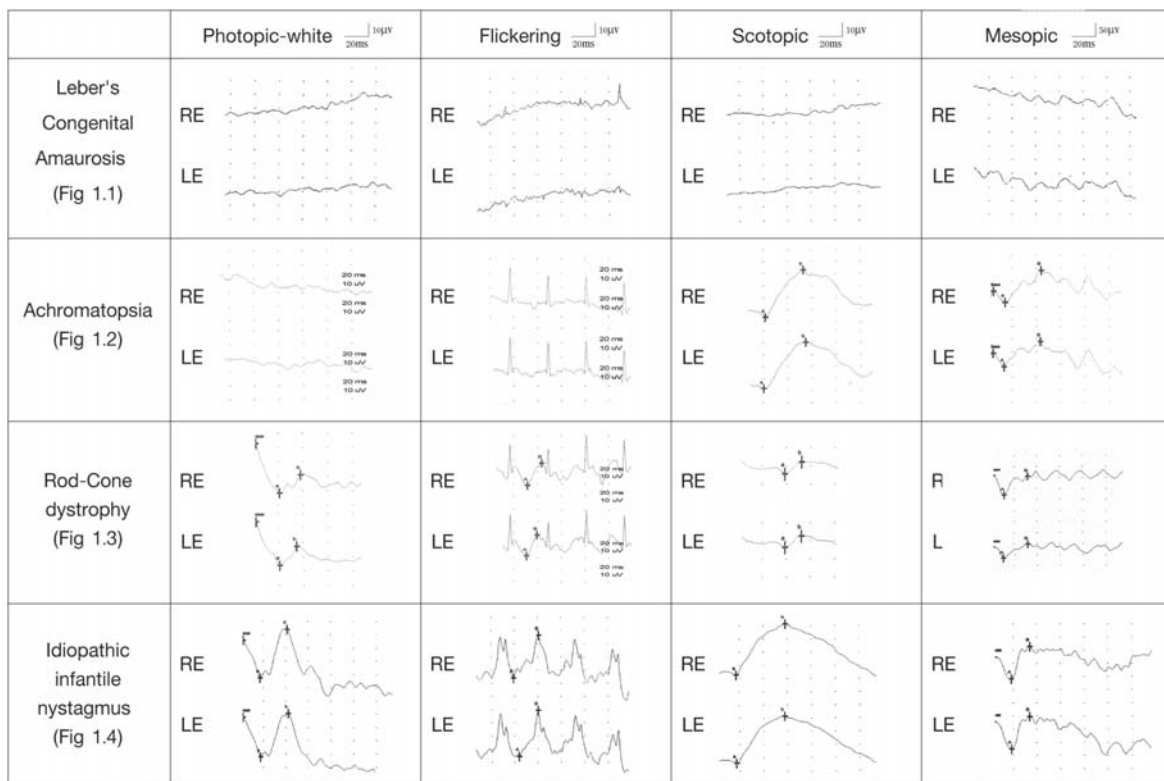


Fig. 1 Demonstration of ERG-findings in a case of Leber's congenital amaurosis (1.1), Acromatopsia (1.2), Rod-cone Dystrophy (1.3) and idiopathic infantile nystagmus (1.4)
RE = Right Eye, LE = Left Eye, μv = microvolt, ms = millisecond

impairment of retinal function. Achromatopsia was not an uncommon cause in the present study. These patients had abnormal ERG: absence of cone function with normal rod function and normal to mild decreased amplitude of VEP. ERG findings are consistent with previous studies but their VEP findings were delayed latency to flash and pattern reversal stimulation^(6,7,10,11). Mild decreased amplitude of VEP may be from absence of cone function that reflects to macular function. The authors found rod-cone dystrophy in one case. There were twelve of thirty-four patients (35.3%) diagnosed as idiopathic nystagmus syndrome from normal ophthalmological examination and normal visual electrophysiology testing⁽¹⁾.

Clinical and visual electrophysiological finding are important and essential for making the diagnosis in congenital nystagmus. When diagnosing Leber's congenital amaurosis, ERG is essential⁽¹²⁻¹⁴⁾. However, recorded VEP provides prognosis information⁽⁹⁾.

In congenital nystagmus, the authors could clinically make a diagnosis from routine ophthalmological examination in many cases but in some cases, the authors had to perform visual electrophysiological testings to make a definite diagnosis and provide prognosis information. The importance of finding definite diagnosis can lead to further treatment especially Leber's congenital amaurosis and achromatopsia in which gene therapy may have a role in future treatment.

References

1. Brecej J, Stirn-Kranjc B. Visual electrophysiological screening in diagnosing infants with congenital nystagmus. *Clin Neurophysiol* 2004; 115: 461-70.
2. Casteels I, Harris CM, Shawkat F, Taylor D. Nystagmus in infancy. *Br J Ophthalmol* 1992; 76: 434-7.
3. Lambert SR, Taylor D, Kriss A. The infant with nystagmus, normal appearing fundi, but an abnormal ERG. *Surv Ophthalmol* 1989; 34: 173-86.
4. Apkarian P, Shallo-Hoffmann J. VEP projections in congenital nystagmus; VEP asymmetry in albinism: a comparison study. *Invest Ophthalmol Vis Sci* 1991; 32: 2653-61.
5. Creel D, Spekrijse H, Reits D. Evoked potentials in albinos: efficacy of pattern stimuli in detecting misrouted optic fibers. *Electroencephalogr Clin Neurophysiol* 1981; 52: 595-603.
6. Shawkat FS, Kriss A, Thompson D, Russell-Eggitt I, Taylor D, Harris C. Vertical or asymmetric nystagmus need not imply neurological disease. *Br J Ophthalmol* 2000; 84: 175-80.
7. Shaw FS, Kriss A, Russell-Eggitt I, Taylor D, Harris C. Diagnosing children presenting with asymmetric pendular nystagmus. *Dev Med Child Neurol* 2001; 43: 622-7.
8. Weiss AH, Biersdorf WR. Visual sensory disorders in congenital nystagmus. *Ophthalmology* 1989; 96: 517-23.
9. Brecej J, Stirn-Kranjc B. ERG and VEP follow-up study in children with Leber's congenital amaurosis. *Eye* 1999; 13(Pt 1): 47-54.
10. Kriss A. Nystagmus and pediatric visual electrophysiology. In: Kimura J, Shibasaki H, editors. *Recent advances in clinical neurophysiology. Excerpta Medica, International Congress Series 1101. Amsterdam: Elsevier; 1996: 480-7.*
11. Kriss T, Thompson D. Visual electrophysiology. In: Taylor D, editor. *Paediatric ophthalmology. 2nd ed. Oxford: Blackwell Science; 1997: 93-121.*
12. Cibis GW, Fitzgerald KM. Electroretinography in congenital idiopathic nystagmus. *Pediatr Neurol* 1993; 9: 369-71.
13. Lambert SR, Newman NJ. Retinal disease masquerading as spasmus nutans. *Neurology* 1993; 43: 1607-9.
14. Grieshaber MC, Boltshauser E, Niemeyer G. Leber's congenital amaurosis. In: Hollyfield JG, Robert EA, Lavail MM, editors. *Clinical heterogeneity and electroretinography in 27 patients. Retinal degenerative diseases and experimental therapy. New York: Kluwer Academic/Plenum Publishers; 1999: 95-104.*

คลื่นไฟฟ้าจอบประสาทตาในผู้ป่วยลูกตาสันตั้งแต่กำเนิด ที่มีจอบประสาทตาปกติ

ธรรมบุญ สุรชาติกำธรกุล, งามแข เรืองวรเวทย์, ชื่นชนก ศรียากุล

วัตถุประสงค์: เพื่อหาสาเหตุทางจักษุวิทยาในผู้ป่วยลูกตาสันตั้งแต่กำเนิดด้วยวิธีการตรวจคลื่นไฟฟ้าจอบประสาทตา
วัสดุและวิธีการ: เป็นการศึกษาย้อนหลังโดยศึกษาจากเวชระเบียนผู้ป่วยที่มีลูกตาสันก่อนอายุ 6 เดือน ที่มีการตรวจทางจักษุ ปกติในช่วงเดือนกุมภาพันธ์ พ.ศ. 2548 ถึงเดือนกุมภาพันธ์ พ.ศ. 2549

ผลการศึกษา: รวบรวมผู้ป่วยได้ 34 รายโดยพบผู้ป่วยเลเบอร์คอนเจนิตัลอมาลูสิส 13 ราย โดยมีผลการตรวจคลื่นไฟฟ้าจอบประสาทตาไม่ตอบสนองทั้ง เซลล์รับแสงในที่สว่างและเซลล์รับแสงในที่มืด ลูกตาสันโดยไม่ทราบสาเหตุพบ 12 ราย โดยมีผลการตรวจคลื่นไฟฟ้าจอบประสาทตาเป็นปกติ ภาวะไม่มีเซลล์จอบประสาทตารับแสงในที่สว่าง 8 ราย โดยมีผล การตรวจคลื่นไฟฟ้าจอบประสาทตาเสียในส่วนของเซลล์รับแสงในที่สว่างและพบ ภาวะผิดปกติของเซลล์จอบประสาทตารับแสงในที่สว่างและที่มืด 1 ราย

สรุป: การตรวจคลื่นไฟฟ้าจอบประสาทตามีประโยชน์ในการหาสาเหตุทางจักษุวิทยาในผู้ป่วยลูกตาสันตั้งแต่กำเนิดที่มีการตรวจทางจักษุปกติ โดยพบเลเบอร์คอนเจนิตัลอมาลูสิสเป็นสาเหตุที่พบบ่อย
