

# Perianal Block for Ambulatory Hemorrhoidectomy, an Easy Technique for General Surgeon

Potchavit Aphinives MD\*

\* Department of Surgery, Faculty of Medicine, Khon Kaen University, Khon Kaen, Thailand

**Background:** Hemorrhoid surgery is mostly being performed as an inpatient procedure under general or regional anesthesia. However, there was a trend toward performing anorectal surgery in an ambulatory setting utilizing local anesthesia.

**Objective:** To propose an easy technique of perianal block for ambulatory hemorrhoidectomy.

**Material and Method:** Between January 2004 and June 2007, 61 patients underwent hemorrhoidectomy under local anesthesia. Lignocaine with adrenaline was injected into the perianal area with an easy technique.

**Results:** Sixty-one patients with a mean age of 41 years underwent ambulatory hemorrhoidectomy. The mean operative time was 21 minutes. Almost all patients preferred to go home, 5-200 km away from this hospital, taking 20 minutes to 4 hours on transportation.

**Conclusion:** An easy technique of perianal block provides availability of performing ambulatory hemorrhoidectomy under general surgeons' hands.

**Keywords:** Hemorrhoidectomy, Local anesthesia, Technique

*J Med Assoc Thai* 2009; 92 (2): 195-7

Full text. e-Journal: <http://www.mat.or.th/journal>

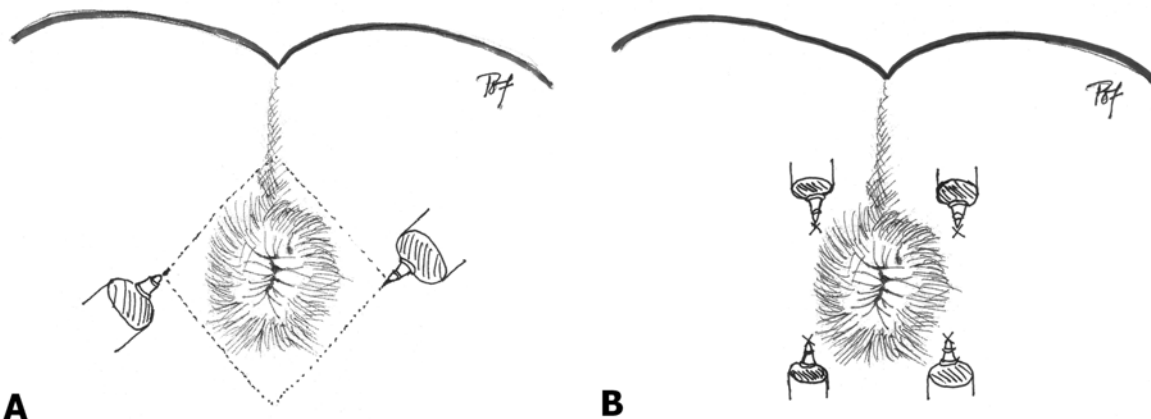
Hemorrhoids are one of the common diseases of mankind. Although non-operative treatments are first-line therapy for hemorrhoids of all grades, surgery is often necessary especially in patients with third and fourth degree hemorrhoids<sup>(1)</sup>. Hemorrhoid surgery is still being performed as an inpatient procedure under general endotracheal or regional anesthesia (spinal or epidural) in many centers today. However, there was a trend toward performing anorectal surgery in an ambulatory setting utilizing local anesthesia combined with intravenous sedation. Several studies showed the safety and efficacy of this type of anesthesia for anorectal surgery to facilitate same-day discharge<sup>(2-4)</sup>. Potential benefits of this anesthetic technique over general or regional anesthesia include more rapid recovery, less postoperative morbidity, shorter length of hospital stay and potentially reduced costs associated with inpatient care<sup>(5)</sup>. Several perianal anesthetic techniques were used among studies<sup>(2-4,6,7)</sup>. The author proposes an easy technique for every surgeon.

## Material and Method

Between January 2004 and June 2007, 61 patients with symptomatic third degree (n = 11) or fourth degree (n = 43) internal hemorrhoids or thrombosed external hemorrhoids (n = 7) underwent hemorrhoidectomy under local anesthesia. All patients were premedicated with 75 mg of diclofenac and 5 mg of diazepam intravenously. The patients were placed in the jackknife position. The perianal skin was painted with a povidine solution.

Lignocaine (1% Xylocaine® with adrenaline) was used for the blockade. Lignocaine was administered via fine needle (No. 23) with 3-ml syringe. The first two injections were applied bilaterally, 5 mm from border of perianal skin, the lignocaine was administered superficially performing the diamond shape (Fig. 1A). After 1 minute, further four injections were applied into four quadrants, 5 mm from the border of the anal opening, every 1 ml was administered at 4-cm (needle length), 3-cm, 2-cm depth from skin, respectively (Fig. 1B). With this technique, lignocaine filled the intersphincteric space and blocked all nerve supplies from the inferior rectal branch of the pudendal nerve (S2, S3) and from the perineal branch of the fourth

Correspondence to: Aphinives P, Department of Surgery, Faculty of Medicine, Khon Kaen University, Khon Kaen, 40002, Thailand. Phone: 043-348-393, Fax: 043-348-393, Mobile: 089-711-5475, E-mail: [potchavit@yahoo.com](mailto:potchavit@yahoo.com)



**Fig. 1** A) First two injections performed the diamond shape, B) Further four injections were applied into 4 quadrants

sacral nerve, causing paralysis of the external sphincter. This local anesthetic solution provided 60-90 minutes of anesthesia and reduced intraoperative bleeding.

Two minutes later, Fansler anoscope was applied and closed hemorrhoidectomy (Fergus on technique) was performed. Each patient was discharged within 2 hours postoperatively. Their home medications included oral NSAIDS, oral antibiotics and anti-inflammatory suppository drug.

### Results

During the study period, 61 patients (26 males and 35 females) with a mean age of  $41 \pm 12$  years (range 20-73 years) underwent ambulatory hemorrhoidectomy. One patient had three complexes excised, 26 patients had two complexes excised, and 35 patients had one complex excised.

The mean operative time was  $21 \pm 5$  minutes (range 15-35 minutes). No patient complained of any problem concerning local anesthesia. Only five patients required additional injection of lignocaine into the submucosal area beneath the hemorrhoids, 0.5-1 ml per injection. Almost all patients preferred to go home, 5-200 km away from this hospital, taking 20 minutes to 4 hours on transportation. No patient needed hospitalization, except one who had postoperative bleeding and thrombosis following motorcycle driving, 6 hours after hemorrhoidectomy, but no reoperation was performed. After 24 hours observation, this patient was discharged from the hospital.

### Discussion

Both lithotomy and jackknife positions are commonly used for hemorrhoidectomy. However,

jackknife position seems to be more appropriate in the situation of local anesthesia, because of better exposure and direction of injection. Lignocaine provides excellent initial pain relief and adrenaline reduces bleeding in the operative field due to vasoconstriction. In contrast to common belief<sup>(3,4)</sup>, lignocaine with adrenaline provides enough time for not only hemorrhoidectomy but also transportation to home. In this technique, the four-quadrant injections are performed through perianal skin landmark causing easier than the fan-shaped injection for pudendal nerve blockage. Compared to submucosal blockage via anoscope<sup>(6)</sup>, no bleeding from the site of previous injections disturbed following injections. No index finger in the anal canal guided track of injection, which may increase risk of accidental stabbing to the surgeon<sup>(7)</sup>. Neither preoperative tests nor preoperative enema was necessary. Finally, the use of a home care program that includes a high residue diet, oral analgesic, and anti-inflammatory suppository drug makes an easy postoperative course.

### Conclusion

An easy technique of perianal block provides availability of performing ambulatory hemorrhoidectomy under general surgeons' hands.

### References

1. MacRae HM, McLeod RS. Comparison of hemorrhoidal treatment modalities. A meta-analysis. *Dis Colon Rectum* 1995; 38: 687-94.
2. Haveran LA, Sturrock PR, Sun MY, McDade J, Singla S, Paterson CA, et al. Simple harmonic scalpel hemorrhoidectomy utilizing local anesthesia

- combined with intravenous sedation: a safe and rapid alternative to conventional hemorrhoidectomy. *Int J Colorectal Dis* 2007; 22: 801-6.
3. Lohsiriwat D, Lohsiriwat V. Outpatient hemorrhoidectomy under perianal anesthetics infiltration. *J Med Assoc Thai* 2005; 88: 1821-4.
  4. Argov S. Ambulatory radical hemorrhoidectomy: personal experience with 1,530 Milligan-Morgan operations with follow-up of 2-15 years. *Dig Surg* 1999; 16: 375-8.
  5. Li S, Coloma M, White PF, Watcha MF, Chiu JW, Li H, et al. Comparison of the costs and recovery profiles of three anesthetic techniques for ambulatory anorectal surgery. *Anesthesiology* 2000; 93: 1225-30.
  6. Nivatvongs S. Technique of local anesthesia for anorectal surgery. *Dis Colon Rectum* 1997; 40: 1128-9.
  7. Delikoukos S, Zacharoulis D, Hatzitheofilou C. Stapled hemorrhoidectomy under local anesthesia: tips and tricks. *Dis Colon Rectum* 2005; 48: 2153-5.

---

## เทคนิคการฉีดยาชารอบทวารหนักแบบง่ายสำหรับศัลยแพทย์ทั่วไป เพื่อทำการผ่าตัดริดสีดวงทวารหนัก

พจนันชวิทย์ อภินิเวศ

ผู้ป่วยจำนวน 61 ราย ได้รับการผ่าตัดริดสีดวงทวารหนัก ในระหว่างเดือนมกราคม พ.ศ. 2547 ถึงเดือนมิถุนายน พ.ศ. 2550 โดยการฉีดยาชารอบทวารหนักด้วยเทคนิคแบบง่าย อายุเฉลี่ยของผู้ป่วยเท่ากับ 41 ปี ระยะเวลาผ่าตัดเฉลี่ย 21 นาที หลังผ่าตัดผู้ป่วยเกือบทั้งหมดเดินทางกลับบ้าน โดยมีระยะทางตั้งแต่ 5 ถึง 200 กิโลเมตร และใช้เวลาเดินทางจากโรงพยาบาลตั้งแต่ 20 นาที ถึง 4 ชั่วโมง เทคนิคที่นำเสนอในรายงานนี้ ศัลยแพทย์ทั่วไปสามารถนำไปใช้ได้โดยง่าย เพื่อให้สามารถผ่าตัดริดสีดวงทวารหนัก โดยผู้ป่วยไม่จำเป็นต้องนอนพักในโรงพยาบาล