

Aortic Bifurcation: A Cadaveric Study of Its Relationship to the Spine

Kimaporn Khamanarong MD*,
Surachai Sae-Jung MD**, Chunsri Supa-adirek MD***,
Supawadee Teerakul*, Parichat Prachaney PhD*

* Department of Anatomy, Faculty of Medicine, Khon Kaen University, Khon Kaen, Thailand

** Department of Orthopaedics, Faculty of Medicine, Khon Kaen University, Khon Kaen, Thailand

*** Division of Radiotherapy, Department of Radiology, Faculty of Medicine, Khon Kaen University, Khon Kaen, Thailand

Background: Vascular injuries are the main complication of the anterior approach to the lumbosacral spines. One of the key procedural steps is the identification and gentle manipulation of the aortic bifurcation to prevent the vascular injury and provide the adequate exposure during anterior lumbosacral operation.

Objective: The present study was to determine the level of abdominal aortic bifurcation in Thai cadavers.

Material and Method: The abdominal aortic bifurcation was studied on 187 cadavers (132 men, 55 women). The average ages of the cadavers were 67.3 ± 0.8 years (range from 30 to 88 years). The accurate site of the abdominal aortic bifurcation was determined by the relationship of the bifurcation with the level of neighbor lumbosacral spine.

Results: The abdominal aorta descended and bifurcated into two common iliac arteries at the level of L4 vertebra in 131 cases (70.1%), at the fourth lumbar intervertebral disc in 23 cases (12.3%), and at the level of L5 vertebra in 33 cases (17.6%).

Conclusion: The precise location of aortic bifurcation is useful for surgeons in the anterior approach of the lumbosacral spine to prevent harmful vascular injury.

Keywords: Abdominal aortic bifurcation, Lumbosacral spine, Cadavers

J Med Assoc Thai 2009; 92 (1): 47-9

Full text. e-Journal: <http://www.mat.or.th/journal>

The laparoscopic approach has evolved to become one of the techniques of choice for performing anterior lumbosacral interbody fusion such as L₄-L₅ or L₅-S₁⁽¹⁾. Anterior interbody fusion has been used for the treatment of a variety of lesions such as spinal deformity^(2,3), spinal instability^(4,5), tumors, infection, and chronic disabling low back pain, including that arising from failed posterior back surgery and recently the lumbosacral total disc arthroplasty⁽⁶⁻⁸⁾. Vascular injury is the main complication of the anterior approach. Although major vascular injury is rare, they can rapidly cause a harmful hypovolemic shock. Serious morbidity or mortality can be the result^(9,10). The anatomical

variations of this vessel mainly the aorta increase the risk of vascular injury. The vascular anatomy and its relationship to the vertebra would provide useful information to the surgeon for the anterior lumbosacral approach. The aim of the present study was to assess the accurate site of aortic bifurcation.

Material and Method

The present study was approved by Ethics Committee on Human Specimen Research of Faculty of Medicine, Khon Kaen University, Thailand. One hundred and eighty seven embalmed adult human cadavers (132 men, 55 women). Cadavers had died between 30 to 88 years of age (average, 67.3 ± 0.8 years) with neither evidence of major vascular disease nor abnormality of the spine such as scoliosis. The dissections were performed by the anterior approach.

Correspondence to: Khamanarong K, Department of Anatomy, Faculty of Medicine, Khon Kaen University, Khon Kaen 40002, Thailand. Phone: 043-348-381, Fax: 043-348-381, E-mail: kkimap@kku.ac.th, kimapor@yahoo.com

Table 1. The site of aortic bifurcation in relation to the lumbar vertebral level

Level	Number of specimens		
	Male (%)	Female (%)	Total
L ₄ vertebral body	90 (48.2%)	41 (21.9%)	131 (70.1%)
4 th lumbar intervertebral disc	13 (6.9%)	10 (5.4%)	23 (12.3%)
L ₅ vertebral body	33 (17.6%)	0 (0%)	33 (17.6%)
Total	136 (72.7%)	51 (27.3%)	187 (100%)

The lumbar and sacral promontory regions were exposed after mobilization of the intestines. All the retroperitoneal structures were dissected. The aortic bifurcation was defined as the junction of the medial sides of the two common iliac arteries. The data were then analyzed using descriptive statistic and gross anatomy observation.

Results

The aortic bifurcation was found at the level of L4 vertebral body in 131 cases (70.12%) and at the fourth lumbar intervertebral disc in 23 cases (12.30%) and at the level of L5 vertebral body in 33 cases (17.6%), as shown in Table 1. The aortic bifurcation at the level of L5 vertebral body was mostly found in group 3; age 80-99 years old (Fig. 1).

Discussion

The increased difficulty and morbidity in a laparoscopic approach at L₄- L₅ has been linked to the prevertebral vascular anatomy and specifically at the level of bifurcation of the aorta. Access to this level requires careful dissection and mobilization of the vessels⁽¹¹⁾. The risk for vascular damage during anterior lumbosacral surgery varies from one to another patient depending on their vascular anatomy⁽¹²⁾.

Chithriki et al⁽¹³⁾ and Inamasu⁽¹⁴⁾ examined the level of the aortic bifurcation in subjects by MRI and computed tomography angiography, found that the aortic bifurcation at the L₄ vertebral body level in 67% and 55% of cases respectively. Kawahara et al⁽¹⁵⁾ studied 21 cadavers and reported the aorta descended and branched into two common iliac arteries at L₅ in one cadaver, at L₃, L₄ in two cadavers, at L₄ in eight cadavers, at L₄- L₅ in nine cadavers and at L₅ in one cadaver.

The results obtained from the present study agree with Chithriki et al. and Kawahara et al. In the present study of 187 subjects, the position of the aortic bifurcation was found downward with increased age

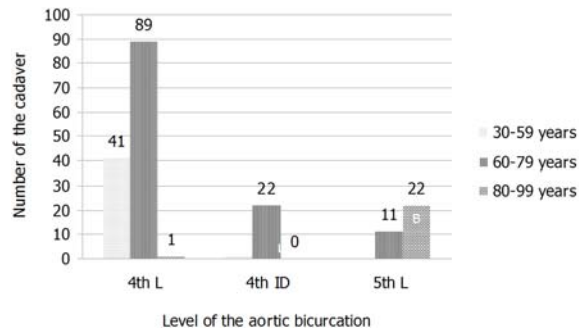


Fig. 1 Histogram of the total number of site of aortic bifurcation in each age group

(Fig. 1). Reduction in the length of the spine with aging is influencing the dynamic change of the intervertebral discs due to their loss of thickness, while osteopenia and osteoporosis of the vertebral result in loss of height. The loss of spinal height results in a caudal shift of the aortic bifurcation.

Conclusion

The precised location of aortic bifurcation is useful when invasive procedures are performed in the pelvis, laparoscopic lumbar discectomy, and lumbosacral total disc arthroplasty. It is also useful because anterior lumbar interbody fusion is gaining in popularity.

Acknowledgement

The authors wish to thank the Faculty of Medicine of Khon Kaen University for the financial support of this research.

References

1. Kleeman TJ, Hiscol AC. Critical analysis of laparoscopic ALIF vs. posterolateral fusion with instrumentation. Presented at the 14th Annual Meeting of the North American Spine Society.

- Hilton and Towers Chicago, Illinois; October 20-23, 1999.
2. Bradford DS. Adult scoliosis. Current concepts of treatment. Clin Orthop Relat Res 1988; (229): 70-87.
 3. Kostuik JP. Decision making in adult scoliosis. Spine 1979; 4: 521-5.
 4. Spencer DL, DeWald RL. Simultaneous anterior and posterior surgical approach to the thoracic and lumbar spine. Spine 1979; 4: 29-36.
 5. Grob D, Scheier HJ, Dvorak J, Siegrist H, Rubeli M, Joller R. Circumferential fusion of the lumbar and lumbosacral spine. Arch Orthop Trauma Surg 1991; 111: 20-5.
 6. Kozak JA, O'Brien JP. Simultaneous combined anterior and posterior fusion. An independent analysis of a treatment for the disabled low-back pain patient. Spine 1990; 15: 322-8.
 7. Kozak JA, Heilman AE, O'Brien JP. Anterior lumbar fusion options. Technique and graft materials. Clin Orthop Relat Res 1994; 45-51.
 8. Southerland SR, Remedios AM, McKerrell JG, Litwin D. Laparoscopic approaches to the lumbar vertebrae. An anatomic study using a porcine model. Spine 1995; 20: 1620-3.
 9. McAfee PC, Regan JR, Zdeblick T, Zuckerman J, Picetti GD III, Heim S, et al. The incidence of complications in endoscopic anterior thoracolumbar spinal reconstructive surgery. A prospective multi-center study comprising the first 100 consecutive cases. Spine 1995; 20: 1624-32.
 10. Zucherman JF, Zdeblick TA, Bailey SA, Mahvi D, Hsu KY, Kohrs D. Instrumented laparoscopic spinal fusion. Preliminary Results. Spine 1995; 20: 2029-34.
 11. Parke WW, Whalen JL, Van Demark RE, Kambin P. The infra-aortic arteries of the spine: their variability and clinical significance. Spine 1994; 19: 1-5.
 12. Tribus CB, Belanger T. The vascular anatomy anterior to the L5-S1 disk space. Spine 2001; 26: 1205-8.
 13. Chithriki M, Jaibaji M, Steele RD. The anatomical relationship of the aortic bifurcation to the lumbar vertebrae: a MRI study. Surg Radiol Anat 2002; 24: 308-12.
 14. Inamasu J, Kim DH, Logan L. Three-dimensional computed tomographic anatomy of the abdominal great vessels pertinent to L4-L5 anterior lumbar interbody fusion. Minim Invasive Neurosurg 2005; 48: 127-31.
 15. Kawahara N, Tomita K, Baba H, Toribatake Y, Fujita T, Mizuno K, et al. Cadaveric vascular anatomy for total en bloc spondylectomy in malignant vertebral tumors. Spine 1996; 21: 1401-7.

การศึกษาจุดแยกสองง่ามของหลอดเลือดแดงเอออร์ตาสัมพันธ์กับกระดูกสันหลัง

กิมพร ขมะณะรงค์, สุรัชชัย แซ่จิ่ง, จันทรศรี ศรีภักดิ์เรก, สุภาวดี ธีระกุล, ปาริฉัตร ประจจะเนย์

ปัญหาที่เป็นภาวะแทรกซ้อนหลัก เมื่อทำการผ่าตัดบริเวณด้านหน้าต่อกระดูกสันหลัง ระดับเอวร่วมกับกระดูกสันหลังระดับใต้กระเบนเหน็บ คือ การเกิดภัยอันตรายกับหลอดเลือดแดงเอออร์ตา ในการศึกษาครั้งนี้จึงได้ศึกษาจุดแยกสองง่ามของหลอดเลือดแดงเอออร์ตาที่สัมพันธ์กับระดับของกระดูกสันหลัง โดยศึกษากับศพดองผู้ใหญ่ จำนวน 187 ร่าง เพศชาย 132 ร่าง และเพศหญิง 55 ร่าง อายุเฉลี่ย 67.3 ปี (30-88 ปี) จากผลการศึกษาพบว่าจุดแยกสองง่ามของหลอดเลือดแดงเอออร์ตา พบที่กระดูกสันหลังระดับเอวชั้นที่ 4 ระดับหมอนรองกระดูกสันหลังระดับเอวที่ 4 และกระดูกสันหลังระดับเอวชั้นที่ 5 จำนวน 131 ร่าง (70.1%), 23 ร่าง(12.3%) และ 33 ร่าง(17.6%) ตามลำดับ ข้อมูลจากการศึกษาครั้งนี้จะเป็นประโยชน์สำหรับแพทย์ออร์โธพีดิกส์ และศัลยแพทย์ ในการทำหัตถการ บริเวณด้านหน้าต่อกระดูกสันหลังระดับเอวร่วมกับกระดูกใต้กระเบนเหน็บ