

# Case Report

## Optic Neuritis in a Patient with Miller-Fisher Syndrome<sup>†</sup>

Praween Lolekha MD\*,  
Kammant Phanthumchinda MD\*

<sup>†</sup>This manuscript was presented at 7<sup>th</sup> ASEAN Neurological Association (ASNA) Convention & 47<sup>th</sup> Annual Meeting of the Neurological Society of Thailand, March 2007

\* Division of Neurology, Department of Internal Medicine, Faculty of Medicine, Chulalongkorn University, Bangkok

---

Miller-Fisher syndrome (MFS) is considered a variant of Guillain-Barré syndrome (GBS). The syndrome is characterized by acute onset of gait ataxia, ophthalmoplegia, and areflexia. Conventionally, MFS has been considered exclusively a disease of the peripheral nervous system. However, there are occasional reports of central nervous system involvement. Here, a 62 year-old woman who presented with classical features of MFS and progressive bilateral dyschromatopsia and reported visual impairment. Normal MRI of the brain and CSF albumino-cytologic dissociation were observed. CSF oligoclonal IgG pattern indicated a passive transfer of oligoclonal IgG from a systemic inflammatory response. Nerve conduction studies showed slow motor conduction velocity in her extremities. The optic fundi were normal. Visual evoked potentials (VEPs) revealed bilateral optic neuropathy. Marked spontaneous improvement of her syndrome was documented within six weeks. Optic neuritis may be a central nervous system feature that should be recognized as part of the MFS.

**Keywords:** Miller-Fisher syndrome, Optic neuritis

*J Med Assoc Thai* 2008; 91 (12): 1909-14

Full text. e-Journal: <http://www.medassocthai.org/journal>

---

Miller-Fisher syndrome (MFS), a variant of Guillain-Barré syndrome (GBS) was first described clinically in 1956<sup>(1)</sup>. The incidence rate in Thailand has not been established but it occurred approximately 1-5% that of GBS in Western countries<sup>(2)</sup>. While the incidence of GBS is broadly the same throughout the world, the incidence of MFS as a proportion of GBS has been reported to be higher in Eastern Asia<sup>(3)</sup>. MFS can be associated with infectious, autoimmune, and neoplastic disorders<sup>(4)</sup>. Conventionally, MFS has been considered a disease exclusively of the peripheral nervous system. However, there are occasional reports of central nervous system involvement such as cerebellar ataxia, supranuclear gaze palsy, and optic neuropathy<sup>(5)</sup>. Several magnetic resonance imaging (MRI) studies have also shown central nervous system abnormalities in MFS<sup>(6-11)</sup>, which suggests that central lesions also are responsible for some clinical aspects

of MFS. Optic nerve involvement is rarely reported in MFS. Only seven reports have been documented in the literature since 1979<sup>(5,9,12-16)</sup> (Table 1).

### Case Report

A 62-year old, previously healthy woman was admitted to King Chulalongkorn Memorial Hospital because of progressive blurring of vision and headache. One week prior to admission, she had a low-grade fever, diffuse headache, ocular pain, nausea, vomiting, and loss of appetite. Four days later, fever and headache were spontaneously subsided but she began to notice diplopia, blurred vision, drooping of both eyelids, and mild ataxia. She did not complain of vertigo, weakness, or numbness of her limbs. Her vital signs, general physical examination were normal. Her consciousness was alert with normal speech. Her corrected visual acuity declined from 20/70 bilaterally to 20/400 on the right and 20/200 on the left within one week. She had marked dyschromatopsia. The optic fundi were normal. Total ophthalmoplegia, bilateral incomplete ptosis, and fixed dilated pupils of 6 mm were observed (Fig. 1). The

---

Correspondence to: Phanthumchinda K, Division of Neurology, Department of Internal Medicine, Faculty of Medicine, Chulalongkorn University, Bangkok 10330, Thailand. E-mail: [fmedkpt@md2.md.chula.ac.th](mailto:fmedkpt@md2.md.chula.ac.th)

**Table 1.** Optic neuropathy with Miller-Fisher syndrome

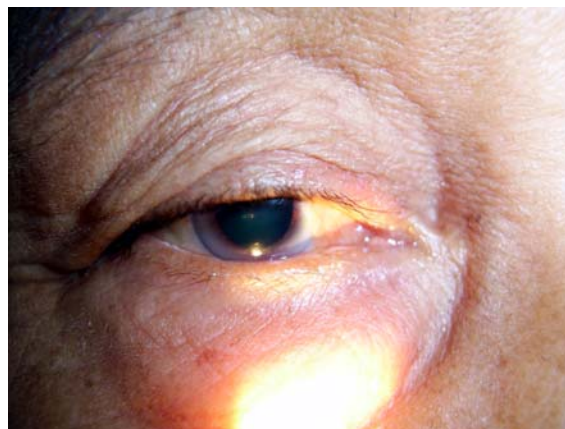
Authors	Age (years)	Sex	Laterality of visual dysfunction	Visual acuity	Fundus	VEP P100 latency	Electro-diagnostic test	Imaging of the brain	CSF examination	Anti-GQ1b	Outcome
Williams et al <sup>(16)</sup>	18	F	Bilateral	OU: HM	Exudate over disc	N/A	N/A	Normal	Normal CSF profile	N/A	Improve in 12 weeks
Toshniwal <sup>(6)</sup>	76	F	Bilateral	OU: 20/800	Normal	Delay	Prolong DML, NCV	Normal	Acellular Protein 51 mg/dl Glucose normal	N/A	Improve in 8 weeks
Ouhabi et al <sup>(9)</sup>	N/A	N/A	Bilateral	N/A	N/A	N/A	N/A	Pontomesencephalic abnormalities	N/A	N/A	N/A
Colding-Jorgensen et al <sup>(14)</sup>	57	F	Bilateral	OU: 6/24	Normal	N/A	Normal	MRI: Normal	Acellular Protein 39 mg/dl Glucose normal	Positive	Rx: IVIg Improve in 3 weeks
Carvalho et al <sup>(12)</sup>	24	M	Bilateral	N/A	Pale disc	Delay	Normal	MRI: Normal	Acellular Protein high Glucose normal	N/A	Improve in 12 weeks
Sasaki et al <sup>(15)</sup>	38	F	Bilateral	N/A	Normal	N/A	N/A	MRI: Normal	N/A	Positive	Rx: Plasmapheresis Improve in 8 weeks
Chan <sup>(13)</sup>	23	F	Unilateral	OD: 20/20 OS: 20/200	N/A	Delay	Prolong DML, NCV	MRI: Normal	Acellular Protein 70 mg/dl Glucose normal	Positive	Rx: Plasmapheresis Improve in 8 weeks
Present case	62	F	Bilateral	OD: 20/400 OS: 20/200	Normal	Delay	Prolong DML, NCV, F wave	MRI: Normal	Acellular Protein 66 mg/dl Glucose normal	N/A	Improve in 6 weeks

N/A : Not available, OD = right eye, OS = left eye, OU = both eyes

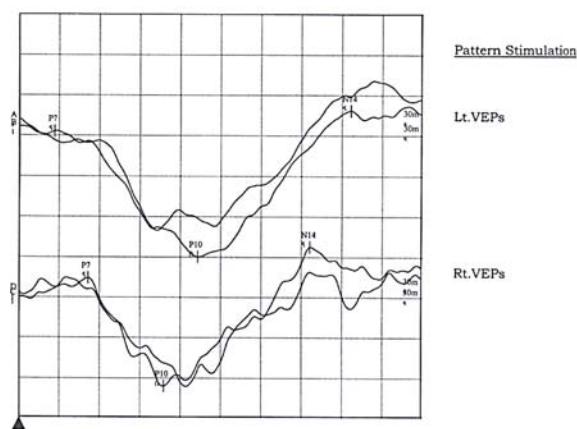
pupils were not reactive to light and accommodation. Facial, trigeminal, and other cranial nerves were normal. She did not have motor deficit but hypoactive deep tendon reflexes and bilateral plantar response. Mild disequilibrium was present and finger-nose tests showed mild dysmetria. Sensory abnormality was not detected. Laboratory investigations showed normal blood counts, plasma glucose, BUN, creatinine, electrolytes and liver function tests. Cerebrospinal fluid examination on day 7 of the illness showed normal opening pressure, total protein of 45 mg/dl, glucose of 72 mg/dl with plasma glucose of 112 mg/dl and no cell. Repeated cerebrospinal fluid examination on day 10 showed mild elevated protein of 66mg/dl, CSF glucose and cell count were normal. CSF VDRL, Gram stain for bacterial, viral studies and CSF culture for bacteria and fungus were all negative. The CSF oligoclonal IgG pattern was similar to the serum oligoclonal IgG pattern, which indicated a passive transfer of oligoclonal IgG from systemic inflammatory response. CT and MRI of the brain were normal. Visual evoked potentials (VEPs) showed delayed P100 latencies at 107.7ms on the right and 132.9ms on the left (Fig. 2). Nerve conduction studies showed prolonged distal motor latencies [Median: 4.6 ms; Ulnar: 3.3 ms], slow motor conduction velocities [Median: 41.8m/s; Ulnar: 42.6m/s] and prolonged F-waves[Median: 37.3 msec; Ulnar: 34.8 msec]. Sensory potentials could not be obtained from median or ulnar nerves. She did not receive any specific treatment due to spontaneous improvement of her clinical syndrome after two weeks. Follow-up examination six weeks later, showed visual acuity of 20/70 on the right and 20/100 on the left. Extraocular movements, gait, and reflexes were normal. She is still healthy and has had no recurrent symptoms after one year follow-up.

## Discussion

Miller Fisher syndrome (MFS) is characterized by ophthalmoplegia, ataxia, and areflexia<sup>(1)</sup>. MFS can occur at any age, but most commonly presents in the fourth and fifth decades. About 70% of patients have an antecedent infection with mean interval of 10 days<sup>(17)</sup>. The preceding specific infection included *Hemophilus influenzae*<sup>(18,19)</sup>, *Campylobacter jejuni*<sup>(18,19)</sup>, *Mycoplasma pneumoniae*<sup>(20,21)</sup>, *Pasteurella multocida*<sup>(22)</sup>, *Helicobacter pylori*<sup>(23)</sup>, *Escherichia coli*<sup>(24)</sup>, human immunodeficiency virus<sup>(25)</sup>, and Epstein-Barr virus<sup>(26)</sup>. However, most of the patients experience a non-specific viral infection before MFS<sup>(3)</sup>. Molecular mimicry has been shown to be the likely mechanism by which infective agents trigger an immunological reaction<sup>(19)</sup>. CSF



**Fig. 1** Incomplete ptosis and pupil dilatation of the right eye



**Fig. 2** Visual evoked potentials shows delayed P100 latencies

examination commonly yields the characteristic finding of albumino-cytologic dissociation that is also typical for GBS<sup>(1)</sup>. Electrodiagnosis of the limbs can be variable but they appear to be related with the clinical symptomatology. Some reports show conduction block or even the evidence of axonal damage<sup>(27)</sup>. Radiological findings are unremarkable in most cases of MFS. Several reports of MRI findings associated with MFS showed lesions in the brainstem, cerebral white matter, spinocerebellar tract, and cerebellum providing evidence supporting central nervous involvement<sup>(6-11)</sup>. MFS usually follows a benign course and most patients make a good recovery within ten weeks<sup>(28)</sup>. Treatment is mainly supportive. Both intravenous immunoglobulin and plasmapheresis, which show benefit in GBS, have also been used in MFS. The predominant clinical

features in the present case, including ataxia, areflexia, and ophthalmoplegia. Furthermore, CSF findings and electrodiagnostic tests were consistent with a diagnosis of MFS. This case may be related to non-specific antecedent viral infection, and had a benign course with good spontaneous improvement.

Although MFS is considered a disorder of the peripheral nervous system, there were occasional reports of central nervous system involvement such as optic neuropathy (Table 1). Seven cases of visual impairment in MFS have been documented in the literature since 1979. Most of them were female, with the mean age of 39 years (range 18-76). Only one case reported unilateral visual dysfunction<sup>(13)</sup> while the others showed bilateral visual involvement. One report provided evidence of the association between pelvic infection, optic neuritis, and ophthalmoparesis<sup>(16)</sup>. Demyelinating optic neuropathies confirmed by VEP were reported in three patients with MFS<sup>(5,12,13)</sup>. The visual impairment was improved after three months of conservative treatment in two cases<sup>(5,12)</sup> and the others improved after plasmapheresis or IVIg<sup>(13-15)</sup>. One case reported ponto-mesencephalic abnormalities on MRI<sup>(9)</sup>. The visual dysfunction in the presented case is characterized by markedly decreased visual acuity, dyschromatopsia, and delayed VEPs, indicating demyelinating optic neuropathy. The onset and gradual spontaneous recovery of visual dysfunction paralleled with other clinical abnormalities typical for MFS, suggesting more than a chance association.

Anti-GQ1b antibody is well known to be associated with MFS<sup>(4)</sup> and is present in more than 90% of patients with MFS<sup>(14,29)</sup>. Anti-GQ1b IgG antibody titers, which can cross blood-brain barrier peak at clinical presentation, decline rapidly during the course of recovery, and become undetectable as early as one month after onset<sup>(30)</sup>. The ganglioside GQ1b is abundant in cranial nerves supplying extraocular muscles, human optic nerve, and the presynaptic neuromuscular junction<sup>(31)</sup>. Recent studies presumed optic neuritis in MFS were also associated with anti-GQ1b antibody<sup>(2,13,14,32-34)</sup>. Three cases of optic neuropathies were associated with anti-GQ1b positive MFS<sup>(13-15)</sup>. Anti-GQ1b antibody was also found in patients with related conditions that share the same pathogenesis, including GBS and Bickerstaff's brainstem encephalitis (BBE)<sup>(35,36)</sup>. Unfortunately, the test for this antibody is not available in Thailand. The present case report emphasizes that optic neuritis may be a central nervous system feature that should be recognized as part of the MFS.

## References

1. Fisher M. An unusual variant of acute idiopathic polyneuritis (syndrome of ophthalmoplegia, ataxia and areflexia). *N Engl J Med* 1956; 255: 57-65.
2. Arnason G. Acute inflammatory demyelinating polyneuropathy. In: Dyck PJ, Griffin JW, Low PA, Poduslo JF, editors. *Peripheral neuropathy*. 3<sup>rd</sup> ed. Philadelphia: Saunders; 1993: 1437-97.
3. Mori M, Kuwabara S, Fukutake T, Yuki N, Hattori T. Clinical features and prognosis of Miller Fisher syndrome. *Neurology* 2001; 56: 1104-6.
4. Lo YL. Clinical and immunological spectrum of the Miller Fisher syndrome. *Muscle Nerve* 2007; 36: 615-27.
5. Toshniwal P. Demyelinating optic neuropathy with Miller-Fisher syndrome. The case for overlap syndromes with central and peripheral demyelination. *J Neurol* 1987; 234: 353-8.
6. Echaniz-Laguna A, Battaglia F, Heymann R, Tranchant C, Warter JM. The Miller Fisher syndrome: neurophysiological and MRI evidence of both peripheral and central origin in one case. *J Neurol* 2000; 247: 980-2.
7. Giroud M, Mousson C, Chalopin JM, Rifle G, Dumas R. Miller-Fisher syndrome and pontine abnormalities on MRI: a case report. *J Neurol* 1990; 237: 489-90.
8. Inoue N, Ichimura H, Goto S, Hashimoto Y, Ushio Y. MR imaging findings of spinal posterior column involvement in a case of Miller Fisher syndrome. *AJNR Am J Neuroradiol* 2004; 25: 645-8.
9. Ouhabi H, Bourazza A, Rouimi A, Boutaleb N, Mosseddaq R. [Bilateral optic neuritis and ponto-mesencephalic involvement shown by MRI in Miller-Fisher syndrome]. *Rev Neurol (Paris)* 1998; 154: 780-2.
10. Urushitani M, Udaka F, Kameyama M. Miller Fisher-Guillain-Barre overlap syndrome with enhancing lesions in the spinocerebellar tracts. *J Neurol Neurosurg Psychiatry* 1995; 58: 241-3.
11. Tezer FI, Gurer G, Karatas H, Nurlu G, Saribas O. Involvement of the central nervous system in Miller Fisher syndrome: a case report. *Clin Neurol Neurosurg* 2002; 104: 377-9.
12. Carvalho AA, Galvao MD, Rocha MS, Piccolo AC, Maia SC. Miller fisher syndrome and optic neuritis: case report. *Arq Neuropsiquiatr* 2000; 58: 1115-7.
13. Chan JW. Optic neuritis in anti-GQ1b positive recurrent Miller Fisher syndrome. *Br J Ophthalmol* 2003; 87: 1185-6.

14. Colding-Jorgensen E, Vissing J. Visual impairment in anti-GQ1b positive Miller Fisher syndrome. *Acta Neurol Scand* 2001; 103: 259-60.
15. Sasaki Y, Takubo H, Arai T, Machida Y, Ikebe S, Yuki N, et al. Atypical Fisher syndrome with optic nerve involvement. *No To Shinkei* 2001; 53: 571-3.
16. Williams B, Ghosh TN, Stockley RA. Ophthalmoplegia, amblyopia, and diffuse encephalomyelitis associated with pelvic abscess. *Br Med J* 1979; 1: 453.
17. Berlit P, Rakicky J. The Miller Fisher syndrome. Review of the literature. *J Clin Neuroophthalmol* 1992; 12: 57-63.
18. Overell JR, Willison HJ. Recent developments in Miller Fisher syndrome and related disorders. *Curr Opin Neurol* 2005; 18: 562-6.
19. Koga M, Gilbert M, Li J, Koike S, Takahashi M, Furukawa K, et al. Antecedent infections in Fisher syndrome: a common pathogenesis of molecular mimicry. *Neurology* 2005; 64: 1605-11.
20. Merckx H, De Keyser J, Ebinger G. Miller Fisher syndrome associated with *Mycoplasma pneumoniae* infection: report of a case. *Clin Neurol Neurosurg* 1994; 96: 96-9.
21. Henderson RD, Ohlrich GD, Pender MP. Guillain-Barre syndrome and optic neuritis after *Mycoplasma pneumoniae* infection. *Aust N Z J Med* 1998; 28: 481-2.
22. Bennetto LP, Lyons P. Miller Fisher syndrome associated with *Pasteurella multocida* infection. *J Neurol Neurosurg Psychiatry* 2004; 75: 1786-7.
23. Chiba S, Sugiyama T, Yonekura K, Tanaka S, Matsumoto H, Fujii N, et al. An antibody to VacA of *Helicobacter pylori* in the CSF of patients with Miller-Fisher syndrome. *Neurology* 2004; 63: 2184-6.
24. Blasetti A, Cerruto M, Cutarella R, Tocco A, Caporale MC, Chiarelli F, et al. Miller Fisher syndrome and *Escherichia coli* infection: is it a novel association? *J Child Neurol* 2007; 22: 71-3.
25. Arranz Caso JA, Martinez R, Cabrera F, Tejeiro J. Miller Fisher syndrome in a patient with HIV infection. *AIDS* 1997; 11: 550-1.
26. Schnorf H, Rathgeb JP, Kohler A. Anti-GQ1b-positive Miller Fisher syndrome in a patient with acute Epstein-Barr virus infection and negative *Campylobacter* serology. *Eur Neurol* 1998; 40: 177.
27. Calleja J, Garcia A, de Pablos C, Polo JM. Miller-Fisher syndrome: electrophysiological serial study of five patients. *Rev Neurol* 1998; 27: 60-4.
28. Bussin J. Miller Fisher syndrome in an elderly man. *Age Ageing* 2001; 30: 268-9.
29. Chiba A, Kusunoki S, Shimizu T, Kanazawa I. Serum IgG antibody to ganglioside GQ1b is a possible marker of Miller Fisher syndrome. *Ann Neurol* 1992; 31: 677-9.
30. Odaka M, Koga M, Yuki N, Susuki K, Hirata K. Longitudinal changes of anti-ganglioside antibodies before and after Guillain-Barre syndrome onset subsequent to *Campylobacter jejuni* enteritis. *J Neurol Sci* 2003; 210: 99-103.
31. Chiba A, Kusunoki S, Obata H, Machinami R, Kanazawa I. Ganglioside composition of the human cranial nerves, with special reference to pathophysiology of Miller Fisher syndrome. *Brain Res* 1997; 745: 32-6.
32. Chiba A, Kusunoki S, Obata H, Machinami R, Kanazawa I. Serum anti-GQ1b IgG antibody is associated with ophthalmoplegia in Miller Fisher syndrome and Guillain-Barre syndrome: clinical and immunohistochemical studies. *Neurology* 1993; 43: 1911-7.
33. Suzuki T, Chiba A, Kusunoki S, Chikuda M, Fujita T, Misu K. Anti-GQ1b ganglioside antibody and ophthalmoplegia of undetermined cause. *Br J Ophthalmol* 1998; 82: 916-8.
34. Willison HJ. Ganglioside complexes as targets for antibodies in Miller Fisher syndrome. *J Neurol Neurosurg Psychiatry* 2006; 77: 1002-3.
35. Yuki N, Wakabayashi K, Yamada M, Seki K. Overlap of Guillain-Barre syndrome and Bickerstaff's brainstem encephalitis. *J Neurol Sci* 1997; 145: 119-21.
36. Williams MH. The spectrum of IgG GQ1(b) syndrome: an unusual cluster. *J Clin Neurosci* 2001; 8: 315-8.



---

## เส้นประสาทตาอักเสบในผู้ป่วยกลุ่มอาการมิลเลอร์ ฟิชเชอร์

ประวีณ โฉมเลขา, กัมมันต์ พันธุมจินดา

กลุ่มอาการมิลเลอร์ ฟิชเชอร์ เป็นกลุ่มอาการผันแปรชนิดหนึ่งของ กลุ่มอาการกิแลงแบเร ประกอบด้วยอาการแสดงหลัก 3 อย่าง ได้แก่ อาการเดินเซ กล้ามเนื้ออ่อนแอ การเคลื่อนไหวของตาเป็นอัมพาต และภาวะไม่มีปฏิกิริยาของเส้นเอ็น เดิมเชื่อว่ากลุ่มอาการนี้เกิดจากความผิดปกติของระบบประสาทส่วนปลายเพียงอย่างเดียว แต่ในปัจจุบันพบรายงานผู้ป่วยที่มีความผิดปกติของระบบประสาทส่วนกลางร่วมด้วยเป็นครั้งคราว รายงานผู้ป่วยหญิงไทย อายุ 62 ปี มีอาการของกลุ่มอาการ มิลเลอร์ ฟิชเชอร์ที่เป็นแบบฉบับ อาการตาบอดสี และอาการตามัวที่เป็นมากขึ้น จากการตรวจภาพถ่ายรังสีแม่เหล็ก ไม่พบความผิดปกติ การตรวจน้ำไขสันหลังพบความไม่สัมพันธ์ของจำนวนเซลล์และโปรตีน ตรวจพบโอลิโกโคลโน ในน้ำไขสันหลังมีรูปแบบที่แสดงว่าโปรตีนดังกล่าวเข้าสู่ไขสันหลังจากอักเสบในส่วนอื่นของร่างกาย การตรวจความไวของการนำไฟฟ้าของเส้นประสาท พบว่ามี การนำไฟฟ้าของเส้นประสาทที่รยางค์ช้ากว่าปกติ จากการตรวจจอบประสาทตาไม่พบความผิดปกติ การตรวจความไวของเส้นประสาทตาทางไฟฟ้าโดยการกระตุ้น พบความผิดปกติเกิดที่บริเวณเส้นประสาทตาทั้ง 2 ข้าง กลุ่มอาการของผู้ป่วยดีขึ้นเองภายในเวลา 6 สัปดาห์ รายงานนี้แสดงให้เห็นว่าเส้นประสาทตาอักเสบอาจเป็นอาการทางระบบประสาทส่วนกลางที่พบได้ในผู้ป่วยกลุ่มอาการมิลเลอร์ ฟิชเชอร์

---