

Nomograms of the Fetal Heart between 16 and 39 Weeks of Gestation

Athita Chanthasenanont MD*,
Charintip Somprasit MD*, Densak Pongroj paw MD*

* Division of Maternal-Fetal-Medicine, Department of Obstetrics and Gynecology, Thammasat University, Pathumthani

Objective: To establish the normal fetal cardiac measurement from 16 to 39 weeks' gestation in Thai fetuses.
Material and Method: Four hundred and eighty normal singleton pregnant women were recruited into the present study. The sonographic measurements were obtained from axial scans at the level of the four-chamber view.

Results: The regression model for cardiac circumference (CC), thoracic circumference (TC), thickness of left ventricular wall during diastole (LVW), diameter of left ventricle during diastole (LVD) and systole (LVS) and thickness of interventricular septum during diastole (IVS) were best fit by allowing a polynomial for gestational age. The cardiothoracic ratio (CTR) and shortening fraction of left ventricle (SFLV) were not statistically different with advancing gestation.

Conclusion: The normal values of fetal CC, TC, CTR, LVW, LVD, LVS, IVS and SFLV during gestation were established. These data could serve as a standard to investigate cardiac change in pregnancies with fetuses at risk.

Keywords: Fetal echocardiography, Cardiothoracic circumference ratio, Left ventricular wall thickness, Interventricular septal thickness, Shortening fraction of left ventricle

J Med Assoc Thai 2008; 91 (12): 1774-8

Full text. e-Journal: <http://www.medassocthai.org/journal>

Fetal echocardiography has been proven to be an accurate method for the prenatal detection of most congenital heart defect⁽¹⁻³⁾. The four-chamber view is now considered to be an integral part of the fetal examination even when performed by an examiner who is not specialized in fetal echocardiography. A normal range for fetal cardiac measurements is a basic requirement for the sonologist performing fetal echocardiography. In many situations such as hydrops fetalis, some cardiac malformations, congenital cystic adenomatoid malformation (CCAM) or skeletal dysplasia, fetal cardiothoracic ratio may be either large or abnormally small. While, in some conditions for example cardiomyopathy in infants of insulin-dependent diabetic mothers has thick interventricular septum^(4,5). Even though, while fetal sonographic examination is

performed, measuring the cardiac chambers or cardiothoracic ratio or thickness of ventricular wall or interventricular septum is not necessary on a routine basis for the experienced sonologist. However, when abnormal sizes or ratios or dimensions are visually suspected, nomograms become mandatory.

Although there are reports presented about fetal cardiovascular dimensions in Thai fetuses^(6,7) the information in this field is still limited. Thus, the present study was conducted to establish the nomogram of fetal cardiac circumference (CC), thoracic circumference (TC), cardiothoracic ratio (CTR), thickness of left ventricular wall (LVW) during diastole, left ventricular dimension during diastole (LVD) and systole (LVS), thickness of interventricular septum (IVS) during diastole and shortening fraction of left ventricle (SFLV) between 16-39 weeks of gestation, using conventional sonographic techniques. These data could serve as a standard to investigate cardiac change in pregnancies with fetuses at risk.

Correspondence to: Chanthasenanont A, Division of Maternal-Fetal Medicine, Department of Obstetrics and Gynecology, Thammasat University, Bangkok 12120, Thailand. E-mail: athitaka@gmail.com

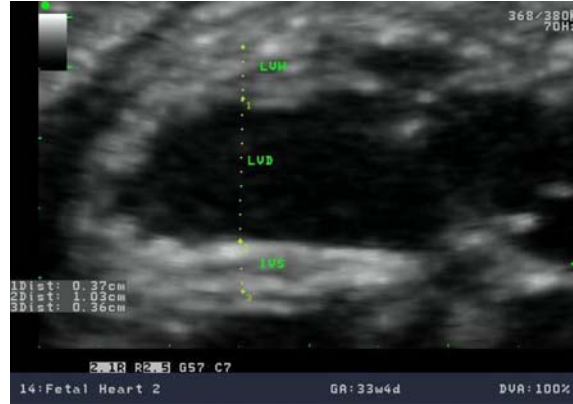Material and Method

The present study was conducted as a descriptive study. After obtaining approval from the Ethical Committee of Faculty of Medicine, Thammasat University, the authors recruited normal Thai pregnant women between 16 and 39 weeks of gestation who routinely attended the antenatal clinic at Thammasat University Hospital, Thailand from February to June 2008. All had a reliable menstrual history, singleton, uncomplicated pregnancy, normal growth and structural scanning. Fetuses with abnormal karyotypes were excluded. In cases of potential gestational diabetes, all had negative diabetic screening at 24-28 weeks of gestation. The only medications taken by these subjects were prenatal vitamins. Birth information and discharge summaries were reviewed. Written informed consent was obtained from each mother participating in the present study.

Fetal ultrasound studies were performed on all fetuses with a coaxial pulsed Doppler color flow imaging system (Aloka ProSound SSD- α 5sv Tokyo, Japan) employing 3.5-7.5 MHz transducer. Two-dimensional structural identification of the fetus was accomplished.

The parameters studied were the gestational age, fetal cardiac circumference (CC), thoracic circumference (TC), cardiothoracic ratio (CTR), thickness of left ventricular wall (LVW) during diastole, left ventricular dimension during diastole (LVD) and systole (LVS), thickness of interventricular septum (IVS) during diastole and shortening fraction of left ventricle (SFLV). The CC, TC, TCR, LVW, LVD and IVS were obtained in a four-chamber view of the fetal heart at end diastole while the LVS was obtained at end systole, using scene loop. The LVW, LVD, LVS and IVS were measured when ultrasound beam was placed perpendicular to the interventricular septum and image was magnified as Fig. 1. All measurements were obtained by one sonologist.

The nomograms for CC, TC, LVW, LVD, LVS and IVS against gestation were constructed by using the Statistical Package for the Social Sciences 13.0 (SPSS Inc, Chicago, IL, USA). A power analysis revealed that a sample size of at least 176 fetuses would be sufficient to have 90% confidence in detecting a relationship of at least 0.50 at $p \leq 0.05$ between these parameters at various gestational ages. Descriptive results of baseline and outcome characteristics used range, mean and standard deviation (SD). Linear regression and coefficient of determination were used to examine the relationship between these parameters



LVW, thickness of left ventricular wall during diastole; LVD, left ventricular dimension during diastole; IVS, thickness of interventricular septum during diastole

Fig. 1 The LVW, LVD, and IVS were measured when ultrasound beam was placed perpendicular to the interventricular septum and image was magnified

and gestational age. The CTR and SFLV were reported as range, mean and SD.

Results

There were 492 normal fetuses age 16 to 39 weeks included in the present study. The data could not be obtained from 12 fetuses due to suboptimal fetal position and maternal obesity leaving 480 cases for analysis.

Demographic characteristics of the study population are presented in Table 1. The number of subjects according to gestational age is shown in Table 2. Discharge summaries revealed no newborn with any clinical evidences of cardiac abnormalities.

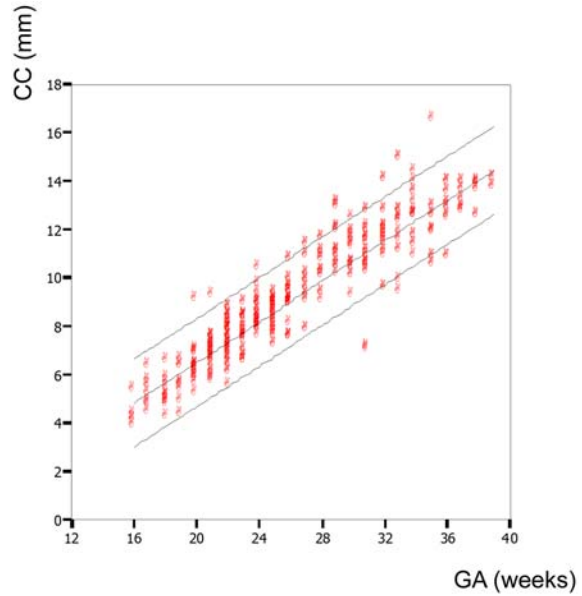
The regression model for CC, TC, LVW, LVD, LVS and IVS were best fit by allowing a polynomial for gestational age as Fig. 2-7. The coefficients of determination (r^2) between the CC, TC, LVW, LVD, LVS and

Table 1. Demographic characteristics of the study population

Characteristics	Mean \pm SD	Range
Maternal age (years)	28.21 \pm 6.11	15-43
Gestational age at examination (weeks)	26.41 \pm 5.51	16-39
Gestational age at delivery (weeks)	38.10 \pm 1.68	31-42
Birth weight at delivery (g)	3120.00 \pm 442.66	1720-3990

Table 2. Number of subjects according to gestational age

GA (weeks)	n	Percent
16.00	5	1.0
17.00	7	1.5
18.00	11	2.3
19.00	10	2.1
20.00	22	4.6
21.00	33	6.9
22.00	53	11.0
23.00	39	8.1
24.00	36	7.5
25.00	35	7.3
26.00	30	6.3
27.00	18	3.8
28.00	17	3.5
29.00	19	4.0
30.00	18	3.8
31.00	22	4.6
32.00	20	4.2
33.00	17	3.5
34.00	17	3.5
35.00	15	3.1
36.00	14	2.9
37.00	10	2.1
38.00	8	1.7
39.00	4	0.8



CC, cardiac circumference; GA, gestational age

Fig. 2 Individual values for the cardiac circumference during gestation with mean, 5th and 95th percentiles from the regression analysis

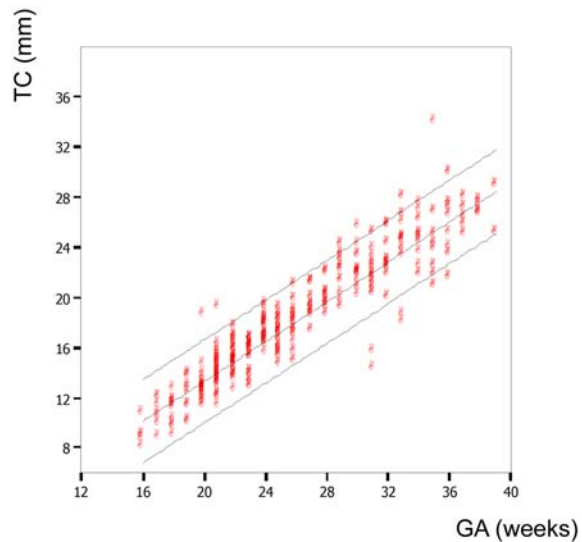
IVS and gestational age were 0.86, 0.87, 0.86, 0.61, 0.53 and 0.83, respectively.

The CTR and SFLV were not statistically different with advancing gestation. The ranges of the CTR and SFLV were 0.42 to 0.57 and 0.29 to 0.75, respectively.

Discussion

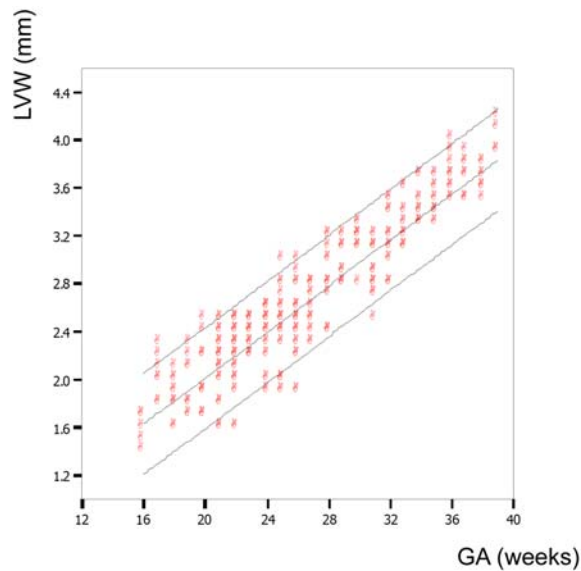
The normal values of fetal cardiac structures in a Thai population from 16 to 39 weeks' gestation were established.

Part of the routine fetal anatomic sonography includes an evaluation of the size of the heart and the relative size of the ventricular chambers⁽⁸⁾. In general, fetal heart size can be gauged by visually comparing to the thorax. The area of the fetal heart is about one-third of the thorax or the cardiothoracic ratio is about 50 percent⁽⁹⁾. Actual measurement of heart size or cardiac chambers or thickness of ventricular septum on a routine basis is too time consuming for ultrasonologists involved in routine fetal screening. However, in case of an abnormality is suspected, measurement can be useful in confirming this impression and



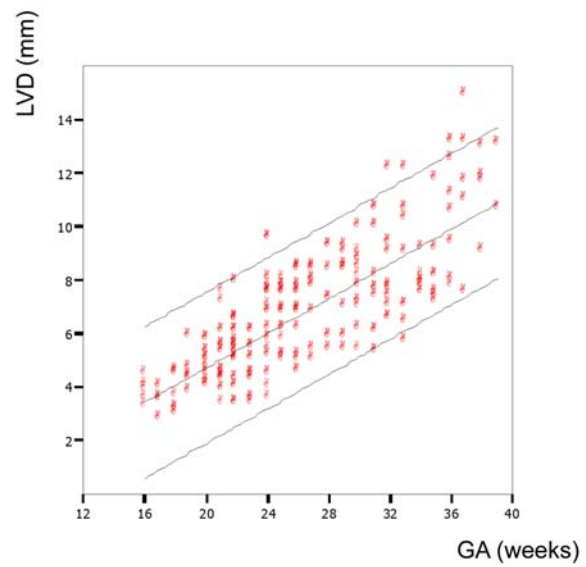
TC, thoracic circumference; GA, gestational age

Fig. 3 Individual values for the thoracic circumference during gestation with mean, 5th and 95th percentiles from the regression analysis



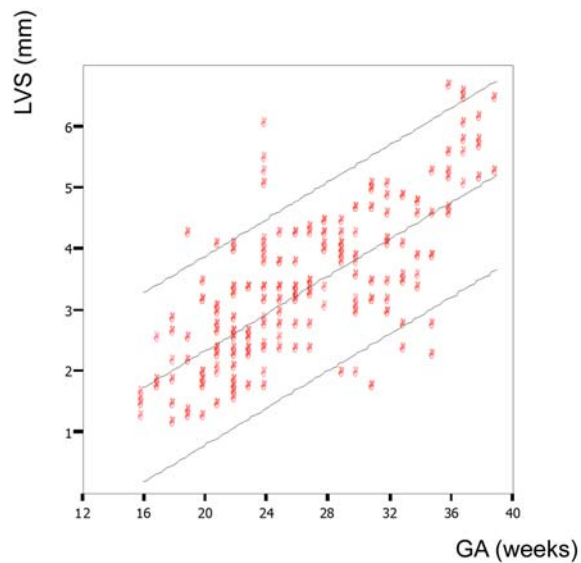
LVW, thickness of left ventricular wall during diastole; GA, gestational age

Fig. 4 Individual values for the thickness of left ventricular wall during diastole during gestation with mean, 5th and 95th percentiles from the regression analysis



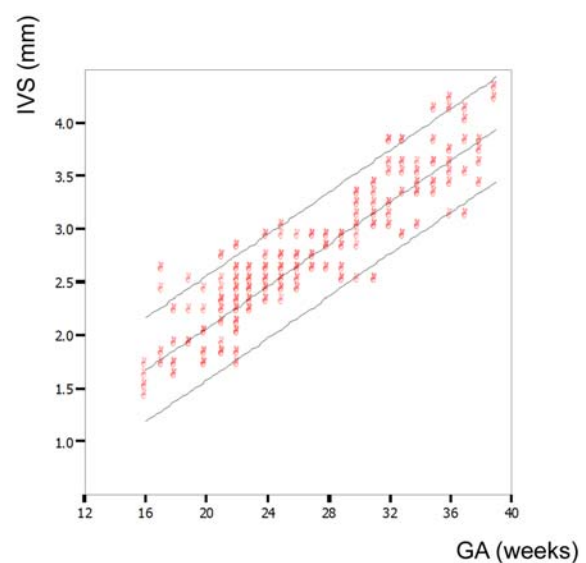
LVD, left ventricular dimension during diastole; GA, gestational age

Fig. 5 Individual values for the thickness of left ventricular dimension during diastole during gestation with mean, 5th and 95th percentiles from the regression analysis



LVS, left ventricular dimension during systole; GA, gestational age

Fig. 6 Individual values for the thickness of left ventricular dimension during systole during gestation with mean, 5th and 95th percentiles from the regression analysis



IVS, thickness of interventricular septum during diastole; GA, gestational age

Fig. 7 Individual values for the thickness of thickness of interventricular septum during diastole during gestation with mean, 5th and 95th percentiles from the regression analysis

altering to the further evaluation by a fetal echocardiographer.

Because the M-mode tracing has become less frequently used recently and, as tracings must be obtained with the M-line perpendicular to the interventricular septum, this can be difficult to achieve in every fetus and may be difficult to understand. The authors measured the thickness of ventricular wall and interventricular septum by using 2-D gray scale imaging. There is evidence that the cardiac measurement from 2-D gray scale ultrasound has good correlation with M-mode^(2,10).

The authors' data shows the fetal CC, TC, LVW, LVD, LVS and IVS are polynomial pattern for gestational age as support previous studies^(6,10). The authors also show the normal values of fetal CTR and SFLV.

These data could serve as a standard to investigate cardiac change in pregnancies with fetuses at risk of cardiac abnormalities.

Acknowledgement

This research was supported by a grant by Thammasat University in 2008.

References

1. Shapiro I, Degani S, Sharif D, Sharf M. Fetal echocardiography. Harefuah 1991; 120: 431-5.
2. Allan LD, Joseph MC, Boyd EG, Campbell S, Tynan M. M-mode echocardiography in the developing human fetus. Br Heart J 1982; 47: 573-83.
3. DeVore GR, Donnerstein RL, Kleinman CS, Platt LD, Hobbins JC. Fetal echocardiography. I. Normal anatomy as determined by real-time - directed M-mode ultrasound. Am J Obstet Gynecol 1982; 144: 249-60.
4. Pildes RS. Infants of diabetic mothers. N Engl J Med 1973; 289: 902-4.
5. Mace S, Hirschfield SS, Riggs T, Fanaroff AA, Merkatz IR. Echocardiographic abnormalities in infants of diabetic mothers. J Pediatr 1979; 95: 1013-9.
6. Patchakapat L, Uerpairojkit B, Wacharaprechanont T, Manotaya S, Tanawattanacharoen S, Charoenvidhya D. Interventricular septal thickness of Thai fetuses: at 32 to 35 weeks' gestation. J Med Assoc Thai 2006; 89: 748-54.
7. Tongsong T, Tatiyapornkul T. Cardiothoracic ratio in the first half of pregnancy. J Clin Ultrasound 2004; 32: 186-9.
8. Sharland GK, Allan LD. Screening for congenital heart disease prenatally. Results of a 2 1/2-year study in the South East Thames Region. Br J Obstet Gynaecol 1992; 99: 220-5.
9. Paladini D, Chita SK, Allan LD. Prenatal measurement of cardiothoracic ratio in evaluation of heart disease. Arch Dis Child 1990; 65: 20-3.
10. Sharland GK, Allan LD. Normal fetal cardiac measurements derived by cross-sectional echocardiography. Ultrasound Obstet Gynecol 1992; 2: 175-81.

ค่าปกติของขนาดหัวใจทารกในครรภ์ระหว่างอายุครรภ์ 16-39 สัปดาห์

อธิตา จันทเสนา นนท์, จรินทร์ทิพย์ สมประสิทธิ์, เด่นศักดิ์ พงศ์โรจน์เผ่า

วัตถุประสงค์: เพื่อศึกษาค่าปกติของขนาดหัวใจทารกในครรภ์ระหว่างอายุครรภ์ 16-39 สัปดาห์

วัสดุและวิธีการ: ทำการวัดเส้นรอบวงของหัวใจและทรวงอกของทารกในครรภ์ ตลอดจนวัดความหนาของผนังหัวใจห้องล่างซ้ายในขณะหัวใจคลายตัว ขนาดของห้องล่างซ้ายในขณะหัวใจบีบตัวและคลายตัว ความหนาของผนังกันระหว่างหัวใจห้องล่างในขณะหัวใจคลายตัว ในทารกจำนวน 480 คน

ผลการศึกษา: ค่าปกติของขนาดของหัวใจของทารกในครรภ์มีความสัมพันธ์กับอายุครรภ์อย่างมีนัยสำคัญทางสถิติ ในขณะที่ขนาดของหัวใจเมื่อเปรียบเทียบกับขนาดของทรวงอก และ shortening fraction ของหัวใจห้องล่างซ้าย ไม่สัมพันธ์กับอายุครรภ์

สรุป: ได้มีการแสดงค่าขนาดของหัวใจของทารกในครรภ์ตามอายุครรภ์ ซึ่งข้อมูลจากการศึกษาครั้งนี้สามารถนำมาใช้เป็นค่ามาตรฐานในการประเมินหัวใจทารกในครรภ์ที่มีความเสี่ยง