

# Dimensional Guide to Harvesting the Radius for Orofacial Reconstruction

Wandee Apinhasmit DDS, PhD\*, Supin Chompoonpong MS, PhD\*\*,  
Dolly Methathrathip DDS\*, Nutchaya Amornmettakit BEd\*\*

\* Department of Anatomy, Faculty of Dentistry, Chulalongkorn University, Bangkok

\*\* Department of Anatomy, Faculty of Medicine Siriraj Hospital, Mahidol University, Bangkok

---

**Objective:** To provide an accurate harvesting guide to maintain the maximum possible safe dimensions of the radius for orofacial reconstruction using the osteocutaneous radial forearm free flap.

**Material and Method:** Two hundred radii of 100 adult formalin-embalmed cadavers (52 males, 48 females) were measured.

**Results:** The mean minimum circumference of the radius measured between the pronator teres and brachioradialis insertions was  $41.0 \pm 4.3$  mm. At this point, the mean medio-lateral diameter was  $13.4 \pm 1.6$  mm. The mean of the maximum harvested length of the radius between the pronator teres and brachioradialis insertions was  $81.3 \pm 10.4$  mm. On the average, the maximum harvested length of the radius was 34.9% of its total length. The minimum medio-lateral diameter of the radius was consistently 1-5 mm less than 40% of its minimum circumference. There was no significant dimensional difference between sides but gender difference existed in all measurements ( $p < 0.001$ ), except the maximum harvested length of the radius.

**Conclusion:** The present study may be helpful to guide reconstructive surgeons for safer harvesting of the radius using the osteocutaneous radial forearm free flap to repair orofacial defects.

**Keywords:** Radius, Osteocutaneous radial forearm free flap, Dimension, Orofacial reconstruction

*J Med Assoc Thai* 2008; 91 (12): 1879-84

Full text. e-Journal: <http://www.medassocthai.org/journal>

---

The osteocutaneous radial forearm free flap (ORFFF) is considered as a useful source of vascularized skin, fascia, and bone for the reconstruction of orofacial defects following ablative surgery<sup>(1-15)</sup>. The ORFFF provides a reliable long pedicle, good pliable skin amenable to sensate reconstruction, and easy repair for donor site defect<sup>(2,16)</sup>. Reliance on the radial artery, this flap may be transferred as a composite flap containing a segment of the underlying radius for restoring the function and appearance in the orofacial region. Owing to the muscle attachments, only a limited segment of the radius between the insertions of pronator teres (PT) and brachioradialis (BR) muscles can be harvested with the flap<sup>(5)</sup> (Fig. 1). A bone length

of 10 to 16 cm<sup>(7)</sup> or up to 16 cm<sup>(9)</sup> can be taken and approximately either 40% of the total circumference of the radius or 40% of the diameter may be safely removed<sup>(7,9)</sup> (Fig. 1).

It is difficult to measure the dimensions of the radius during the operation because most of the bone is covered with muscles and their periosteum, which preserves its blood supply<sup>(15)</sup>. A deficient or superfluous amount of radius harvesting is possible. An excessive amount of the harvested bone can increase the risk of postoperative fracture which is the greatest complication at the residual donor site and varies from 17 to 43%<sup>(1,12,17-19)</sup>. Fractures of the radius have been virtually eliminated by minimal bone removal with keel-shaped osteotomies and prophylactic plating<sup>(6,10,11,13,20)</sup>.

Adequate knowledge of the dimensions of the radius is important for the surgeon to prevent

---

Correspondence to: Apinhasmit W, Department of Anatomy, Faculty of Dentistry, Chulalongkorn University, Bangkok 10330, Thailand. Phone: 0-2218-8875, Fax: 0-2218-8870, E-mail: Wandee.A@chula.ac.th

possible complications to the donor but a relative paucity of studies has been reported on a dimensional guide to harvesting the radius for the orofacial reconstruction using the ORFFF<sup>(21)</sup>. No such study has ever been reported in Thais. Possible gender differences in these parameters were taken into consideration and compared with the findings in the former literature. Therefore, the present study aimed to provide an accurate guide to harvesting the maximum possible safe dimension of the radius for the reconstruction of craniofacial defect and intraoral implants using the ORFFF.

### Material and Method

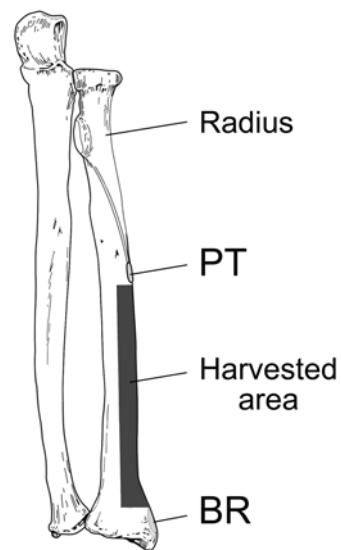
Two hundred radii from both sides of 100 adult formalin-embalmed Thai cadavers were investigated in the present study. These subjects had been partially dissected in the gross anatomy laboratories by medical students at the Department of Anatomy of the Faculty of Medicine Siriraj Hospital and the Faculty of Science at Mahidol University, and dental students at the Department of Anatomy of the Faculty of Dentistry at Chulalongkorn University.

Upon dissection of the forearm, the radial head, the styloid process, and the insertions of both muscles were identified (Fig. 2).

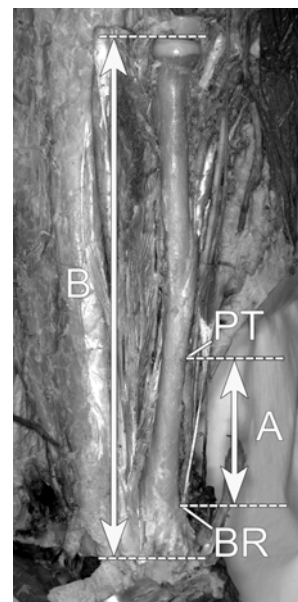
The minimum circumference of each radius between the insertions of PT and BR was measured. At the point of minimum circumference, the medio-lateral and the antero-posterior diameters of the radius were measured. The maximum theoretical length of harvested bone was also measured as the distance between the insertions of PT and BR (Fig. 2). The total length of the radius was measured from the highest point of the radial head to the lowest point of the styloid process (Fig. 2).

All measurements were made using sliding calipers (Mitutoyo®, Japan) capable of measuring to the nearest 0.01 mm, except for the minimum circumference and total length of the radius, which were measured by using a measuring tape.

Overall, the complete data of measurements were tabulated and separated according to side and gender. The Statistical Package for Social Science (version 11.5) was used for the analyses. The mean, standard deviation (SD) and range for each of the measurements were assessed. The maximum length of harvested bone of the radius was compared with its total length as percentage. Comparisons of the values of all measurements were made between the sides of each subject and genders using paired and unpaired



**Fig. 1** Diagram showed the possible harvested area of the radius. The length of the harvested radius is the distance between the insertions of pronator teres (PT) and brachioradialis (BR) muscles. The width of harvested area is limited to 40% of the minimum circumference of the radius between the insertions of the PT and BR muscles or 40% its medio-lateral width in the same area



**Fig. 2** The dissection of the radius. Distance A is the length of the harvested radius between the insertions of pronator teres (PT) and brachioradialis (BR) muscles, while distance B is the total length of the radius

*t*-tests, respectively. The differences between groups were considered significantly at  $p < 0.05$ .

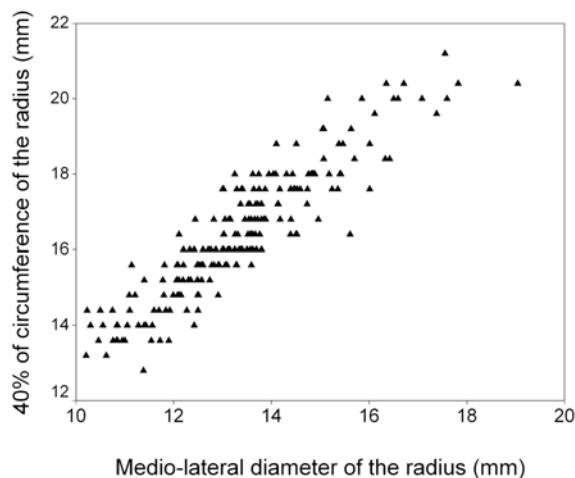
## Results

Fifty-two subjects were males and 48 females. The mean age of the subjects was  $70.5 \pm 12.4$  years and ranged between 39 and 96 years with no significant age difference between the genders ( $p = 0.255$ ).

The dimensions of radii relevant to the bone harvest for orofacial reconstruction and intraoral implants using ORFFF are shown in Table 1. The mean value of the minimum circumference of the radius between the PT and BR insertions was  $41.0 \pm 4.3$  mm. At the point of minimum circumference, the mean medio-lateral diameter was  $13.4 \pm 1.6$  mm. The mean value of the maximum length of the harvested bone measured as the distance between the insertions of PT and BR was  $81.3 \pm 10.4$  mm. The maximum harvested bone length of the radius as compared with its total length was 34.9% (Table 1).

A dimensional comparison between the sides indicated no significant difference but gender difference existed in all measurements ( $p < 0.001$ ), except for the distance between the insertions of PT and BR ( $p = 0.150$ ) (Table 1).

Fig. 3 demonstrates the close relation between the minimum medio-lateral diameter measured between the insertions of PT and BR muscles and 40% of the circumference at this point of each radius ( $r = 0.915$ ). The minimum medio-lateral diameter of the radius was consistently 1-5 mm less than 40% of its minimum circumference.



**Fig. 3** The close relation between the minimum medio-lateral diameter and 40% of the circumference at that point of each radius

## Discussion

Since the ORFFF was first described in China by Yang et al., in 1978, it has become widely accepted as a reliable flap in many areas of reconstructive surgery for restoring the orofacial defects and intraoral implants<sup>(1-15)</sup>. However, early clinical studies have reported high rates of donor site complications<sup>(4,8,12)</sup>. The main criticisms are associated with the postoperative fracture risk of the residual radius and inadequate harvested bone<sup>(4,8,12)</sup>.

The dimensional study might be a guide to harvesting the maximum possible safe width and

**Table 1.** Measurements of 200 radii from 100 subjects and their comparison between genders

Measurements of radii (mm)	Total (n = 200)		Males (n = 104)		Females (n = 96)	
	Mean $\pm$ SD	Range	Mean $\pm$ SD	Range	Mean $\pm$ SD	Range
Minimum circumference	$41.0 \pm 4.3$	32.0-53.0	$43.8 \pm 3.6$	34.0-53.0	$38.0 \pm 2.8^*$	32.0-45.0
Medio-lateral diameter	$13.4 \pm 1.6$	10.2-19.0	$14.3 \pm 1.4$	10.8-19.0	$12.3 \pm 1.1^*$	10.2-15.6
Antero-posterior diameter	$11.1 \pm 1.2$	8.9-14.3	$11.9 \pm 0.9$	9.8-14.3	$10.3 \pm 0.7^*$	8.9-12.6
Distance between PT and BR insertions (A)	$81.3 \pm 10.4$	60.0-109.1	$82.3 \pm 9.6$	65.3-109.1	$80.2 \pm 11.0$	60.0-108.9
Total length (B)	$233.0 \pm 16.7$	186.0-280.0	$243.2 \pm 13.0$	216.0-280.0	$220.0 \pm 12.7^*$	186.0-249.0
40% of circumference	$16.4 \pm 1.7$	12.8-21.2	$17.5 \pm 1.5$	13.6-21.2	$15.2 \pm 1.1^*$	12.8-18.0
Difference between 40% of circumference and medio-lateral diameter	$3.1 \pm 0.7$	0.8-4.9	$3.2 \pm 0.7$	1.4-4.9	$2.9 \pm 0.6^*$	0.8-4.5
A/B (%)	$34.9 \pm 3.9$	24.9-45.2	$33.9 \pm 3.7$	24.9-45.1	$36.1 \pm 3.8^*$	2.4-45.2

PT, pronator teres muscle; BR brachioradialis muscle

Statistical evaluation with the unpaired *t*-test: \*  $p < 0.001$  between males and females

length of the radius for orofacial reconstruction using the ORFFF. The present study is unique in that the material was harvested from known races and genders. It was therefore possible to investigate sexual dimorphism.

The diameter of the radius varies depending on the plane in which it is measured. The mean theoretical length of the harvested bone measured between the insertions of PT and BR in the present study was  $81.3 \pm 10.4$  mm (range, 60.0-109.1 mm). The harvested radius length was shorter than those in the previous reports<sup>(7,9,21)</sup>. Collyer and Goodger<sup>(21)</sup> studied 100 dried cadaveric radii and indicated that the mean distance between the PT and BR insertions was 110 mm (range, 90-130 mm). Urken<sup>(7)</sup> stated that a total of 10 to 12 cm and up to 40% of the circumference of the radius could be harvested. Even after stripping the part of the insertion of PT and distracting osteotomy sites of the graft, it would be unusual to obtain the 160 mm span that has been recorded by Vaughan<sup>(9)</sup>. The difference in the radius length is partially due to the race. However, it is sufficient to use the radius with 90-130 mm for the orofacial reconstruction of defects from cancer and trauma as previously reported by Kim et al<sup>(2)</sup> that the mean length of the harvested radius in 52 patients was 63 mm with a range of 25 to 110 mm.

The length of the harvested bone varies in the wide dimensional range among the individuals. Total length can be assessed by using preoperative radiograph, therefore the relative ratio between the maximum harvested bone length and total length of the radius should be a more reliable parameter for clinical use. The ratio was 34.9% in Thais.

The present result shows that the minimum diameter of the radius from the medial to the lateral border corresponds closely to 40% of the circumference of the radius. This particular clinical interest is consistent with the previous study of 100 dried cadaveric radii<sup>(21)</sup>. The minimum medio-lateral diameter of the radius was consistently 1-5 mm less than 40% of its minimum circumference. Therefore, it is suggested to use the minimum medio-lateral diameter of the radius to estimate its harvested width.

The mean of the total length of radius reported in the present study ( $233.0 \pm 16.7$  mm) was nearly equal to the previous study in another racial population (231 mm)<sup>(21)</sup>. Significant difference between genders was also found in the present study as was the case in the previous study<sup>(22)</sup>.

The results from the present study show gender differences in the minimum circumference of

the radius, medio-lateral diameter, antero-posterior diameter and total length. They were significantly longer in males than in females ( $p < 0.001$ ) but the distance between the insertions of PT and BR was not different ( $p = 0.150$ ). Gender variation should be taken into consideration when the measurements related to the ORFFF are performed.

In conclusion, the maximum possible safe length of the harvested radius was 34.9% of its total length. The minimum medio-lateral diameter of the radius corresponds closely to 40% of its circumference. The present study may be helpful in guiding reconstructive surgeons in the safer harvesting of the radius for the reconstruction of orofacial defect and intraoral implants using the ORFFF.

#### Acknowledgements

This research project was supported by a grant from the Dental Research Fund, Faculty of Dentistry, Chulalongkorn University, Bangkok 10330, Thailand. Special thanks are expressed to the Department of Anatomy, Faculty of Medicine Siriraj Hospital, Mahidol University; the Department of Anatomy, Faculty of Science, Mahidol University and to the Department of Anatomy, Faculty of Dentistry, Chulalongkorn University for the provision of samples; Dr Chanchai Hosanguan for his statistical advice and Miss Nuanlaor Nimlaor for her help in drawing the picture.

#### References

1. Corrigan AM, O'Neill TJ. The use of the compound radial forearm flap in oro-mandibular reconstruction. *Br J Oral Maxillofac Surg* 1986; 24: 86-95.
2. Kim JH, Rosenthal EL, Ellis T, Wax MK. Radial forearm osteocutaneous free flap in maxillofacial and oromandibular reconstructions. *Laryngoscope* 2005; 115: 1697-701.
3. Martin IC, Cawood JI, Vaughan ED, Barnard N. Endosseous implants in the irradiated composite radial forearm free flap. *Int J Oral Maxillofac Surg* 1992; 21: 266-70.
4. Soutar DS, McGregor IA. The radial forearm flap in intraoral reconstruction: the experience of 60 consecutive cases. *Plast Reconstr Surg* 1986; 78: 1-8.
5. Soutar DS, Scheker LR, Tanner NS, McGregor IA. The radial forearm flap: a versatile method for intraoral reconstruction. *Br J Plast Surg* 1983; 36: 1-8.
6. Thoma A, Khadaroo R, Grigenas O, Archibald S, Jackson S, Young JE, et al. Oromandibular reconstruction with the radial-forearm osteocutaneous

- flap: experience with 60 consecutive cases. *Plast Reconstr Surg* 1999; 104: 368-78.
7. Urken ML. Composite free flaps in oromandibular reconstruction. Review of the literature. *Arch Otolaryngol Head Neck Surg* 1991; 117: 724-32.
  8. Vaughan ED. The radial forearm free flap in orofacial reconstruction. Personal experience in 120 consecutive cases. *J Craniomaxillofac Surg* 1990; 18: 2-7.
  9. Vaughan ED. The radial forearm flap in orofacial reconstruction. *Int J Oral Maxillofac Surg* 1994; 23: 194-204.
  10. Villaret DB, Futran NA. The indications and outcomes in the use of osteocutaneous radial forearm free flap. *Head Neck* 2003; 25: 475-81.
  11. Werle AH, Tsue TT, Toby EB, Girod DA. Osteocutaneous radial forearm free flap: its use without significant donor site morbidity. *Otolaryngol Head Neck Surg* 2000; 123: 711-7.
  12. Bardsley AF, Soutar DS, Elliot D, Batchelor AG. Reducing morbidity in the radial forearm flap donor site. *Plast Reconstr Surg* 1990; 86: 287-92.
  13. Weinzweig N, Jones NF, Shestak KC, Moon HK, Davies BW. Oromandibular reconstruction using a keel-shaped modification of the radial forearm osteocutaneous flap. *Ann Plast Surg* 1994; 33: 359-69.
  14. Cordeiro PG, Santamaria E. A classification system and algorithm for reconstruction of maxillectomy and midfacial defects. *Plast Reconstr Surg* 2000; 105: 2331-46.
  15. Boyd JB, Mulholland RS, Davidson J, Gullane PJ, Rotstein LE, Brown DH, et al. The free flap and plate in oromandibular reconstruction: long-term review and indications. *Plast Reconstr Surg* 1995; 95: 1018-28.
  16. Yang GF, Chen PJ, Gao YZ, Liu XY, Li J, Jiang SX, et al. Forearm free skin flap transplantation: a report of 56 cases. 1981. *Br J Plast Surg* 1997; 50: 162-5.
  17. Boorman JG, Brown JA, Sykes PJ. Morbidity in the forearm flap donor arm. *Br J Plast Surg* 1987; 40: 207-12.
  18. Richardson D, Fisher SE, Vaughan ED, Brown JS. Radial forearm flap donor-site complications and morbidity: a prospective study. *Plast Reconstr Surg* 1997; 99: 109-15.
  19. Timmons MJ, Missotten FE, Poole MD, Davies DM. Complications of radial forearm flap donor sites. *Br J Plast Surg* 1986; 39: 176-8.
  20. Edmonds JL, Bowers KW, Toby EB, Jayaraman G, Girod DA. Torsional strength of the radius after osteofasciocutaneous free flap harvest with and without primary bone plating. *Otolaryngol Head Neck Surg* 2000; 123: 400-8.
  21. Collyer J, Goodger NM. The composite radial forearm free flap: an anatomical guide to harvesting the radius. *Br J Oral Maxillofac Surg* 2005; 43: 205-9.
  22. Suwanlikhid N, Mahakkanukrauh P. Northern Thai radius and sexing. *Bull Chiang Mai Assoc Med Sci* 2004; 37: 97-105.

---

## คำแนะนำทางมิติของการเก็บกระดูกปลายแขนท่อนนอกสำหรับการบูรณะช่องปากและไบหน้า

วันดี อภินทรมิต, สุพิน ชมภูพงษ์, ดอลลี เมธาธราธิป, ณิชยา อมรเมตตาจิต

**วัตถุประสงค์:** เพื่อหาคำแนะนำที่แม่นยำในการเก็บกระดูกปลายแขนท่อนนอกให้ได้ความกว้างและความยาวของกระดูกมากที่สุด และปลอดภัยต่อกระดูกปลายแขนท่อนนอกส่วนที่เหลือ สำหรับการบูรณะช่องปากและไบหน้า โดยใช้แผ่นเนื้อเยื่อปะปลูกชนิดออสซีโอคิวทาเนียสเรเดียลฟอราร์ม

**วัสดุและวิธีการ:** วัดกระดูกปลายแขนท่อนนอกจำนวน 200 อัน จากศพดองฟอรมาลินผู้ใหญ่ 100 ศพ เป็นเพศชาย 52 คน และเพศหญิง 48 คน

**ผลการศึกษา:** ความยาวรอบกระดูกปลายแขนท่อนนอกที่น้อยที่สุด ซึ่งอยู่ระหว่างที่เกาะปลายของกล้ามเนื้อไพเรเนเทอเทเรส กับ เบรคิโอเรเดียลีส มีค่าเฉลี่ยเท่ากับ  $41.0 \pm 4.3$  มม. ณ จุดนี้ เส้นผ่าศูนย์กลางในระนาบกลาง-ข้าง มีค่าเฉลี่ยเท่ากับ  $13.4 \pm 1.6$  มม. ความยาวมากที่สุดของกระดูกที่สามารถเก็บมาใช้ได้ ซึ่งวัดจากระยะระหว่างที่เกาะปลายของกล้ามเนื้อไพเรเนเทอเทเรสกับเบรคิโอเรเดียลีส มีค่าเฉลี่ยเท่ากับ  $81.3 \pm 10.4$  มม. ความยาวมากที่สุดของกระดูกปลายแขนท่อนนอกที่สามารถเก็บมาใช้ได้มีค่าเฉลี่ยเป็นร้อยละ 34.9 ของความยาวกระดูกท่อนนี้ นอกจากนี้ยังพบว่าเส้นผ่าศูนย์กลางในระนาบกลาง-ข้างของกระดูกปลายแขนท่อนนอกมีค่าน้อยกว่าร้อยละ 40 ของความยาวโดยรอบกระดูกปลายแขนท่อนนอกระหว่าง 1-5 มม. เมื่อทำการเปรียบเทียบระหว่างด้านจะไม่พบความแตกต่างกันของค่าที่วัดได้ แต่พบความแตกต่างระหว่างเพศในทุกค่าที่ทำการวัด ( $p < 0.001$ ) ยกเว้นระยะระหว่างที่เกาะปลายของกล้ามเนื้อไพเรเนเทอเทเรสกับเบรคิโอเรเดียลีส

**สรุป:** การศึกษานี้ให้ข้อแนะนำทางมิติที่เป็นประโยชน์ต่อศัลยแพทย์ในการเก็บกระดูกปลายแขนท่อนนอกอย่างปลอดภัย เพื่อใช้แผ่นเนื้อเยื่อปะปลูกชนิดออสซีโอคิวทาเนียสเรเดียลฟอราร์ม สำหรับการบูรณะช่องปากและไบหน้า

---