

# The Surgical Outcome of Primary Trabeculectomy with Mitomycin C and A Fornix-Based Conjunctival Flap Technique in Thailand<sup>†</sup>

Li-Anne Lim MD\*,  
Panida Chindasub MD\*\*, Naris Kitnarong MD\*\*

<sup>†</sup>This article was presented in the Royal College of Ophthalmology of Thailand annual meeting in November 2006

\* University of New South Wales, Australia

\*\* Department of Ophthalmology, Faculty of Medicine Siriraj Hospital, Mahidol University, Bangkok, Thailand

---

**Objective:** To determine the surgical outcome of primary trabeculectomy with mitomycin C (MMC) and fornix-based conjunctival flap technique in Thai patients.

**Material and Method:** This retrospective review was conducted from the clinical records of all Thai glaucoma patients who underwent a primary trabeculectomy with MMC using a fornix-based conjunctival flap technique by or under supervision of one ophthalmologist (NK) between February 2004 and July 2006 at Siriraj Hospital, School of Medicine, Mahidol University, Bangkok, Thailand.

**Results:** There were 69 eyes from 60 patients. Postoperatively, mean intraocular pressure (IOP) was significantly decreased from  $26.1 \pm 11.7$  mmHg to  $11.7 \pm 4.4$  mmHg ( $p < 0.001$ ) and mean number of anti-glaucoma medication was significantly reduced from  $3.9 \pm 0.7$  to  $0.3 \pm 0.9$  ( $p < 0.001$ ) at last visit. Sixty-seven eyes (96.8%) were considered as success. Eight eyes (11.6%) in this group needed topical anti-glaucoma medications. Two eyes (2.9%) were considered as failure. Mean follow-up period was  $7.7 \pm 4.0$  months. Complications included bleb leaking in 16 eyes, choroidal detachment in four eyes, and blebitis in two eyes. Seven eyes with leaking bleb resolved spontaneously.

**Conclusion:** Primary trabeculectomy with MMC using a fornix-based conjunctival flap technique is effective as a treatment for Thai glaucoma patients. There is a high rate of success (96.8%) with the low rate of complication.

**Keywords:** Glaucoma, Trabeculectomy, Antimetabolites

*J Med Assoc Thai* 2008; 91 (10): 1551-7

**Full text. e-Journal:** <http://www.medassocthai.org/journal>

---

Trabeculectomy is a well recognized treatment option for the surgical management of raised intraocular pressure (IOP)<sup>(1)</sup> When compared with medical therapy, it has been found to produce consistently lower IOPs<sup>(2)</sup>. Several modalities have been established to improve the success rate of trabeculectomy. The recent use of adjunctive antimetabolites such as mitomycin C (MMC) has shown improved postoperative success rates<sup>(3)</sup> and is now the most widely accepted procedure<sup>(4)</sup>. The potent anti-fibrotic agent acts by modifying the

healing process of the Tenon's capsule and conjunctiva, decreasing fibrosis and inflammation and thus improving post operative IOP control and increasing the longevity of the surgical procedure<sup>(5-7)</sup>. The orientation of the trabeculectomy conjunctival flap, either limbus-based or fornix-based, has long been the subject of much controversy. Reviews of previous comparative studies have shown no statistically significant difference in outcomes<sup>(8,9)</sup>, although an increased incidence of early bleb leaks, which were usually self resolving, were reported for fornix-based conjunctival flap trabeculectomy<sup>(8)</sup>. The majority of studies reported the outcome of fornix-based conjunctival flap (FBCF) trabeculectomy in Caucasian subjects. The present

---

Correspondence to: Kitnarong N, Department of Ophthalmology, Siriraj Hospital, Mahidol University, 2 Prannok, Bangkok Noi, Bangkok 10700, Thailand. Phone: 0-2419-8033, Fax: 0-2411-1906. E-mail: [tenkn@mahidol.ac.th](mailto:tenkn@mahidol.ac.th)

report presents outcome data of a series of fornix-based conjunctival flap trabeculectomy operations performed on Thai glaucoma patients.

### **Material and Method**

This is a retrospective study review of all Thai glaucoma patients who underwent FBCF trabeculectomy with MMC between February 2004 and July 2006, at Siriraj Hospital. All surgeries were performed by one ophthalmologist (NK). Patients with a history of a previous trabeculectomy or who had a postoperative follow up period of less than 12 months were excluded. The Ethic Committee of school of Medicine Siriraj Hospital, Mahidol University approved the present study in accordance with the principles articulated in the Declaration of Helsinki.

The diagnosis of glaucoma was made on the basis of clinical evidence of typical glaucomatous optic disc cupping associated with raised IOP, defined as that greater than 21 mmHg without antiglaucoma treatment, and/or visual field damage. Using gonioscopy, an angle grade 0-1, greater than 180 degrees by the modified Shaffer grading system, was diagnosed as angle-closure. Open angle was defined as an angle of grade 3-4 of at least 180 degrees. Indications for trabeculectomy surgery were considered on the basis of insufficient IOP control with either: (1) maximally tolerated glaucoma medications, (2) progression of disease with either visual field loss or optic disc cupping, or (3) poor medication compliance. The primary indication for surgery was uncontrolled IOP with maximal tolerable medical therapy.

### **Surgical technique**

All surgery was performed by one surgeon (NK). After retrobulbar anesthesia, the eye was prepared with sterile drapes. A wire lid speculum was inserted and a corneal traction suture placed adjacent to the inferior limbus for ocular stability. A fornix-based conjunctival flap was created by limbal periotomy at the superonasal or superotemporal quadrant for 3-4 clock hours. Disinsertation of the conjunctiva and Tenon's capsule was achieved by blunt posterior dissection using Westcott scissors. Oblique relaxing incisions at one or both sides allowed for conjunctival flap retraction superiorly away from the surgical limbus, as well as adequate scleral exposure. Hemostasis of the sclera was controlled using a diathermy.

A partial thickness 3.5 x 3.5 mm (base x height) triangular or rectangular scleral flap was then created using a surgical blade No.15, dissecting anteriorly

towards the clear cornea by lamellar dissection. Mitomycin C (0.4mg/ml) was applied by a thin cellulose sponge to the scleral flap below the conjunctiva and Tenon's capsule for 45 seconds to 4 minutes. The surgical area was then vigorously irrigated with balance salt solution (BSS). The duration of MMC application was based upon the preoperative evaluation of each patient's risk factors for surgical failure including patient age and the preoperative quality of the subconjunctiva and tenon's capsule. In general, younger patients and thicker Tenon's capsule received a longer application.

Paracentesis was performed through the temporal clear cornea with a 20-gauge needle. The anterior chamber was then entered via sclerotomy, using a 15-degree blade for sharp dissection. The sclerotomy was widened with a Kelly Descemet punch. Peripheral iridectomy was performed to decrease the risk of sclerostomy occlusion and papillary block. The scleral flap was sutured with 10-0 nylon sutures anchored at its corners. The tension and number of sutures was individualized for each case to allow for adequate flow of aqueous humour and adjustments were made in the case of leakage or flattening of the anterior chamber. The fornix-based flap was closed securely with round needle 10-0 nylon sutures anchored at the limbus and closed relaxing incisions with a continuing suture. The bleb and wound closure were checked post-operatively with 2% fluorescein dye.

### **Postoperative procedure**

In the early post-operative period, topical antibiotics and 1% prednisolone were applied six times a day for seven days. A combination of antibiotics and dexamethasone were then administered four times a day for the following one month or until the signs of inflammation disappeared. All patients were followed up post-operatively at 1-day, 7-days, 1-month and then every two months thereafter.

The post-operative follow-up schedule involved a full eye examination, visual acuity, IOP and for the development of any post-operative complications such as bleb leak, blebitis, hyphema, endophthalmitis and hypotony. The presence of bleb leak was tested using the Seidel test routinely at almost every visit. In the presence of any post-operative complications, suitable interventions were administered at the appropriate time.

For each patient the following data were collected: age of patient at time of surgery, gender, eye laterality, concurrent ocular diseases prior to or at the

time of surgery, previous eye surgery, pre and post-operative visual acuity, IOP, and the number of medications, intraoperative and postoperative complications, and postoperative interventions such as laser suture lysis, 5-fluorouracil (5-FU) injection, bleb needling, or any other surgery performed after trabeculectomy.

### Statistical methods

Two definitions of successful IOP control were applied: definition 1: the IOP is consistently lower than 21mmHg without any glaucoma medication, definition 2: the IOP is consistently lower than 21 mmHg with topical antiglaucoma medication. Surgical failure was also determined using two definitions; definition 1; an IOP of greater than 21 mmHg with maximal dose of topical antiglaucoma medication or definition 2: an IOP of less than 21mmHg but controlled using systemic antiglaucoma medication. As minor procedures such as bleb needling, laser suture lysis and 5-FU injection were carried out at the doctor's discretion when indicated, they were not taken into account in determining failure apart from the given definitions of failure. Hypotony was defined as an IOP of less than 5mmHg for three or more consecutive months postoperatively. Descriptive statistics were used to summarize the results. Comparison between mean IOP at preoperative and postoperative during the follow up period was presented. Paired t test were used to compare between pre and last visit with significantly at  $p < 0.05$ .

### Results

There were 69 eyes from 60 patients with the mean age of 54.2 year-olds included in the present study. The demographic characteristics are summarized in Table 1. The most common diagnosis was primary open angle glaucoma (POAG). The majority of eyes had no previous ocular operation. The mean duration of the disease before trabeculectomy was  $18.8 \pm 24.5$  months. Intraoperative MMC was applied with the average time of 1.8 minutes. Serial mean IOP during the follow-up period is demonstrated in Fig. 1. Mean IOP was significantly decreased from  $26.1 \pm 11.7$  mmHg to  $11.7 \pm 4.4$  mmHg ( $p < 0.001$ ) at the last visit. At the last follow up period, 67 eyes (97.1%) were considered as success. In this group, 59 eyes (85.5%) achieved control of IOP under 21 mmHg without any antiglaucoma medication (definition 1). The remaining eight eyes (11.6%) needed topical antiglaucoma medications to control IOP under 21 mmHg (definition 2). Two eyes required oral acetazolamide (failure), subsequently underwent second trabeculectomy. The mean number

of medications was reduced significantly from  $3.9 \pm 0.7$  to  $0.3 \pm 0.9$  ( $p < 0.001$ ). Intraoperative complication was observed in two eyes, including hyphema and scleral flap tear. Forty-five eyes (65.2%) experienced no complication. Postoperative complications are summarized in Table 2. The most common complication was bleb leaking, of which seven eyes resolved spontaneously with conservative treatment. Postoperative interventions required in 31 eyes (44.9%) included

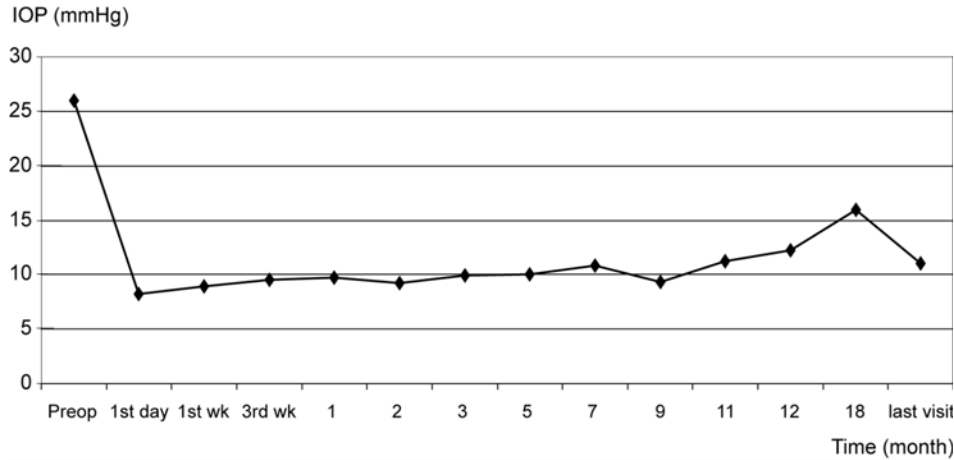
**Table 1.** The demographic characteristics

Number of eyes/patients	69/60
Age (mean $\pm$ SD) (years)	54.2 $\pm$ 21.9
Range	9-83
Gender	
Male	34 (57%)
Female	26 (43%)
Eye laterality	
Right	36 (52%)
Left	33 (48%)
Diagnosis	
POAG	31
PACG	21
NVG	5
Steroid induced glaucoma	4
Post ocular trauma	4
Others	4
Previous operations	
None	57
Vitrectomy	2
Phacoemulsification with IOL	7
ECCE with IOL	2
Cryoretinopexy	1

IOL = intraocular lens, ECCE = extracapsular cataract extraction, POAG = primary open angle glaucoma, PACG = primary angle-closure glaucoma, NVG = neovascular glaucoma

**Table 2.** Postoperative complications after trabeculectomy with mitomycin C using fornix-based conjunctival flap technique in Thai glaucoma patients

Complication	Eyes
Bleb leak	16
Choroidal detachment	4
Blebitis	2
Hyphema	2
Corneal decompensation	1
Ocular hypotony	1
Shallow anterior chamber	1



**Fig. 1** Sequential change of mean IOP preoperatively and postoperatively during the follow-up period after trabeculectomy with mitomycin C using fornix-based conjunctival flap technique

5-FU injection in 19 eyes (27.5%), laser suture lysis in 18 eyes (26.1%), bleb resuturing in nine eyes (13.0%), and bleb needling in two eyes (2.9%). Fifty-five eyes (80%) had visual acuity better than 6/60 compared to 53 eyes (77%) preoperatively. Mean follow-up time was  $7.7 \pm 4.0$  months (range 3-18 months).

### Discussion

Filtration surgery has been reported to have a lower success rate in Asian than the success rate reported on Caucasian populations in the Western literature<sup>(10-12)</sup>. However, the survival of trabeculectomy improved with the use of intraoperative antimetabolite, which was advocated in the Asian population<sup>(10,13)</sup>. The refinement of surgical technique such as the orientation of conjunctival flap, the conjunctival closure, and the scleral flap size has been reported to affect the success rate and complications<sup>(8,14-16)</sup>. This is a report of a moderately sized retrospective and non-randomized series of FBCF trabeculectomy procedures with adjunctive intraoperative MMC. All surgeries were performed by or under the supervision of a single surgeon (NK), so the technique was consistent. Most patients in the present series benefited from the FBCF trabeculectomy, with sixty-seven eyes (97.1%) successfully treated according to both definitions of success. Of these, only eight eyes (11.6%) in this group, were in the category of definition 2, requiring topical anti-glaucoma medications. Mean IOP and the mean number of anti-glaucoma medications was significantly decreased from preoperative compared to the last visit. Only two eyes (2.9%) were considered as failures.

These findings are comparable with a previous study carried out by Ng et al of similar design and scale (Table 3)<sup>(15)</sup>. Apart from racial differences, patient demographics were similar. Overall success was slightly higher in the current study and the frequency of post-operative complications was lower. However, the report by Ng used Wise's conjunctival closure technique with a longer follow-up period ( $21.8 \pm 4.5$  months).

Previous studies of both isolated trabeculectomy and combined cataract and glaucoma surgery comparing limbal-based and fornix-based procedures have shown no significant differences with regard to IOP or post-operative visual acuity<sup>(9,7-22)</sup>. There was some variability in the comparison of post-operative complications between the two groups, such as surgical techniques, length of follow-up and criteria for success. Murchinson and Shields reported better early post-operative IOP control in the limbal-based group, while the fornix-based group showed slightly increased IOP's

**Table 3.** Comparison of the current study with Ng et al, a report of fornix-based trabeculectomy in Chinese patients

	Ng et al (2000)	Present study
Number of eyes	48	69
Overall success	75.0%	97.1%
Conjunctival wound leak	20.8%	23.2%
Choroidal detachment	6.3%	5.8%
Shallow anterior chamber	10.4%	1.4%
HypHEMA	8.3%	2.9%

on post-operative days 1 and 2<sup>(18)</sup>. They recommended this as one reason they preferred the limbal-based conjunctival flap technique<sup>(18)</sup>. Similarly, Lemon and co-workers reported early post-operative IOP control at 1-week to be lower in the limbal-based group; however, it was not statistically significant<sup>(17)</sup>.

Post-operative wound leaks were also reported in previous studies with mixed results. Mandic et al and Tezel et al found an increased incidence of bleb leakage in the fornix based group<sup>(20,23)</sup>, while Shingleton et al and Traverso et al reported no statistical difference regarding bleb leaks between the two groups<sup>(9,22)</sup>. Lemon and co-workers reported more leaks in the limbal-based group and suggested that the lower incidence of hypotony with wound leaks in the fornix-based group may be related to the technical differences between the two procedures; a FBCF allowing for tighter contact between the conjunctival and scleral flaps<sup>(17)</sup>. A review by Kohl and Walton of several comparative studies showed an early wound leak rate between 11-30% for FBCF trabeculectomies and 0-11% for LBCF trabeculectomies<sup>(8)</sup>. Wells et al found that limbal-based (LBCF) procedures were more likely to develop serious bleb related complications at an earlier stage than in fornix-based procedures<sup>(16)</sup>. They reported increased incidences of cystic bleb formation (90% LBCF group, 29% FBCF group,  $p < 0.01$ ), late hypotony and bleb related ocular infection (both more common and occurring earlier in the LBCF group  $p < 0.05$ ).

In the present series, the overall rate of post-operative complication was low occurring in 24 eyes (34.8%). The most common early complication was bleb leak seen in 16 eyes (23.2%). These were treated with suitable interventions carried out at the appropriate time including the use of contact lenses (1 eye, 1.4%), conjunctival resuturing (10 eyes, 14.5%) and autologous blood injection (1 eye, 1.4%). Seven eyes had spontaneous bleb leak resolution. This is comparable with the results of Ng et al who also reported a 20.8% incidence of wound leak, most of which resolved spontaneously<sup>(14)</sup>. Furthermore, multivariate analysis suggests that early bleb leaks are not an independent risk factor for trabeculectomy failure<sup>(8)</sup>.

Kohl and Walton also reported a similar rate of shallow anterior chamber and hypotony as well as late post-operative complications between the LBCF and FBCF groups<sup>(8)</sup>. We encountered one case (1.4%) of corneal decompensation and ocular hypotony and one case (1.4%) of shallow anterior chamber.

There are many favorable aspects of the fornix-based trabeculectomy over the limbal-based

approach. Intra-operatively, fornix-based procedures are faster to perform, (44 minutes as compared with 55 minutes for LBCF trabeculectomy) technically less challenging and requires less manipulation and trauma to the conjunctiva decreasing the risk of "button-holing" and reducing bleeding<sup>(8,19)</sup>. With shorter conjunctival incisions, it also gives better exposure and visualization of the operative field<sup>(19,24)</sup>. As a result, it is easier to apply anti-metabolite over a larger area than with a LBCF, which may encourage the development of a diffuse bleb<sup>(8,16)</sup>. Fukuchi et al also suggested that a limbal-based incision as used in a FBCF trabeculectomy does not give the bleb an upper border, thus promoting the formation of a stronger bleb and possibly attempting to prevent or reduce the incidence of post-operative bleb related complications<sup>(25)</sup>.

As a retrospective noncomparative study with a short follow-up period, the authors were unable to study on late complications and long-term success rates. Prospective, randomized, comparative, and long-term follow up should be conducted to gather further information.

## Conclusion

In conclusion, primary trabeculectomy with MMC using a fornix-based conjunctival flap technique is an effective treatment for Thai glaucoma patients. It shows a high rate of success and a low incidence of post-operative complications. Although there is an increased incidence of early bleb leaks, all cases resolved spontaneously or with an appropriated intervention. A fornix based approach offers many intraoperative advantages and with the use of antimetabolites such as MMC may promote the formation of a stronger, flatter more posterior diffuse bleb that is less likely to have late complications.

## References

1. Nouri-Mahdavi K, Brigatti L, Weitzman M, Caprioli J. Outcomes of trabeculectomy for primary open-angle glaucoma. *Ophthalmology* 1995; 102: 1760-9.
2. Fontana H, Nouri-Mahdavi K, Lumba J, Ralli M, Caprioli J. Trabeculectomy with mitomycin C: outcomes and risk factors for failure in phakic open-angle glaucoma. *Ophthalmology* 2006; 113: 930-6.
3. Maquet JA, Dios E, Aragon J, Bailez C, Ussa F, Laguna N. Protocol for mitomycin C use in glaucoma surgery. *Acta Ophthalmol Scand* 2005; 83: 196-200.

4. Chen PP, Yamamoto T, Sawada A, Parrish RK, Kitazawa Y. Use of antifibrosis agents and glaucoma drainage devices in the American and Japanese Glaucoma Societies. *J Glaucoma* 1997; 6: 192-6.
5. Kitazawa Y, Kawase K, Matsushita H, Minobe M. Trabeculectomy with mitomycin. A comparative study with fluorouracil. *Arch Ophthalmol* 1991; 109: 1693-8.
6. Cheung JC, Wright MM, Murali S, Pederson JE. Intermediate-term outcome of variable dose mitomycin C filtering surgery. *Ophthalmology* 1997; 104: 143-9.
7. Bindlish R, Condon GP, Schlosser JD, D'Antonio J, Lauer KB, Lehrer R. Efficacy and safety of mitomycin-C in primary trabeculectomy: five-year follow-up. *Ophthalmology* 2002; 109: 1336-41.
8. Kohl DA, Walton DS. Limbus-based versus fornix-based conjunctival flaps in trabeculectomy: 2005 update. *Int Ophthalmol Clin* 2005; 45: 107-13.
9. Shingleton BJ, Chaudhry IM, O'Donoghue MW, Baylus SL, King RJ, Chaudhry MB. Phacotrabeculectomy: limbus-based versus fornix-based conjunctival flaps in fellow eyes. *Ophthalmology* 1999; 106: 1152-5.
10. Hooi ST, Hooi SH. Trabeculectomy outcomes in a Malaysian general hospital. *Med J Malaysia* 2003; 58: 565-78.
11. Ehrnrooth P, Lehto I, Puska P, Laatikainen L. Long-term outcome of trabeculectomy in terms of intraocular pressure. *Acta Ophthalmol Scand* 2002; 80: 267-71.
12. Tan C, Chew PT, Lum WL, Chee C. Trabeculectomy - success rates in a Singapore hospital. *Singapore Med J* 1996; 37: 505-7.
13. Wong JS, Yip L, Tan C, Chew P. Trabeculectomy survival with and without intra-operative 5-fluorouracil application in an Asian population. *Aust NZ J Ophthalmol* 1998; 26: 283-8.
14. Ng PW, Yeung BY, Yick DW, Yu CB, Lam DS. Fornix-based trabeculectomy with Wise's suture technique in Chinese patients. *Ophthalmology* 2000; 107: 2310-3.
15. Ng PW, Yeung BY, Yick DW, Tsang CW, Lam DS. Fornix-based trabeculectomy using the 'anchoring' corneal suture technique. *Clin Experiment Ophthalmol* 2003; 31: 133-7.
16. Wells AP, Cordeiro MF, Bunce C, Khaw PT. Cystic bleb formation and related complications in limbus-versus fornix-based conjunctival flaps in pediatric and young adult trabeculectomy with mitomycin C. *Ophthalmology* 2003; 110: 2192-7.
17. Lemon LC, Shin DH, Kim C, Bendel RE, Hughes BA, Juzych MS. Limbus-based vs fornix-based conjunctival flap in combined glaucoma and cataract surgery with adjunctive mitomycin C. *Am J Ophthalmol* 1998; 125: 340-5.
18. Murchison JF Jr, Shields MB. Limbal-based vs fornix-based conjunctival flaps in combined extracapsular cataract surgery and glaucoma filtering procedure. *Am J Ophthalmol* 1990; 109: 709-15.
19. Alwitry A, Patel V, King AW. Fornix vs limbal-based trabeculectomy with mitomycin C. *Eye* 2005; 19: 631-6.
20. Mandic Z, Bencic G, Zoric GM, Bojic L. Fornix vs limbus based flap in phacotrabeculectomy with mitomycin C: prospective study. *Croat Med J* 2004; 45: 275-8.
21. Berestka JS, Brown SV. Limbus- versus fornix-based conjunctival flaps in combined phacoemulsification and mitomycin C trabeculectomy surgery. *Ophthalmology* 1997; 104: 187-96.
22. Traverso CE, Tomey KF, Antonios S. Limbal- vs fornix-based conjunctival trabeculectomy flaps. *Am J Ophthalmol* 1987; 104: 28-32.
23. Tezel G, Kolker AE, Kass MA, Wax MB. Comparative results of combined procedures for glaucoma and cataract: II. Limbus-based versus fornix-based conjunctival flaps. *Ophthalmic Surg Lasers* 1997; 28: 551-7.
24. Wise JB. Mitomycin-compatible suture technique for fornix-based conjunctival flaps in glaucoma filtration surgery. *Arch Ophthalmol* 1993; 111: 992-7.
25. Fukuchi T, Ueda J, Yaoeda K, Suda K, Seki M, Abe H. Comparison of fornix- and limbus-based conjunctival flaps in mitomycin C trabeculectomy with laser suture lysis in Japanese glaucoma patients. *Jpn J Ophthalmol* 2006; 50: 338-44.

---

## ผลการผ่าตัด primary trabeculectomy with mitomycin C โดยวิธี fornix-based conjunctival flap ในประเทศไทย

Li-Anne Lim, พนิดา จินดาทรัพย์, นริศ กิจณรงค์

**วัตถุประสงค์:** เพื่อศึกษาผลการผ่าตัดรักษาต้อหินแบบ trabeculectomy with mitomycin C (MMC) ด้วยวิธี fornix-based conjunctival flap ในผู้ป่วยคนไทย

**วัสดุและวิธีการ:** การศึกษานี้เป็นการศึกษาแบบย้อนหลังโดยเก็บรวบรวมข้อมูลจากทะเบียนประวัติของผู้ป่วยต้อหินทุกคนที่ได้รับการผ่าตัด trabeculectomy with MMC ด้วยวิธี fornix-based conjunctival flap โดย หรือ ภายใต้อการควบคุมการผ่าตัดของจักษุแพทย์ท่านเดียว (ผศ.นพ.นริศ กิจณรงค์) ระหว่างเดือนกุมภาพันธ์ พ.ศ.2547 ถึงเดือนกรกฎาคม พ.ศ.2549 ที่ภาควิชาจักษุวิทยา คณะแพทยศาสตร์ศิริราชพยาบาล มหาวิทยาลัยมหิดล กรุงเทพมหานคร ประเทศไทย

**ผลการศึกษา:** มีผู้ป่วย 60 คนคิดเป็น 69 ตา พบว่าค่าเฉลี่ยความดันตาลดลงอย่างมีนัยสำคัญทางสถิติจาก  $26.1 \pm 11.7$  มิลลิเมตรปรอทก่อนผ่าตัดเป็น  $11.7 \pm 4.4$  มิลลิเมตรปรอทหลังผ่าตัด ( $p < 0.001$ ) จำนวนยาที่ใช้หลังผ่าตัดก็ลดลงอย่างมีนัยสำคัญทางสถิติคือ จากก่อนผ่าตัด  $3.9 \pm 0.7$  ชนิดเป็น  $0.3 \pm 0.9$  ชนิด ( $p < 0.001$ ) ตาที่ได้รับการพิจารณาว่าประสบความสำเร็จในการผ่าตัดวิธีนี้มี 67 ตา (คิดเป็นร้อยละ 96.8) โดยในจำนวนนี้มี 8 ตา (ร้อยละ 11.6) ที่ต้องการใช้ยารักษาต้อหินหลังผ่าตัด มีผู้ป่วยเพียง 2 ราย (2 ตา) ที่ถือว่าการผ่าตัดไม่ประสบความสำเร็จ ระยะเวลาในการติดตามการรักษาเฉลี่ย  $7.7 \pm 4.0$  เดือน ภาวะแทรกซ้อนประกอบด้วย bleb leaking 16 ตา choroidal detachment 4 ตาและ blebitis 2 ตา ผู้ป่วยที่มีภาวะ bleb leaking สามารถหายได้เอง 7 ตา

**สรุป:** การผ่าตัดรักษาต้อหินแบบ trabeculectomy with mitomycin C (MMC) ด้วยวิธี fornix-based conjunctival flap เป็นวิธีที่มีประสิทธิภาพสำหรับรักษาผู้ป่วยโรคต้อหินคนไทย พบว่ามีอัตราความสำเร็จสูง (ร้อยละ 96.8) และพบภาวะแทรกซ้อนที่รุนแรงจากการผ่าตัดน้อย

---