

The Anatomy of the Lateral Circumflex Femoral Artery in Anterolateral Thigh Flap

Tanvaa Tansatit MD*,
Samang Wanidchaphloi MSc**, Pasinee Sanguansit MSc**

* Department of Anatomy, Faculty of Medicine, King Chulalongkorn Memorial Hospital,
Chulalongkorn University, Bangkok

** Department of Biological Science, Faculty of Science and Technology,
Huachiew Chalermprakiet University, Samutprakarn

Objective: To determine systematically the pattern of the cutaneous perforator of the lateral circumflex femoral artery (LCFA) in anterolateral thigh perforator (ALT) flap.

Material and Method: Sixty dissections of the LCFA were carried out in 30 preserved cadavers. The number, type, origin, and location of the cutaneous perforators of the LCFA were studied and measured.

Results: There were 169 perforators. In 79.3%, the perforators originated from the descending branch, 18.3% from the transverse branch. The perforator of the medial descending and the ascending branch were found in 1.8% and 0.6%, respectively. The most cutaneous perforators were concentrated in the middle third (14 to 28 cm from the ASIS) of the anterolateral thigh region.

Conclusion: The perforator of the descending branch, which was located ranging from 21 to 35 cm, was appropriate for flap designing to avoid the perforator of the transverse branch, which was difficult to harvest.

Keywords: Lateral circumflex femoral artery, Anterolateral thigh flap

J Med Assoc Thai 2008; 91 (9): 1404-9

Full text. e-Journal: <http://www.medassocthai.org/journal>

The concept of the septocutaneous artery flaps, as one variety of the fasciocutaneous flap, has recently become established^(1,2). Septocutaneous flaps have been widely used for the reconstruction of various defects^(1,3-5). Among these flaps was the anterolateral thigh perforator (ALT) flap, which was first reported by Song et al⁽¹⁾. The lateral circumflex femoral artery was an ideal axial vessel on which to base the ALT flap⁽⁶⁾. The purpose of the present study was to define the neurovascular anatomy of the lateral circumflex femoral artery related to this flap.

Material and Method

Thirty adult embalmed cadavers were dissected. The skin incisions were made medially

starting at the level of the anterior superior iliac spine (ASIS) in the lower abdomen down to the medial border of the patella. The incision was extended laterally from both ends. The cutaneous flaps were raised from the muscles to investigate the perforating vessels of the lateral circumflex femoral artery. The following anatomical features were identified and measured: (1) The numbers and types of the perforator greater than 0.5 mm in diameter, (2) The diameters at its origin and locations from the ASIS of the perforators.

Results

The lateral circumflex femoral artery (LCFA) originated from the deep femoral artery in 56.67% or from the femoral artery in 43.33%. The LCFA divided into three main branches: the ascending branch (AB), the transverse branch (TB), and the descending branch (DB) (Fig.1, Table 1). The DB was accompanied by two veins and laterally (90%) by the nerve to vastus lateralis muscle. There were two types of the LCFA

Correspondence to: Tansatit T, Department of Anatomy, Faculty of Medicine, King Chulalongkorn Memorial Hospital, Chulalongkorn University, Bangkok 10330, Thailand. Phone: 0-2256-4281, 0-2252-7028, Fax: 0-2256-4281, 0-2252-7028, E-mail: tansatit@yahoo.com

Table 1. Mean distance, length and diameter of each branch

	n	Distance (cm)	Length (cm)***	Diameter (mm)****
LCFA	60	5.1 ± 1.7 (1.0-9.0)*	15.4 ± 3.1 (10.6-26.0)	4.9 ± 1.1 (2.4-8.0)
DB	54	3.2 ± 1.6 (0.5-7.5)**	12.0 ± 3.4 (6.7-23.8)	3.4 ± 0.8 (2.0-6.0)
TB	27	-	6.6 ± 1.2 (4.2-9.0)	2.9 ± 0.5 (2.0-4.0)
MDB	3	-	6.8 ± 0.5 (6.5-7.4)	3.0 ± 0.6 (2.6-3.7)
AB	1	-	5.5	2.4
Total	60	-	-	-

Data were presented as mean ± SD (range)

Abbreviation: LCFA, the lateral circumflex femoral artery; DB, the descending branch; TB, the transverse branch; MDB, the medial descending branch; AB, the ascending branch; *, distance from the inguinal ligament to the origin of the LCFA; **, distance from the origin to disappear into the muscle; ***, length from the origin to disappear into the muscle; ****, diameter at its origin

(Fig. 2). The AB derived from the TB (56.7%) or the AB derives from the LCFA (43.3%).

In 60 flaps, 169 perforators were presented (2.8 perforators per flap). The average diameter of the perforators was 1.1 ± 0.4 mm. One hundred and thirty-four perforators of the DB were observed (2.3 perforators per flap). None of the other branches of the LCFA gave rise to constant perforators. The musculocutaneous perforators that penetrated the vastus lateralis muscle was the most common type (76.9%).

The cutaneous perforators of the ALT flap derived from branches of the LCFA (Table 2). In the majority of dissections (79.3%), the perforators arose from the DB and were the musculocutaneous perforators (65.1%) (Fig. 3).

In Table 2, the perforator of the DB was 23.9 ± 4.95 cm from the ASIS. The perforator of the TB was 16.6 ± 3.4 cm distal to the ASIS. The average distance of all perforators measured from the ASIS to exit the fascia, was 22.4 ± 5.5 cm. In 76.9% of the dissections, the perforators were concentrated in the middle third of the thigh (Fig. 4). The DB gave 106 perforators (78.5%). In the majority of dissections (75.4%), the perforators mostly concentrated between 21 and 35 cm from the ASIS. The diameter was 0.9 ± 0.3 mm in diameter (Fig. 5). The large perforators were located nearer the ASIS than the small perforators (Table 3).

The average distance of the first perforator of each flap measured from the ASIS, was 16.6 ± 3.4 cm and 1.3 ± 0.3 in the diameter. Details of the first perforator are reported in Table 4. In 90% of the dissections, the DB gave sizable cutaneous perforators. The DB gave at least two perforators in 85.2%. The first perforator of the DB located 21.0 ± 4.0 cm. The second

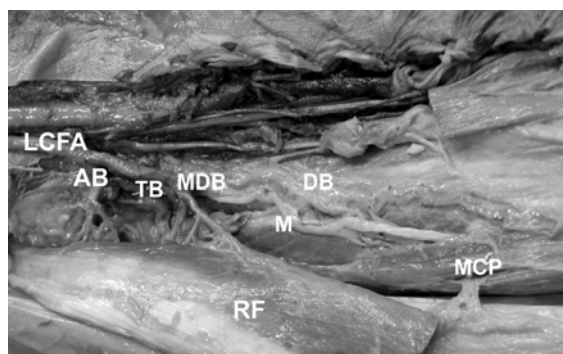


Fig. 1 The lateral circumflex femoral artery (LCFA) gave three main branches: the ascending branch (AB), the transverse branch (TB) and the descending branch (DB); the medial descending branch (MDB); the rectus femoris muscle (RF); the motor branch (M); the musculocutaneous perforator (MCP)

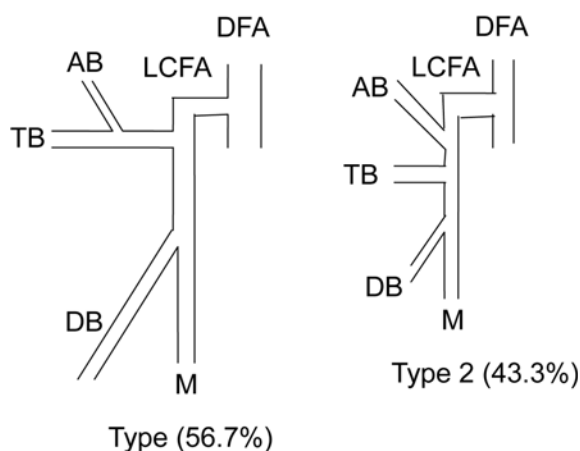


Fig. 2 The patterns of the LCFA

Table 2. The number, type, distance and diameter of the perforator for each branch of the LCFA

Branch	n = 60 (%)	Number of perforator (%)	Type		Distance (cm)*	Diameter (mm)**
			MCP (%)	SCP (%)		
DB	54 (90)	134 (79.3)	110 (82.1)	24 (17.9)	23.9 ± 4.95 (11.8-35.0)	1.0 ± 0.3 (0.5-2.3)
TB	27 (45)	31 (18.3)	20 (64.5)	11 (35.5)	16.6 ± 3.40 (8.2-23.3)	1.3 ± 0.3 (0.8-2.2)
MDB	3 (5)	3 (1.8)	-	3 (100)	15.9 ± 2.60 (13.3-18.5)	1.6 ± 0.2 (1.4-1.8)
AB	1 (1.7)	1 (0.6)	-	1 (100)	15.5	1.2
Total		169 (100)	130 (76.9)	39 (23.1)	-	-

Data were presented as mean ± SD (range) for distance and diameter

Abbreviation: DB, the descending branch; TB, the transverse branch; MDB, the medial descending branch; AB, the ascending branch; MCP, the musculocutaneous perforators; SCP, the septocutaneous perforators; *, distance from the ASIS; **, diameter at its origin

Table 3. The number and the distance of the diameter for each group

Diameter (mm)	Number (%)	Distance (cm)*
0.5-0.8	48 (28.4)	25.7 ± 5.7 (11.5-35.0)
0.9-1.2	68 (40.2)	23.1 ± 4.5 (13.0-32.7)
1.3-1.6	39 (23.1)	18.7 ± 4.2 (8.2-28.1)
1.7-2.0	12 (7.1)	18.3 ± 3.9 (13.2-26.2)
2.1-2.4	2 (1.2)	17.5 ± 2.1 (16.0-19.0)
Total	169 (100)	-

Abbreviation: *, the distance from the superior border of ASIS to exit the deep fascia: mean ± SD (range)

Table 4. The origins and types of the first perforator of each flap

Branch	n (%)	Type	
		MCP (%)	SCP (%)
DB	29 (48.3)	19 (31.7)	10 (16.7)
TB	27 (45.0)	18 (30.0)	9 (15.0)
MDB	3 (5.0)	-	3 (5.0)
AB	1 (1.6)	-	1 (1.6)
Total	60 (100)	-	-

Abbreviation: DB, the descending branch; TB, the transverse branch; MDB, the medial descending branch; AB, the ascending branch; MCP, the musculocutaneous perforators; SCP, the septocutaneous perforators

perforator of the DB located 4.2 ± 1.99 cm below the first perforator.

The lateral femoral cutaneous nerve (Fig. 6) pierced the deep fascia at 13.5 to 23.0 cm from the ASIS

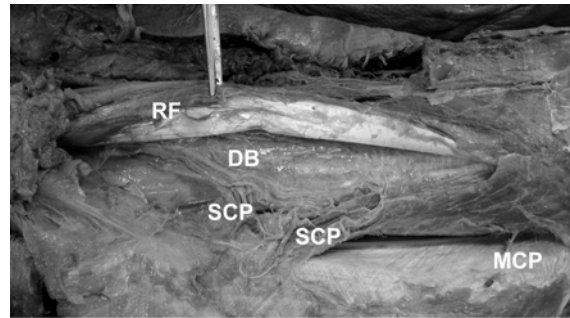


Fig. 3 The descending branch (DB) gave the septocutaneous perforators (SCP) and musculocutaneous perforators (MCP); the rectus femoris muscle (RF)

and entered the flap at its superior border in the deep subcutaneous layer. The diameter of the nerve was 2.1 ± 0.7 mm at the lateral border of the ASIS.

Discussion

In recent years, the ALTP flap has become the major flap in reconstructive surgery⁽⁷⁾, and its usefulness and versatility have been well documented⁽⁸⁾. It has almost replaced many other flaps⁽⁷⁾. The ALT flap has several advantages: 1) relative consistency of the anatomy; 2) ease of dissection; 3) long pedicle length; 4) ability to thin the flap; 5) good texture; 6) providing a sensate flap; 7) a two-team approach; 8) no sacrifice of a major artery; 9) lack of functional morbidity at the donor site; and 10) ability to close the donor site primarily⁽⁷⁾. The disadvantages are: 1) the board fascia has to be taken within the flap; and 2) the flap is thick. The anatomy of this flap has been reported, yet, analysis of the vascular anatomy has not been described⁽⁸⁾.

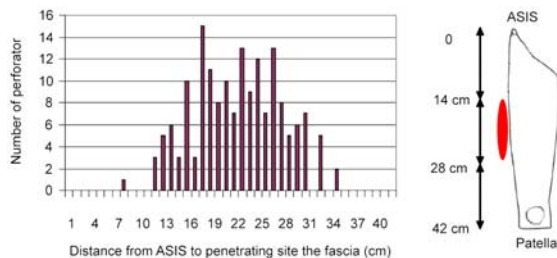


Fig. 4 Most perforators were concentrated in the middle third of the thigh

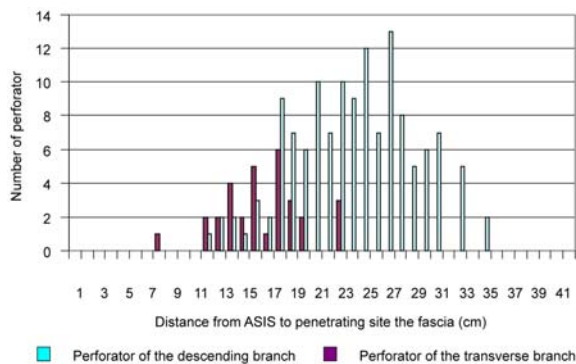


Fig. 5 The location of the perforator of the descending branch compared the perforator of the transverse branch




Fig. 6 The lateral femoral cutaneous nerve (LCFN) easy found beside the lateral border of the ASIS (Probe)

The number of the perforator of the descending branch

Some authors described that the number of the perforators mostly arose from the DB of the LCFA but a few studies were reported.

Kimata et al⁽⁹⁾ reported 2.31 perforators arose from the DB. In contrast to this, Kawai et al⁽⁸⁾ found 3.8 perforators originated from the DB. The present study, observed 2.2 perforators with the average diameter of

1.1mm. Therefore, this region had adequate perforators for flap harvesting.

The type of the perforator of the descending branch

In the present study, the most perforators were the musculocutaneous perforators (79.3%) and were similar to several authors, Xu et al⁽⁶⁾, 59.8%, Zhou et al⁽¹⁰⁾, 63%, Kimata et al⁽⁹⁾, 81.9%, Yu et al⁽¹¹⁾, 71%, and Chen et al⁽⁷⁾, 88%. Then, the musculocutaneous perforator was suitable for harvesting of the flap because it is easily found and great in number. While, the septocutaneous perforators were becoming popular because it dissection was easy, but limited in number.

The origin of the perforator

In the present study, the most perforators originated from the DB in 79.3%. These findings were similar to several authors. The DB was suitable for flap harvesting because it was the largest and longest branch of the LCFA and it was lined in a loose plane between the rectus femoris and the vastus inter-mediate muscles.

The location of the perforator

The present study reported that most of perforators were located in the middle third of the thigh region (The ASIS to the center of the lateral part of the patella). In addition, the first perforators were concentrated in the middle third of the thigh near the proximal third of the thigh.

The present study findings were similar to several authors, Xu et al⁽⁶⁾, Zhou et al⁽¹⁰⁾, Kimata et al⁽⁹⁾, Kuo et al⁽¹²⁾, Kawai et al⁽⁸⁾ and Chen et al⁽⁷⁾. It was found that the perforators were located in the middle third of the thigh region. However, Koshima et al⁽¹⁾ found that the perforators were located in the proximal one-third of the lateral aspect of the thigh.

The TB, which was difficult for dissection, gave to the perforators, which concentrated from 12 to 20 cm from the ASIS. The DB gave the perforators located in this range in 24.6% of the dissections. Then, to avoid the perforator of the TB, dissection of the perforator should be confined within the range starting from 21 to 35 cm from the ASIS.

In 2002, Celik et al⁽¹³⁾ reported the use of the ALT flaps in 660 patients with the success rate was 96.58%. The present study, the DB gave at least two perforators in 85.2%. The second perforator of the DB located 4.2 ± 1.99 (1.0-9.5 cm) below the first perforator of the DB. It is reasonable to include two perforators in this flap.

The motor branch of the femoral nerve

In 2001, Kuo et al⁽¹²⁾ reported, the motor branch of the femoral nerve running medial to the DB. In the present study, the motor branches ran laterally (90%) and they were easily noticed during flap harvesting.

The lateral femoral cutaneous nerve

Chuan et al⁽⁶⁾ described the nerve pierced the deep fascia 7 to 10 cm below the ASIS. Ribuffo et al⁽¹⁴⁾ reported at 18 to 20 cm. Sensation recovered well when sensate flaps were used. In the present study, the nerve pierced the deep fascia at 13.5 to 23.0 cm from the ASIS. Sensate flap should be harvested because this nerve was easy to find at the lateral border of the flaps.

Conclusion

The authors suggested that the perforator of the DB, which was located ranging from 21 to 35 cm from the ASIS, was appropriate for flap designing.

References

1. Koshima I, Fukuda H, Utunomiya R, Soeda S. The anterolateral thigh flap; variations in its vascular pedicle. *Br J Plast Surg* 1989; 42: 260-2.
2. Cormack GC, Lamberty BG. A classification of fascio-cutaneous flaps according to their patterns of vascularisation. *Br J Plast Surg* 1984; 37: 80-7.
3. Song R, Gao Y, Song Y, Yu Y, Song Y. The forearm flap. *Clin Plast Surg* 1982; 9: 21-6.
4. Baek SM. Two new cutaneous free flaps: the medial and lateral thigh flaps. *Plast Reconstr Surg* 1983; 71: 354-65.
5. Song YG, Chen GZ, Song YL. The free thigh flap: a new free flap concept based on the septocutaneous artery. *Br J Plast Surg* 1984; 37: 149-59.
6. Xu DC, Zhong SZ, Kong JM, Wang GY, Liu MZ, Luo LS, et al. Applied anatomy of the anterolateral femoral flap. *Plast Reconstr Surg* 1988; 82: 305-10.
7. Chen HC, Tang YB, Mardini S, Tsai BW. Reconstruction of the hand and upper limb with free flaps based on musculocutaneous perforators. *Microsurgery* 2004; 24: 270-80.
8. Kawai K, Imanishi N, Nakajima H, Aiso S, Kakibuchi M, Hosokawa K. Vascular anatomy of the anterolateral thigh flap. *Plast Reconstr Surg* 2004; 114: 1108-17.
9. Kimata Y, Uchiyama K, Ebihara S, Nakatsuka T, Harii K. Anatomic variations and technical problems of the anterolateral thigh flap: a report of 74 cases. *Plast Reconstr Surg* 1998; 102: 1517-23.
10. Zhou G, Qiao Q, Chen GY, Ling YC, Swift R. Clinical experience and surgical anatomy of 32 free anterolateral thigh flap transplantations. *Br J Plast Surg* 1991; 44: 91-6.
11. Yu P, Sanger JR, Matloub HS, Gosain A, Larson D. Anterolateral thigh fasciocutaneous island flaps in perineoscrotal reconstruction. *Plast Reconstr Surg* 2002; 109: 610-6.
12. Kuo YR, Jeng SF, Kuo MH, Huang MN, Liu YT, Chiang YC, et al. Free anterolateral thigh flap for extremity reconstruction: clinical experience and functional assessment of donor site. *Plast Reconstr Surg* 2001; 107: 1766-71.
13. Celik N, Wei FC, Lin CH, Cheng MH, Chen HC, Jeng SF, et al. Technique and strategy in anterolateral thigh perforator flap surgery, based on an analysis of 15 complete and partial failures in 439 cases. *Plast Reconstr Surg* 2002; 109: 2211-6.
14. Ribuffo D, Cigna E, Gargano F, Spalvieri C, Scuderi N. The innervated anterolateral thigh flap: anatomical study and clinical implications. *Plast Reconstr Surg* 2005; 115: 464-70.

กายวิภาคของหลอดเลือดแดงแลทเทอร์อัล เซอร์คัมเฟล็ก เฟโมรอล ใน แอนเทอโรแลทเทอร์อัล ไฮ แฟล็บ

ธันวา ตันสถิตย, สำอาง วณิชชาพลอย, ภาสินี สงวนสิทธิ์

วัตถุประสงค์: เพื่อศึกษาถึงรูปแบบของหลอดเลือดเพอพอเรเทอร์ ของหลอดเลือดแดงแลทเทอร์อัล เซอร์คัมเฟล็ก เฟโมรอล ในแอนเทอโรแลทเทอร์อัล ไฮ แฟล็บ

วัสดุและวิธีการ: ทำการศึกษาในศพดองที่รักษาสภาพด้วยฟอร์มาลินจำนวน 30 ท่อน (60 แฟล็บ) โดยศึกษาจำนวน ชนิด จุดกำเนิด และวัดตำแหน่งของเพอพอเรเทอร์ของหลอดเลือดแดงแลทเทอร์อัล เซอร์คัมเฟล็ก เฟโมรอล

ผลการศึกษา: ใน 60 แฟล็บ พบหลอดเลือดเพอพอเรเทอร์ทั้งหมด 169 หลอดเลือด โดยเป็นเพอพอเรเทอร์ที่เกิดจากแขนงดิสเซนดิง 79.3 เปอร์เซ็นต์ แขนงทรานซเวิสต์ 18.3 เปอร์เซ็นต์ แขนงมีเดียล ดิสเซนดิง 1.8 เปอร์เซ็นต์และแขนงแอ็ชเซนดิง 0.6 เปอร์เซ็นต์ เพอพอเรเทอร์ส่วนใหญ่อยู่หนาแน่นบริเวณกึ่งกลางของต้นขาทางด้านหน้าและด้านข้าง ประมาณ 14 ถึง 28 ซม. จากแอนทีเรีย ซูพีเรีย อิลีแอค สปาย (ASIS)

สรุป: เพอพอเรเทอร์ที่เกิดจากแขนงดิสเซนดิง พบหนาแน่นที่ระยะ 21 ถึง 35 ซม. สามารถนำไปใช้ในการออกแบบแฟล็บ และควรหลีกเลี่ยงเพอพอเรเทอร์ของแขนงทรานซเวิสต์
