

# Case Report

## Type A Aortic Dissection Presenting as Acute Ischemic Stroke Caution for Thrombolytic Therapy: A Case Report and Literatures Review

Tawai Ngernsritrakul MD\*,  
Pornchai Sathirapanya MD\*

\* Department of Internal Medicine, Faculty of Medicine, Prince of Songkla University, Hat Yai, Songkhla

---

*The authors reported a patient who had type A aortic dissection presenting with sudden onset of right hemiplegia and depressed consciousness. CT scan of brain showed acute cerebral infarction of left corona radiata, posterior limb of left internal capsule combined with left hemispheric brain swelling. An old cerebral infarction at the posterior limb of right internal capsule was also noted. Clinical signs of aortic regurgitation and difference in blood pressures and amplitude of pulses on both arms were associated. Initial chest x-ray revealed widening of the mediastinum. CT scan of chest revealed dissecting aorta extending from the ascending aorta to the mid of the descending aorta. Surgical correction of the aorta was refused and the patient was treated medically with partial neurological deficit. No additional cardiovascular events occurred.*

**Keywords:** Aortic dissection, Ischemic stroke, Thrombolytic therapy

*J Med Assoc Thai* 2008; 91 (8): 1302-7

**Full text. e-Journal:** <http://www.medassocthai.org/journal>

---

Cerebral infarction due to acute aortic dissection is a rare clinical experience. However, this emergency condition needs accurate diagnosis and prompt management since it has high fatality. Concern for this hidden life threatening cardiovascular disease in patients presenting with acute ischemic stroke is warranted to avoid the unexpected catastrophic outcome from thrombolytic therapy.

### Case Report

A 49-year-old fisherman, with a history of sudden onset of right hemiplegia and depressed consciousness while fishing in the sea, was taken to the emergency department of our center two days later. On the initial evaluation his blood pressure were 90/60 mmHg on the right arm and 120/50 mmHg on the left arm.

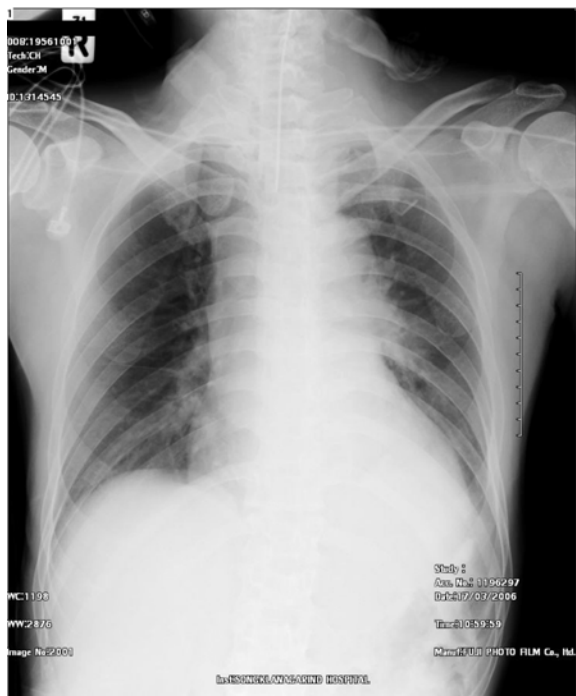Pulse rate was regular with 74 beats/min but decreased in amplitude on his right arm. Collapsing pulse was detected in all extremities. On the cardiac

examination, there was no apical shifting, no ventricular heaving, and no thrill. Normal rhythm of the first and second heart sounds was audible. The diastolic blowing murmur of grade II was heard in the left upper parasternal border. On the neurological examination, he was drowsy and did not respond to commands properly. The pupils were 3 mm in diameter and normally reacted to the light bilaterally. Both eyes were deviated to the left side on primary eyes position, but correctable by tilting the head in the horizontal plane. Right hemiplegia was found. Hyporeflexia and absence of ankle clonus but presence of Babinski's signs were evidenced on the affected side. There was no meningeal irritation signs elicited. Normal carotid pulsation and no carotid bruit were detected.

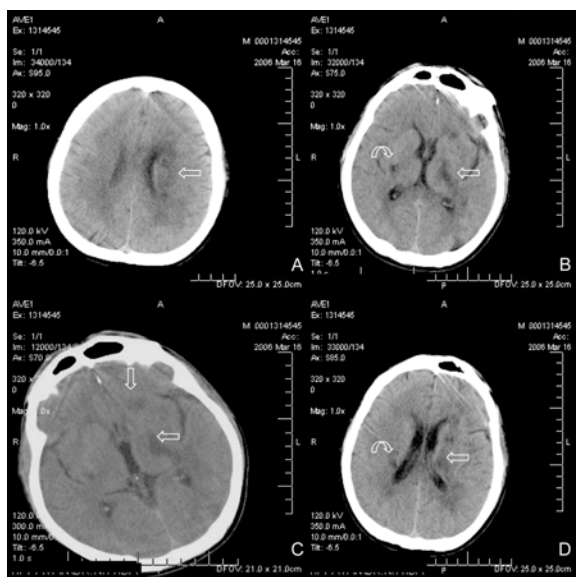
Laboratory studies revealed normal routine blood tests including anti- HIV, serology for syphilis and coagulogram. An electrocardiogram demonstrated normal sinus rhythm with ST segments elevation in II, III and aVF were evidenced. No PR interval depression was detected. The initial chest x-ray revealed widening of mediastinum without abnormal lung infiltration (Fig. 1).

---

*Correspondence to: Sathirapanya P, Department of Internal Medicine, Faculty of Medicine, Prince of Songkla University, Hat Yai, Songkhla 90110, Thailand. Phone: 074-451-452, Fax: 074-429-385. E-mail: sporncha@medicine.psu.ac.th*



**Fig. 1** Chest x-ray showed widening mediastinum



**Fig. 2** CT scan of the brain revealed acute cerebral infarction at the left corona radiate (A and D), internal capsule (B and C) (horizontal arrow) and frontal lobe (C) (vertical arrow) and old cerebral infarction at posterior limb of right internal capsule (B and D) (curved arrow)

An emergency CT scan of the brain revealed a hypodensity lesion at the left corona radiata, left thalamus, left temporal, and left frontal area with prominent brain swelling on the left hemisphere indicating acute cerebral infarction along the left middle cerebral artery territory. An old cerebral infarction at the posterior limb of right internal capsule was also detected (Fig. 2). Immediately, an emergency CT scan of the chest was requested after aortic dissection was suspected and it revealed an intimal flap extending from the ascending aorta, the aortic arch to the descending aorta, and ended at the thoraco-abdominal junction. However, the suprarenal abdominal aorta was intact. The dissection extended upwards to involve the innominate artery, left common carotid artery, and left subclavian artery (Fig. 3).

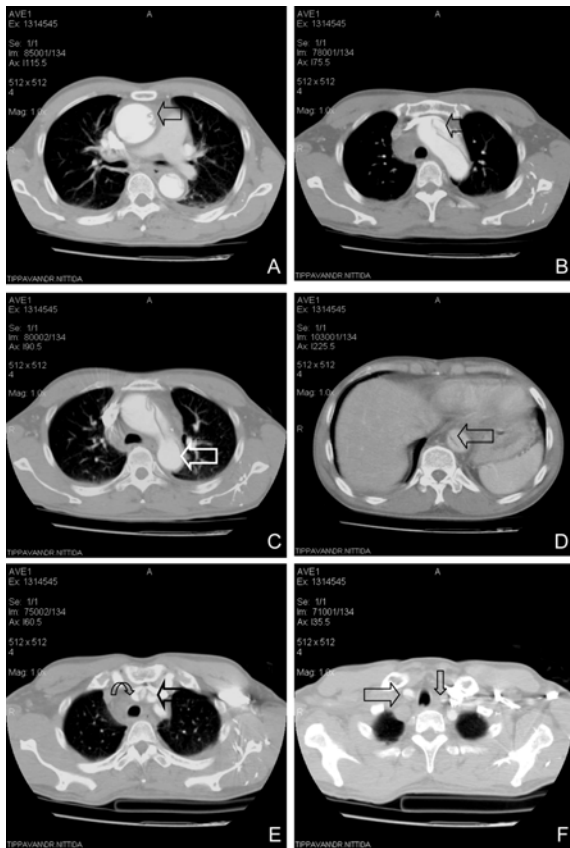
The emergency surgical repair of the aorta was planned immediately but it had to be postponed due to his markedly impaired consciousness and high fever of which aspiration pneumonia was suspected. He received broad-spectrum antibiotics and best supportive treatment in the intensive care unit with partial recovery of his alertness in the next several days. The surgical correction was refused by his relatives and the patient was discharged home. He has been cared regularly for one year in the out-patient department and has some hemiparesis left (motor power of grade 3/5) with partial dependence. No additional cardiovascular disorders were reported.

## Discussion

Neurological disorders as the initial manifestation of type A aortic dissection have been reported in 29% in one recent case series, with a high number of ischemic stroke (16%)<sup>(1)</sup>.

From a literature review, there were some clinical clues for detection of aortic dissection: 1) History of concomitant chest pain. 2) Loss of carotid pulse without audible carotid bruit. 3) Loss or decreased intensity of peripheral pulse. 4) Signs of cardiac tamponade. 5) Unstable vital signs. 6) Diastolic blowing murmur. 7) Signs of dissection of the descending aorta such as paraparesis, mesenteric infarction, and anuria. 8) Widening mediastinum from the chest x-ray. 9) Transient or persistent ST elevation especially in the right coronary artery territory because the common site of aortic dissection that arises at the lateral wall of ascending aorta and the retrograde dissection commonly affects the origin right coronary artery.

A comprehensive review of all the reported cases of aortic dissection presenting with ischemic



**Fig. 3** The contrast enhanced CT scan of the chest demonstrates the aortic dissection. Intimal flap causing double lumens of aorta arises from lateral wall of ascending aorta above the aortic root, approximately at the level of bifurcation of pulmonary artery (A), extend to arch of aorta (B), to descending aorta (C) and terminates at thoraco-abdominal junction-the most distal end of the dissection (D). The dissection also extends upwards to involve Innominate artery (curved arrow) and left common carotid artery. (straight arrow) (E), and finally both common carotid arteries (F)

stroke with Pubmed database is shown in Table 1. They presented with sudden either focal or diffuse neurological disorders and ascending aorta was the common site of dissection in all cases. However, only half of them reported chest or back pain suggestive of aortic dissection. A study has shown that only two-thirds of patients of type A aortic dissection experienced pain, and most of those without neurological presentation reported pain (94%)<sup>(1)</sup>.

Among these clinical clues, Von Kodolitsch et al<sup>(8)</sup> reviewed the likelihood ratio of each sign, symp-

tom, and basic investigation associated with aortic dissection. The study revealed the most helpful clue was pulse deficit (positive LR 47; 95% CI 6.6-333.0), followed by focal neurological deficit (positive LR 33.0; 95% CI 2.0-549), “tear and ribbing pain” (positive LR 10.8; 95% CI 5.2-22.0), migrating pain (positive LR 7.6 95% CI 3.6-16), left ventricular hypertrophy (positive LR 3.2; 95% CI 1.5-6.8), sudden chest pain (positive LR 2.6; 95% CI 2.0-3.5), enlarged aorta or widening mediastinum (positive LR 2.0; 95% CI 1.4-3.1), and history of hypertension (positive LR 1.8; 95% CI 1.4-2.3).

Since the consciousness of the reported case was significantly depressed, the symptom of chest or back pain was unable to be obtained for the initial evaluation. The critical clinical clues for achieving the diagnosis of the fatal condition in the presented case were the difference in the blood pressures and the amplitude of radial pulses between both upper limbs, aortic regurgitation murmur and widening mediastinum in the initial chest radiological study. Computer tomographic scan of chest and transesophageal echocardiography are the very sensitive diagnostic studies for the disorder, however, they are time consuming that would reduce the opportunity of thrombolytic therapy. The simplicity and widely available chest x-ray, though up to 20% may be negative in aortic dissection<sup>(9)</sup>, makes it valuable as a part of the initial assessment of acute stroke sufferers.

Emergency surgical treatment is indicated in type A aortic dissection with favorable outcome in experienced surgical and postoperative care teams. The autopsy series before the era of modern treatment estimated that 40-50% of patients with dissection of proximal aorta died within 48 hours and one-year mortality rate was around 90%<sup>(10)</sup>. Since new treatment regimens have been developed and the patients are immediately operated on, the 30-day survival rate has increased to 80-85% and 10-year survival rate has risen to 55%<sup>(11)</sup>. Surgical correction was refused in the presented case and the patient was treated medically with some improvement in neurological deficit and without additional cardiovascular event reported at one year after the onset. Unlike one of our reviewed cases (case 3), the medical treatment failed and the patient died shortly after it was started. This may partly be due to the origin of the dissection in the reported case which did not involve the root of ascending aorta, in which its complication from hemopericardium or hemothorax usually causes a high mortality rate.

The caution for this life threatening cardiovascular condition should be of concern and it should

**Table 1.** Summary of reported cases of aortic dissection presented with neurological deficits from the literature review

Age (year)	64 <sup>(2)</sup>	64 <sup>(3)</sup>	72 <sup>(4)</sup>	44 <sup>(5)</sup>	49 <sup>(6)</sup>	85 <sup>(7)</sup>	49*
Sex	Female	Male	Female	Male	Male	Female	Male
Presentation	Sudden severe back pain Alteration of consciousness	Sudden severe chest pain Wernicke aphasia	Alteration of consciousness intermittently	Lt hemiparesis	Chest pain and Lt hemiparesis	Recurrent episode of aphasia and right-sided weakness with spontaneous resolution	Alteration of consciousness and Rt. hemiplegia
Associated symptoms, signs and investigation	Absent of right radial pulse Acute aortic regurgitation Cardiac temponade	Absent of right radial pulse	Diminish radial pulse bilaterally	Not mention	Right bundle branch block, and poor R wave progression in V3-6, and ST segment depression in the II, III, and aVF	Hypotension	Difference in BP and radial pulses between both arms Aortic regurgitation murmur
Affected vessel	Ascending aorta Right and left common carotid artery Left subclavian artery	Ascending aorta include aortic root	Ascending aorta Right and left common carotid artery Right subclavian artery	Ascending aorta Descending aorta Common iliac artery	Ascending aorta Descending aorta at the level of superior mesenteric artery	Ascending to descending aorta	Ascending to descending aorta
Treatment	Surgery	Surgery	Medical management	Surgery	Percutaneous cardiopulmonary Support	Surgery	Medical management
Outcome	Survived with left hemeplegia	Expire on postoperative day 7 <sup>th</sup>	Expire 1 day after admission	Survive with left hemiparesis	Expire after 2 days of admission	Expire at the day 4 <sup>th</sup> postoperative	Survive with partial deficit at one year

\* The present case report

be included as a differential diagnosis in the management of acute ischemic stroke patients before the infusion of thrombolytic agent is started. Our reported case was presented at the time that exceeded the golden period of the thrombolytic treatment; hence, it was not initiated for him. However, for the stroke patients who have impaired consciousness and the thrombolytic therapy is clinically indicated, a thorough cardiovascular examination is warranted.

### Conclusion

This cause of ischemic stroke in clinical practices remains uncommon. However, careful and complete cardiovascular examination combined with routine chest x-ray has to be included in the protocols of acute stroke treatment and this fatal condition has to be suspected when thrombolytic therapy for ischemic stroke is planned. The concomitant abnormalities in cardiovascular examinations and chest radiographic study in acute stroke should raise suspicion of this condition. To avoid the unexpected catastrophic outcome of thrombolytic treatment for acute ischemic stroke, none of these clinical evidences can be overlooked.

### References

1. Gaul C, Dietrich W, Friedrich I, Sirch J, Erbguth FJ. Neurological symptoms in type A aortic dissections. *Stroke* 2007; 38: 292-7.
2. Shimazaki Y, Minowa T, Watanabe T, Koshika M, Toyama H, Inui K. Acute aortic dissection with new massive cerebral infarction - a successful repair with ligature of the right common carotid artery. *Ann Thorac Cardiovasc Surg* 2004; 10: 64-6.
3. Wright V, Horvath R, Baird AE. Aortic dissection presenting as acute ischemic stroke. *Neurology* 2003; 61: 581-2.
4. Flemming KD, Brown RD Jr. Acute cerebral infarction caused by aortic dissection: caution in the thrombolytic era. *Stroke* 1999; 30: 477-8.
5. Chua CH, Lien LM, Lin CH, Hung CR. Emergency surgical intervention in a patient with delayed diagnosis of aortic dissection presenting with acute ischemic stroke and undergoing thrombolytic therapy. *J Thorac Cardiovasc Surg* 2005; 130: 1222-4.
6. Kawano H, Tomichi Y, Fukae S, Koide Y, Toda G, Yano K. Aortic dissection associated with acute myocardial infarction and stroke found at autopsy. *Intern Med* 2006; 45: 957-62.
7. Zaidat OO, Ubogu EE, Lerner AJ. Recurrent transient ischemic attacks as the initial presenting manifestation of type A aortic dissection. *Ann Vasc Surg* 2002; 16: 676-8.
8. von Kodolitsch Y, Loose R, Ostermeyer J, Aydin A, Koschyk DH, Haverich A, et al. Proximal aortic dissection late after aortic valve surgery: 119 cases of a distinct clinical entity. *Thorac Cardiovasc Surg* 2000; 48: 342-6.
9. Earnest F, Muhm JR, Sheedy PF. Roentgenographic findings in thoracic aortic dissection. *Mayo Clin Proc* 1979; 54: 43-50.
10. Hirst AE Jr, Johns VJ Jr, Kime SW Jr. Dissecting aneurysm of the aorta: a review of 505 cases. *Medicine (Baltimore)* 1958; 37: 217-79.
11. Burt CW. Summary statistics for acute cardiac ischemia and chest pain visits to United States EDs, 1995-1996. *Am J Emerg Med* 1999; 17: 552-9.

---

ภาวะผนังหลอดเลือดแดงเอออร์ตาปริแยกตัวชนิด เอ นำเสนอด้วยอาการของสมองขาดเลือดเฉียบพลัน ข้อพึงระวังเมื่อจะให้การรักษาด้วยสารละลายลิ้มเลือด: รายงานผู้ป่วย 1 ราย และบททวนวรรณกรรม

ถวายเป็นเงินศรัทธา, พรชัย สติรปัญญา

รายงานผู้ป่วยหนึ่งรายที่มีภาวะผนังหลอดเลือดแดงเอออร์ตาปริแยกตัวชนิด เอ ถูกนำมาด้วยอาการอ่อนแรงแขนขาซีกขวาเฉียบพลัน และระดับความรู้สึกตัวลดลง ภาพถ่ายเอกซเรย์คอมพิวเตอร์สมอง พบภาวะเนื้อสมองตายเฉียบพลันที่โคโรนารีเรดิอาตา ขาหลังของอินเทอรนัลแคปซูลด้านซ้าย ร่วมกับภาวะสมองบวมซีกซ้าย นอกจากนี้ยังพบภาวะเนื้อสมองตายเรื้อรังที่ขาหลังของอินเทอรนัลแคปซูลด้านขวา จากการตรวจร่างกายพบหลักฐานของลิ้นเอออร์ติกริว ความแตกต่างของระดับความดันโลหิตและแรงดันของซีพจรบนแขนทั้งสองข้าง ภาพถ่ายเอกซเรย์ปอดพบว่าไม่มีดีแอสตินัมกว้างมากขึ้น ภาพถ่ายเอกซเรย์คอมพิวเตอร์ทรวงอก พบรอยปริแยกของหลอดเลือดแดงเอออร์ตา ตั้งแต่ส่วนที่เป็นขาขึ้นไปจนถึงกึ่งกลางของส่วนที่เป็นขาหลง เนื่องจากการรักษาทางศัลยกรรมถูกปฏิเสธ ผู้ป่วยจึงได้รับการรักษาทางอายุรกรรม โดยมีความผิดปกติทางระบบประสาทเหลืออยู่หลงเหลืออยู่บางส่วน แต่ไม่มีความผิดปกติทางหลอดเลือดและหัวใจเพิ่มเติมจากนั้น

---