

Case Report

Gastropleural Fistula Following A Splenectomy for Splenic Abscess: A Case Report

Prasit Wuthisuthimethawee MD*,
Surasak Sangkhathat MD**, Charoenkiat Ruegklinag MD**,
Sakda Patrapinyokul MD**, Kamolwish Laoprasopwathana MD***

* *Emergency Unit, Faculty of Medicine, Prince of Songkla University, Hat Yai, Songkhla*

** *Department of Surgery, Faculty of Medicine, Prince of Songkla University, Hat Yai, Songkhla*

*** *Department of Pediatrics, Faculty of Medicine, Prince of Songkla University, Hat Yai, Songkhla*

Gastropleural fistula is a rare condition that occurs as a consequence of various thoraco-abdominal surgical procedures and septic conditions. The diagnosis is difficult, it needs a high index of suspicion and appropriate investigations. There are no previous reports of a patient developing a fistula after a splenectomy procedure. The authors report a twelve-year old boy who developed gastropleural fistula following thoraco-abdominal surgery, a splenectomy. The patient presented with the clinical condition of chronic empyema thoracis and responded well to medical and surgical treatment.

Keywords: *Gastropleural fistula, Splenectomy, Tuberculosis*

J Med Assoc Thai 2008; 91 (8): 1291-5

Full text. e-Journal: <http://www.medassocthai.org/journal>

A fistula between stomach and pleural cavity is a rare complication that occurs because of various thoraco-abdominal surgical procedures and septic conditions⁽¹⁻⁵⁾. This uncommon condition must be considered when a patient has persistent empyema thoracis that does not respond well to appropriate antibiotics, intercostal tube drainage, and surgical procedures. The diagnosis is difficult, needs a high index of suspicion and appropriate investigations, especially radiological contrast media study. There are no previous reports of a patient developing the fistula after a splenectomy procedure. Herein, the authors report a case of gastropleural fistula in a twelve-year-old child who presented with left intractable empyema thoracis following a splenectomy. The case was successfully managed with a series of surgical approach and aggressive pharmacological therapy.

Case Report

A 12-year-old boy was referred to the authors from a provincial hospital with an intractable empyema thoracis in his left chest. The child developed this problem 3 months after a splenectomy for pyogenic splenic abscesses. An attempt to do a thoracotomy in that hospital failed because of severe adhesion. An intercostal tube was left in place after that operation, which drained over 1 liter of purulent discharge each day.

Tracing back to a history of the patient before the splenectomy, the child was brought to the hospital with prolonged fever, abdominal pain and abnormal chest symptoms. The chest radiography revealed left lower lung infiltration and therefore pneumonia was diagnosed. The patient was admitted and received intravenous antibiotics, but his clinical condition failed to improve. Abdominal ultrasound was performed and revealed multiple hypoechoic spots in the splenic parenchyma, compatible with pyogenic splenic abscess. An elective splenectomy was then scheduled and, unfortunately, an exsanguination occurred during the procedure and led to stomach injury. The patient

Correspondence to: Wuthisuthimethawee P, Emergency Unit, Faculty of Medicine, Prince of Songkla University, Hat Yai, Songkhla 90110, Thailand. Phone: 074-451-700-5, Mobile: 08-1540-0203, Fax: 074-451-702, E-mail: prasit0552002@yahoo.com

did not have any serious post-operative complication and was discharged from the hospital 11 days later with the clinical assessment of doing well. The authors could not acquire any data regarding the microbiological investigations effected on him, either before or after the operation. At the follow-up visits at weeks two and four, he had only low grade fever and cough, which were consistent with upper respiratory tract infection, and the doctor treated him with some medications. He was admitted again after another 2 months due to left empyema thoracis, received intravenous antibiotics, intercostal tube drainage, and left thoracotomy procedure.

On admission to Songklanagarind Hospital, the child looked pale and malnourished. His body mass index was 14.3 kg/m². The patient had a swinging fever together with tachycardia and tachypnea. Hematologic examination showed moderate anemia (Hb 5.9 mg/dl) and leucocytosis (WBC 24,300 cells/ml, N71%, L19%). The serum albumin was 2.3 mg/dl. Chest radiography revealed a misplaced thoracic tube and a hazy fluid shadow collected around the left lower chest. Initial therapy included broad spectrum antibiotics, revision of an intercostal tube, and chest physical therapy. However, after a week, the measures failed to expand the lung or get rid of the pus discharge. A chest CT scan detected left lower lung loculated collection with a massive atelectasis (Fig. 1a, 1b).

A left thoracotomy revealed multiple loculated collections, and a restrictive atelectasis caused by severe adhesion at the left lower lobe. The left lower lobe parenchyma appeared destroyed by the infection. In addition, a small rupture about 1 centimeter in diameter was detected on the surface of the left posterior diaphragmatic recess, which was suture-closed. A left lower lobectomy with a decortication of the remaining fibrino-purulent material was performed.

On the third post-operative day, the content from vacuum drain appeared green in color like bile-stained fluid. An upper gastrointestinal study was performed, using water-soluble contrast. The study revealed continuity between the gastric fundus and the left pleural cavity (Fig. 2). A left gastropleural fistula was diagnosed.

An exploratory laparotomy was then performed to divide the fistula and repair the stomach and left diaphragm. The pathological findings from the lobectomy specimen revealed bronchiectasis, atelectasis and multiple granuloma of the left lower lobe, consistent with *Mycobacterium tuberculosis*. However, neither AFB nor fungal stain was positive. A

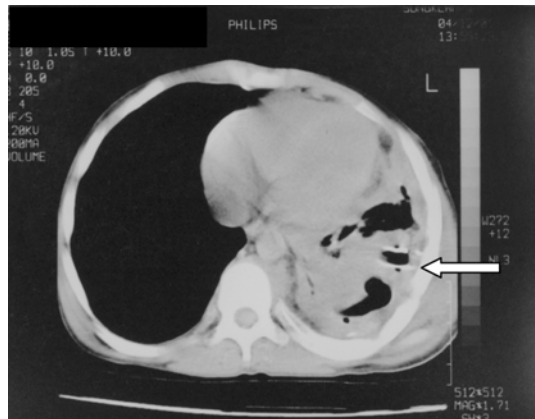


Fig. 1a Chest CT scan demonstrating loculated collections and atelectasis at left lower lung field

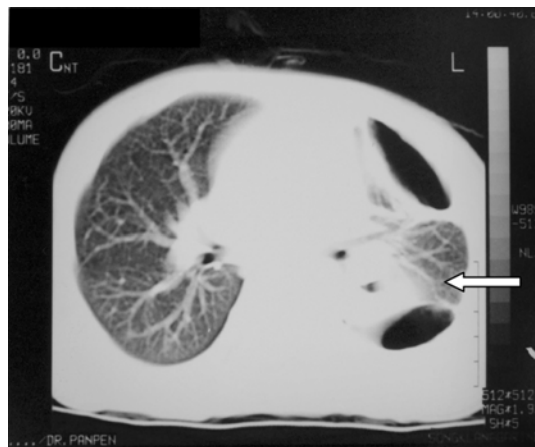


Fig. 1b Chest CT scan demonstrating the same study with contrast clearly demonstrating left lower lobe lesion

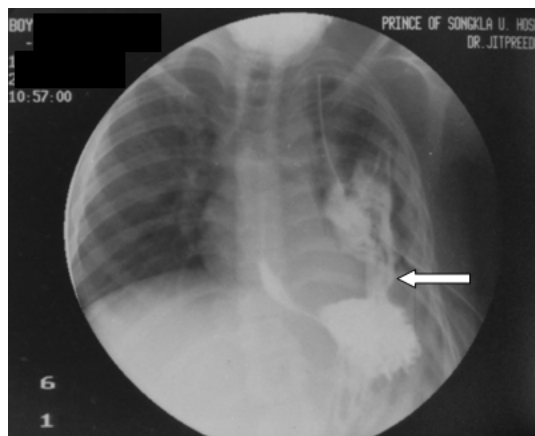

Fig. 2 Gastrograffin contrast medium upper GI study showed fistula tract between gastric fundus and left pleural cavity

microbio-logical study of the lung tissue showed positive culture of *Staphylococcus aureus* (methicillin resistant strain), *Klebsiella pneumoniae* and yeast cells.

A post-operative course of intravenous antibiotics (Fosfomycin and Cefotaxime) was administered. Cessation of the ICD content with declination of fever was achieved around the fourteenth postoperative day. The patient could tolerate enteral diet normally. However, persistent air leakage and un-expandable left lung led to a left thoracoplasty a week later. The child made a good recovery and was discharged from the authors' service on the 40th day of admission with a one-way (Heimlick-type) thoracic tube in place. The tube was removed six weeks later at post-operative follow up. The patient also received oral anti-tuberculous drugs for another six months because *Mycobacterium* species were found in the pus culture. At 6 months of post-operative follow up, his chest x-rays showed satisfactory expansion without signs of recurrent lung infection (Fig. 3). The patient also gained his nutritional status and well-being. His body mass index at the last follow up was 15.2 kg/m².

Discussion

Gastropleural fistula is an uncommon condition. The diagnosis requires both clinical investigations and a high index of suspicion⁽¹⁾. The clinical symptoms are fever, pleuritic chest pain and chronic empyema thoracis as in the presented patient. Chest x-rays, upper

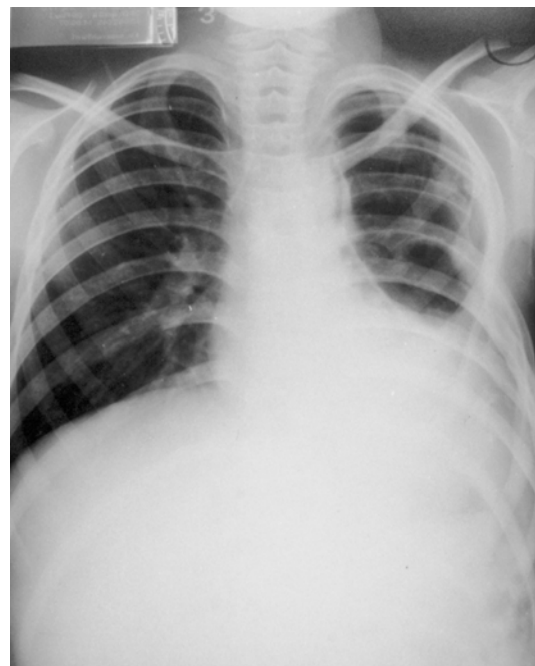


Fig. 3 Chest x-rays at 6 months after removal of the Heimlick tube drainage; the remaining left lower lung haziness resulted from a left lower lobectomy

gastroduodenoscopy and upper gastrointestinal contrast study are useful to confirm this condition.

The pathogenesis of gastropleural fistula has been described following various conditions.

Table 1. Reports of gastropleural fistula

Author (year)	Cause	Number of patient	Treatment	Result
Markowitz et al ⁽⁷⁾ (1960)	Esophageal hiatal hernia with perforation	1	Surgically repaired	Recovery
Rotstein et al ⁽⁶⁾ (1985)	Perforated paraesophageal hernia	1	Surgically repaired	Recovery
Scwhab et al ⁽⁵⁾ (1991)	Post hiatal hernia repair	1	Anitbiotics and drainage	Death
	Gastric bypass operation	1	Surgically repaired	Recovery
	Traumatic diaphragmatic hernia with stomach perforation	1	Thoracotomy, repaired stomach and diaphragm	Recovery
O'Keefe et al ⁽³⁾ (1993)	Pulmonary resection	1	Surgically repaired	Recovery
Anbari et al ⁽⁴⁾ (1993)	Post esophagogastrectomy	2	1 antibiotics and drainage 1 surgically repaired	Recovery Recovery
Warburton et al ⁽¹⁾ (1997)	Gastric lymphoma	1	Total gastrectomy with splenectomy and repaired	Death
Mussi et al ⁽²⁾ (2000)	Postpneumonectomy	1	Surgically repaired	Recovery

Warburton and Calverley⁽¹⁾ reported a patient developing tension pneumothorax, empyema thoracis and gastropleural fistula following total gastrectomy for gastric lymphoma. Mussi et al⁽²⁾ reported a case of gastropleural fistula following pneumonectomy and O'Keefe⁽³⁾ reported this condition as a complication from pulmonary resection. Anbari et al⁽⁴⁾ reviewed patients who underwent esophagogastrectomy and reported that anastomotic leaks or fistula occurred in 16% during the late post-operative period. In 1991, Schwab and Jarvik⁽⁵⁾ reported a case of tension pneumothorax due to a gastropleural fistula resulting from perforation of the stomach in a diaphragmatic hernia. In summary, the condition mostly occurred as a complication of surgical procedures involving the stomach, lower esophagus or lung, or as a consequence of diseases, especially infectious conditions, around this anatomic region.

The cause of gastropleural fistula in this patient was possibly a gastric injury during splenectomy procedure that led to a small or nearly concealed fistula, which may explain the persistent infection. Removal of fibrinous adhesion during thoracotomy in the authors' service expanded the size of the continuity. During the operation the authors did not suspect this condition and closed the diaphragmatic rupture loosely with a heavy suture. The fistula had not been managed until the gastric fundus was completely divided from the inferior diaphragmatic surface. After the abdominal operation, the problem of empyema was also successfully cured, suggesting that there should be a cause-effect relationship between the fistula and the thoracic infection. The possibility that the primary pathology was in the thorax was excluded in the presented case by a negative history of lung disease.

According to a previous report, initial managements of this condition include closed thoracic drainage⁽⁶⁾, chest physical therapy, intravenous antibiotics, and nutritional support. Surgical repair is the mainstay treatment of this condition, although there is also a report of successful conservative treatment in a persistent gastropleural fistula after a gastric bypass procedure⁽⁶⁾. A majority of cases in previous reports responded well to surgical therapy⁽¹⁻⁶⁾. However, the result depended on the time of diagnosis and

treatment, underlying disease and the patient's general condition. Hence, an early diagnosis is mandatory to achieve a satisfactory result. Major causes of death are septic complications.

Conclusion

The present study reported a case of a twelve-year old boy who developed gastropleural fistula following thoraco-abdominal surgery, a splenectomy. The authors conclude that in patients presenting with the clinical condition of chronic empyema thoracis, particularly those with persistent voluminous drainage following thoraco-abdominal procedure, a gastropleural fistula should always be suspected.

Acknowledgements

The authors wish to thank Dr. Alan Geater and the International Relation office for checking the English.

References

1. Warburton CJ, Calverley PM. Gastropleural fistula due to gastric lymphoma presenting as tension pneumothorax and empyema. *Eur Respir J* 1997; 10: 1678-9.
2. Mussi A, Lucchi M, Davini F, Angeletti CA. Gastropleural fistula as complication of post-pneumonectomy empyema. *J Cardiovasc Surg (Torino)* 2000; 41: 147-9.
3. O'Keefe PA, Goldstraw P. Gastropleural fistula following pulmonary resection. *Thorax* 1993; 48: 1278-9.
4. Anbari MM, Levine MS, Cohen RB, Rubesin SE, Laufer I, Rosato EF. Delayed leaks and fistulas after esophagogastrectomy: radiologic evaluation. *AJR Am J Roentgenol* 1993; 160: 1217-20.
5. Schwab RJ, Jarvik JG. Tension pneumothorax secondary to a gastropleural fistula in a traumatic diaphragmatic hernia. *Chest* 1991; 99: 247-9.
6. Rotstein OD, Pruett TL, Simmons RL. Gastropleural fistula. Report of three cases and review of the literature. *Am J Surg* 1985; 150: 392-6.
7. Markowitz AM, Herter FP. Gastro-pleural fistula as a complication of esophageal hiatal hernia. *Ann Surg* 1960; 152: 129-34.

รายงานผู้ป่วยภาวะ *gastropleural fistula* ภายหลังการผ่าตัดม้าม

ประสิทธิ์ วุฒิสุทธิเมธาวิ, สุรศักดิ์ สังขทัต ณ อยุธยา, เจริญเกียรติ ฤกษ์เกลี้ยง, ศักดา ภัทรภิญโญกุล, กมลวิช เล่าประสพวัฒนา

ภาวะ *gastropleural fistula* เป็นภาวะที่พบบ่อย มักเป็นภาวะแทรกซ้อนที่เกิดภายหลังการติดเชื้อ หรือ การผ่าตัดในช่องท้องและช่องอก ภาวะนี้วินิจฉัยค่อนข้างยาก จำเป็นต้องได้รับการตรวจทางห้องปฏิบัติการที่สำคัญ โดยเฉพาะการถ่ายภาพเอกซเรย์รวมกับการกลืนสารทึบแสงเป็นต้น ผู้นิพนธ์รายงานผู้ป่วยอายุ 12 ปี เกิดภาวะติดเชื้อ รื้อรังในช่องเยื่อหุ้มปอดด้านซ้าย และเกิดภาวะ *gastropleural fistula* ภายหลังการตัดม้าม ซึ่งผู้ป่วยตอบสนองดี ต่อการรักษาด้วยยาและการผ่าตัด
