

Anatomical Study of the Superior Gluteal Artery Perforator (S-GAP) for Free Flap Harvesting

Tanvaa Tansatit MD*, Prayuth Chokrungraranont MD**,
Pasinee Sanguansit MSc*, Samang Wanidchaphloi MSc*

* Department of Anatomy, Faculty of Medicine, King Chulalongkorn Memorial Hospital, Chulalongkorn University, Bangkok

** Unit of Plastic Surgery, Department of Surgery, Faculty of Medicine, King Chulalongkorn Memorial Hospital,
Chulalongkorn University, Bangkok

Objective: To present the appropriate superior gluteal branch for free flap harvesting.

Material and Method: The characteristic and external diameter of the pedicles and the main perforators, and length of the pedicles were studied in both sides of 30 formalin-preserved cadavers.

Results: The patterns of the pedicle could be classified into four types, the vertical, the horizontal, the descending, and the penetrating main branches. The descending branch was the longest (7.33 ± 1.3 cm). While the pedicle and perforator of the horizontal branches was the largest (2.7 ± 0.6 mm and 1.2 ± 0.2 mm, respectively). However, it was difficult to dissect the vertical and the horizontal branches because the vessel courses did not run in the direction of the muscle fiber. Whereas the penetrating main branches were observed in the intermuscular septum so, it was easy to approach the pedicle. The length (5.3 ± 1.3 cm) and external diameter (2.17 ± 0.5 mm) of the pedicle were adequate for free flap harvesting.

Conclusion: In the anatomical study, the penetrating pedicle was recommended to use for the S-GAP flap.

Keywords: Superior gluteal artery, Perforator flap

J Med Assoc Thai 2008; 91 (8): 1244-9

Full text. e-Journal: <http://www.medassocthai.org/journal>

Breast reconstruction following modified radical mastectomy with autogenous tissue is rather complicated and technically difficult but the result is excellent and permanent⁽¹⁾. Many patients have a history of radiation to the chest wall, so silicone breast Implantation is difficult to perform and may likely result in failure⁽²⁾. The abdomen with an incisional scar or thin young abdomen is not a suitable donor site. Patients undergoing reconstruction with musculocutaneous flaps from abdominal area can suffer from postoperative hernias or weakness in the abdominal muscles⁽³⁻⁵⁾. The first-line alternative in patients in whom the abdomen is inadequate as a donor site could be the buttocks^(4, 6-10). This flap provides adequate tissue to perform the reconstruction. After Koshima

et al⁽¹¹⁾ reported their cases on the perforator flaps. This innovation had been accomplished in breast reconstruction by the development of the superior gluteal artery perforator (S-GAP) free flap by Allen and Tucker⁽⁴⁾. The avoidance of resection of the gluteus maximus muscle decreased the rigidity of the flap and increased the pedicle length, providing flexibility in positioning and shaping the flap. The tedious dissection of the perforator should be managed with profound anatomical knowledge of the vessel⁽⁶⁾. The purpose of the present paper is to present anatomical overview of this flap and the practical surgical suggestion based on this fact for successful flap harvesting.

Material and Method

Anatomical dissection was performed on 30 formalin-preserved adult human cadavers. All were self-donated for teaching and investigation from the Department of Anatomy, Faculty of Medicine, Chulalongkorn University. The dissection was begun

Correspondance to: Tansatit T, Department of Anatomy, Faculty of Medicine, King Chulalongkorn Memorial Hospital, Chulalongkorn University, Bangkok 10330, Thailand. Phone: 0-2256-4281, 0-2252-7028, Fax: 0-2256-4281, 0-2252-7028, E-mail: tansatit@yahoo.com

laterally over the tensor fascia lata. After the skin incision was made through the subcutaneous fat, the gluteal muscle fascia was identified and elevated. A dissection plane between the fascia and the muscle was established. The superior gluteal artery perforators were identified and preserved. The locations related to anatomical landmark was documented and photographed. External diameter of each perforator was measured as it emerged from the fascia of the gluteus maximus muscle using venire calipers. Then perforators were dissected down to the superior gluteal vascular pedicle. For optimal exposure of the superior gluteal artery, the gluteus maximus muscle was incised on the insertion at the proximal femur and reflected medially revealing the superficial branches of the artery beneath. The pattern of branching was diagrammed and photographed. The pedicle lengths were measured from the skin insertion to the main artery. External diameters were measured at origin of the pedicle. The relationships of nerves to the vascular perforators were observed.

Results

The superior gluteal artery arises from the internal iliac artery in the lateral pelvic wall. This artery passed the greater sciatic foramen out of the pelvis above the piriformis muscle supplying the upper half of the gluteus maximus muscle, the gluteus medius and the gluteus minimus muscles. As it passed the greater sciatic foramen, it divided into a superficial and a deep branch. The deep branch coursed between the gluteus medius muscle and the gluteus minimus muscle, spreading branches parallel to the muscular fascial plane. The superficial branch exits the pelvis through the suprapiriform foramen was marked at the middle of a line connecting the posterior superior iliac spine (PSIS) and coccyx.

The superficial branch divided into 2-7 main branches (Fig. 1). These branches coursed deep to and supplied the gluteus maximus muscle and the overlying skin territory by musculocutaneous and septocutaneous perforators. Three of seven main branches were constant and distributed their muscular branches in the fascial plane between the under surface of the gluteus maximus muscle and the gluteus medius muscle. Their perforators arranged in a line along the upper and lateral free border of the gluteus maximus muscle (Fig. 2). This line was parallel inferiorly by a line marked by connecting the PSIS with the greater trochanter. Superior branches were found to take a vertical direction to the iliac crest, the middle branch

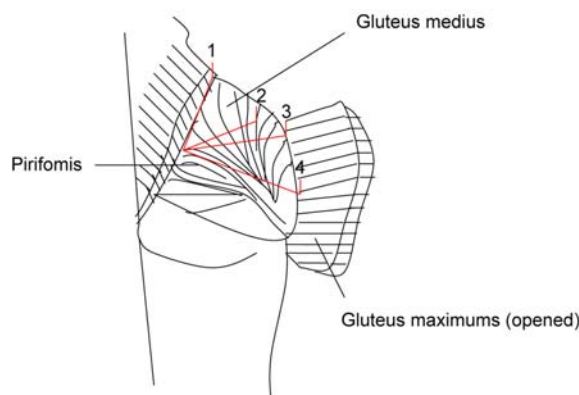


Fig. 1 This diagram showed distribution of the superficial branches of the superior gluteal artery. 1; vertical main branch, 2; penetrating main branch, 3; horizontal main branch, and 4; descending main branch

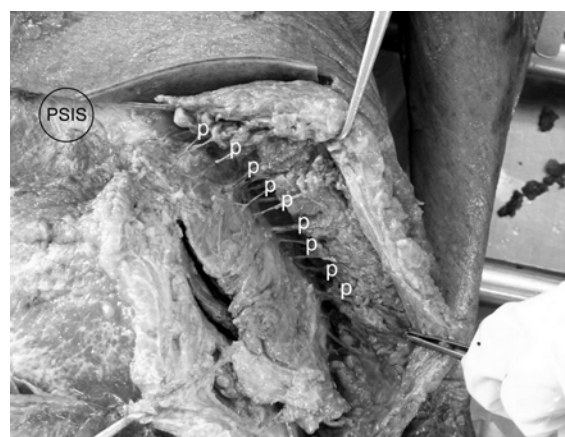


Fig. 2 The perforators (p) arrange in a line along the upper and lateral free border of the gluteus maximus muscle

took a horizontal direction and the inferior branch took oblique descending direction to the greater trochanter and coursing parallel to the muscle fiber (Fig. 3). Any one of these perforators could be dissected from the underlying muscle to form the pedicle of the superior gluteal flap. The dissection proceeded toward the sacrum.

The other main branches usually penetrated obliquely through the gluteus maximus at the beginning and provided subcutaneous and skin perforators. These perforators generally located medial to the lateral border of gluteus maximus about 2.85 cm (Fig. 4). The pedicle of these perforators was easily approached by splitting in the direction of the muscle fiber. Otherwise, the vertical and horizontal main branches were difficult

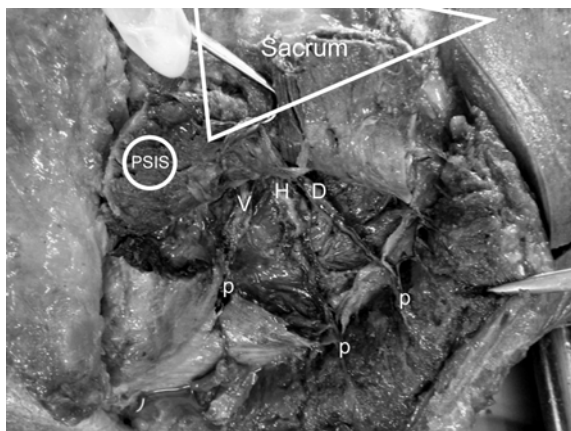


Fig. 3 The superior branch were found to take a vertical direction (V) to the iliac crest, middle branch took a horizontal direction (H) and inferior branch took oblique descending direction (D) to the greater trochanter and coursing parallel to the muscle fiber. p; perforator

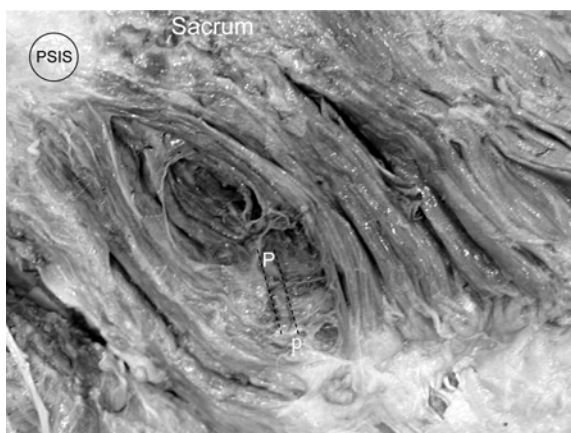


Fig. 4 The penetrating main branch (P) usually penetrated through the gluteus maximus and provided subcutaneous and skin perforators at the medial line to lateral border of gluteus maximus. P; perforator

to dissect because they coursed obliquely to the muscle fibers.

Many cutaneous perforators were found throughout the gluteal region. There were 2-7 main perforators per flap (an average of 4 perforators per flap). Each main perforator was the largest perforator of each main branch. The external diameter of the main perforators ranged from 0.5 to 1.7 mm (an average of 1.17 mm). The pedicle length from the skin to the main artery ranged from 3 to 11.5 cm (an average of 5.84 cm) and the external diameter at its origin of the pedicle ranged from 0.9 to 4.0 mm (an average of 2.42 mm). The gluteus maximus muscle can be preserved during the deep dissection of the flap harvesting. The details of the main branches of the superficial branches are described in Table 1.

The vertical main branch was the shortest. The length of the vertical main branches ranged from 3 to 6 cm (an average of 4.5 ± 0.79 cm) and their external diameter was usually between 1.4 and 3.5 mm (an average of 2.40 ± 0.52 mm). External diameter of the main perforators was 0.7 to 1.8 mm with an average of 1.14 ± 0.25 mm, while three flaps from 60 flaps did not have vertical main branches and the other three vertical main branches did not provide cutaneous perforator as shown in Table 1.

The diameters of the horizontal main branch and its main perforator were the largest. Their external diameter was usually between 1.2 and 4.0 mm (an average of 2.72 ± 0.60 mm). External diameter of main perforators was 0.7 to 1.7 mm (an average of 1.22 ± 0.22 mm). The length of horizontal main branches ranged from 3.8 to 9.5 cm with an average of 6.44 ± 1.31 cm, while two flaps from 60 flaps did not have horizontal main branches and another one horizontal main branches did not provide cutaneous perforator as demonstrated in Table 1.

The descending main branch was the longest pedicle. The length of descending main branches ranged from 4.8 to 11.5 cm (an average of 7.33 ± 1.28 cm).

Table 1. Summary of mean \pm SD (range) of length and external diameter of pedicle and external diameter of main perforator

Branch	Number of perforator	Length of pedicle (cm)	Diameter of pedicle (mm)	Diameter of perforator (mm)
Vertical	54	4.59 ± 0.79 (3.0-6.0)	2.40 ± 0.52 (1.4-3.5)	1.15 ± 0.25 (0.7-1.8)
Horizontal	57	6.44 ± 1.30 (3.8-9.5)	2.72 ± 0.60 (1.2-4.0)	1.22 ± 0.22 (0.7-1.7)
Descending	46	7.33 ± 1.28 (4.8-11.5)	2.38 ± 0.62 (0.9-3.6)	1.14 ± 0.27 (0.5-1.7)
Penetrating	49	5.30 ± 1.34 (3.0-8.7)	2.17 ± 0.50 (1.1-3.5)	1.14 ± 0.20 (0.7-1.7)

Table 2. The number of penetrating branch

Number of branch	Number of flap	Percent
0	11	18.33
1	25	41.67
2	18	30.00
3	2	3.33
4	4	6.67
Total	60	100.00

cm) and their external diameter was usually between 0.9 and 3.6 mm (an average of 2.3 ± 0.62 mm). External diameter of main perforators was 0.5 to 1.7 mm with an average of 1.14 ± 0.27 mm, while three flaps from 60 flaps did not have descending main branches and the other 11 descending main branches did not provide cutaneous perforator are shown in Table 1.

The penetrating main branches that ran through the gluteus maximus were found 1-4 branches per flap. Only one branch was mostly found in each flap (Table 2). The length of the penetrating main branch ranged from 3.0 to 8.7 cm (an average of 5.3 ± 1.34 cm) and their external diameter from 1.1 to 3.5 mm (an average of 2.17 ± 0.50 mm). External diameter of main perforators was 0.7 to 1.7 mm with an average of 1.14 ± 0.20 mm, while 11 flaps from 60 flaps did not have penetrating branch as demonstrated in Table 1.

The superior cluneal nerves provided sensation to the flap. They originated from the dorsal branches of the first to the third lumbar segmental nerves and perforated the superficial layer of the thoracolumbar fascia at its lateral border, just above the iliac crest lateral to the posterior superior iliac spine. Vascular perforators from the segmental vessels accompanied the nerves. They pierced the thoracolumbar fascia 6.56 ± 1.11 cm (3.5-9.0 cm) from the midline and 1.52 ± 1.03 cm (0-3.8 cm) above the PSIS. Then they provided sensate innervation to the superior part of the buttock (Fig. 5).

The inferior gluteal nerve from the ventral rami of L5-S1 nerve left the pelvis through the greater sciatic foramen inferior to the piriformis and divided into several branches then supplied gluteus maximus. These nerves usually ran anterior to the descending main branch before entering the muscle (Fig. 6).

Discussion

During the S-GAP flap harvesting, only fat and skin from the gluteal region are harvested. Dissection of the vascular structures out of the muscle

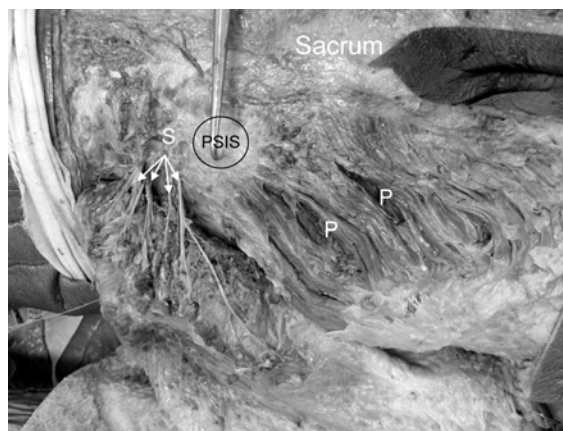


Fig. 5 The superior cluneal nerves (S) provided sensate innervation to the superior part of the buttock. P; penetrating main branch

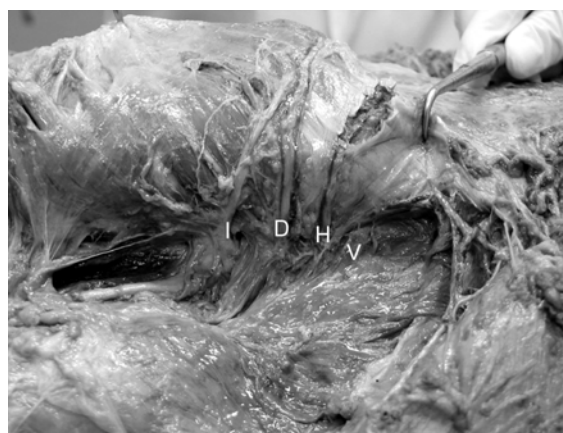


Fig. 6 The gluteus maximus was cut and reflected from its insertion. The inferior gluteal nerve (I) divided into several branches then supplied gluteus maximus. These nerves usually ran anterior to descending main branch before entering the muscle

proved to be advantageous by providing a long pedicle, which microvascular anastomosis can be performed without the need for vein graft^(7,12). The nature of the fat in the gluteal region tends to be more rigid than abdominal fat, which allows for creation of a breast with good projection, natural firmness, and adequate volume. Shaping and inseting the flap at the chest wall using the internal mammary vessels or the thoracodorsal vessels as the recipients is feasible because of the long flap pedicle^(4,6). In this study, the authors' dissections show the pattern, length, and external diameter of pedicles and perforators of

superior gluteal artery, which have not previously been described. This information has implications for S-GAP flap harvesting.

The pattern of the pedicle of superior gluteal artery was classified into four types, the vertical, the horizontal, the descending, and the penetrating main branches. The average external diameter of the pedicle and the main perforator of the horizontal main branches were the largest (2.7 ± 0.6 mm and 1.2 ± 0.2 mm, respectively). These perforators usually arrange in a line along lateral border of gluteus maximus muscle. Contrast with the five cadaver studies of Koshima⁽¹⁾, who described the several main perforators of large caliber were found in the parasacral and central portions of the gluteal muscle. In addition, Koshima⁽¹⁾ reported that the total number of perforator supply the entire gluteal region was 20 to 25 in each cadaver. The length of the vessels ranged from 3 to 8 cm and their diameter ranged from 1 to 1.5 mm. The present study found that the pedicle length ranged 3 to 11.5 cm and the external diameter of pedicle was 0.9-4.0 mm. The different results are probably because of the smaller number of specimens of Koshima⁽¹⁾ compared with the present study.

Aldo⁽⁷⁾, who review 142 patient charts from breast reconstruction with S-GAP flap reported that the pedicle length between 8 and 12 cm and artery diameter 2 mm or greater were used for S-GAP flap harvesting. Blondeel⁽⁶⁾ reported that the mean length of the vascular pedicle was 7.8 cm and varied between 6 and 10.5 cm. All S-GAP flaps were vascularised by one single perforator, located around the line drawn preoperatively between the PSIS and the greater trochanter of the femur. In the present study, it was demonstrated that the average length of the descending pedicle was the longest (7.33 ± 1.3 cm). The average external diameter of the pedicle and the main perforator of the horizontal pedicle were the largest (2.7 ± 0.6 mm and 1.2 ± 0.2 mm, respectively). However, it was difficult to dissect the vertical and the horizontal main branches because the vessel courses did not run in the direction of the muscle fibers. The descending main branch had longer pedicle and coursed parallel to the muscle fibers. The dissection of the descending main branch was difficult and hazardous because of the regional thickness of the gluteus maximus muscle at its insertion, the strong and tough tensor fascia lata, and the inconstant perforators. Because the pedicle of the penetrating main branch lay in a single muscle fiber cleavage plane, very few muscle fibers were sacrificed. The average length of the penetrating pedicle was 5.3 ± 1.3 cm. The average external diameter of the pedicle and

the main perforator of the penetrating pedicle were 2.17 ± 0.5 mm and 1.1 ± 0.2 mm, respectively. There were adequate length and diameter of the penetrating pedicle and the main perforator for free flap harvesting.

The superior cluneal nerves entered the flap at its superior border. These nerves could be harvested with the flap and anastomosed to the anterior ramus of the lateral branch of the fourth intercostal nerve at the recipient site. In this case, the outline of the flap should be planed close to the iliac crest to allow the nerves to cross the incision line. The inferior gluteal nerve usually ran anterior to the descending branch before entering the muscle. Therefore, surgeons should be aware of this nerve during S-GAP flap harvesting.

In conclusion, the penetrating pedicle, which is usually found within 3 cm medial to the lateral border of the gluteus maximus, is recommended to use for the S-GAP flap. The penetrating pedicle lay in a single muscle fiber cleavage plane therefore, very few muscle fibers are sacrificed. The muscle is split as needed in the direction of its fibers. The anatomical feature and the surgical procedure are equally important in the success of flap harvesting. Future clinical study should focus further.

References

1. Koshima I, Moriguchi T, Soeda S, Kawata S, Ohta S, Ikeda A. The gluteal perforator-based flap for repair of sacral pressure sores. *Plast Reconstr Surg* 1993; 91: 678-83.
2. Shaw WW. Breast reconstruction by superior gluteal microvascular free flaps without silicone implants. *Plast Reconstr Surg* 1983; 72: 490-501.
3. Shaw WW. Superior gluteal free flap breast reconstruction. *Clin Plast Surg* 1998; 25: 267-74.
4. Allen RJ, Tucker C Jr. Superior gluteal artery perforator free flap for breast reconstruction. *Plast Reconstr Surg* 1995; 95: 1207-12.
5. Guerra AB, Allen RJ, Dupin CL. Breast reconstruction with the superior gluteal artery perforator (S-GAP) flap. *Semin Plast Surg* 2002; 16: 27-34.
6. Blondeel PN. The sensate free superior gluteal artery perforator (S-GAP) flap: a valuable alternative in autologous breast reconstruction. *Br J Plast Surg* 1999; 52: 185-93.
7. Guerra AB, Metzinger SE, Bidros RS, Gill PS, Dupin CL, Allen RJ. Breast reconstruction with gluteal artery perforator (GAP) flaps: a critical analysis of 142 cases. *Ann Plast Surg* 2004; 52: 118-25.
8. Allen RJ, Treece P. Deep inferior epigastric perforator flap for breast reconstruction. *Ann Plast Surg*

- 1994; 32: 32-8.
9. Hartrampf CR, Schefflan M, Black PW. Breast reconstruction with a transverse abdominal island flap. *Plast Reconstr Surg* 1982; 69: 216-25.
 10. Grotting JC, Urist MM, Maddox WA, Vasconez LO. Conventional TRAM flap versus free microsurgical TRAM flap for immediate breast reconstruction. *Plast Reconstr Surg* 1989; 83: 828-41.
 11. Koshima I, Soeda S. Inferior epigastric artery skin flaps without rectus abdominis muscle. *Br J Plast Surg* 1989; 42: 645-8.
 12. Guerra AB, Soueid N, Metzinger SE, Levine J, Bidros RS, Erhard H, et al. Simultaneous bilateral breast reconstruction with superior gluteal artery perforator (SGAP) flaps. *Ann Plast Surg* 2004; 53: 305-10.

การศึกษากายวิภาคระบบประสาทและหลอดเลือดของ superior gluteal artery perforator flap

ธันวา ตันสถิตย, ประยุทธ์ โชครุ่งวรานนท์, ภาสินี สงวนสิทธิ์, สำอาง วณิชชาพลอย

วัตถุประสงค์: เพื่อนำเสนอ แขนงของ superior gluteal artery ที่เหมาะสมสำหรับการผ่าตัด

วัสดุและวิธีการ: ทำการชำแหละศพ 30 ศพ โดยศึกษาถึง รูปแบบ ความยาว และ เส้นผ่าศูนย์กลางของ pedicle และ perforator

ผลการศึกษา: จำแนกรูปแบบ pedicle ได้ 4 แบบคือ แขนง vertical แขนง horizontal แขนง descending และแขนง penetrating โดยแขนง descending มีความยาวมากที่สุด (7.33 ± 1.3 ซม.) ส่วนแขนง horizontal มีขนาดของ pedicle และ perforator ใหญ่ที่สุดคือ 2.7 ± 0.6 มม. และ 1.2 ± 0.2 มม. ตามลำดับ แต่การผ่าตัดแขนง vertical และแขนง horizontal นั้นทำได้ยากเนื่องจากเส้นทางของหลอดเลือดนั้นไม่ได้ทอดตัวในทิศทางเดียวเส้นใยกล้ามเนื้อ ในขณะที่การผ่าตัดแขนง penetrating สามารถทำได้ง่าย เนื่องจากเส้นทางของหลอดเลือด ทอดตัวไปในทิศทางขนานกับเส้นใยของกล้ามเนื้อ แขนง penetrating นี้มีขนาดโดยเฉลี่ย 2.17 ± 0.5 มม. และมีความยาวโดยเฉลี่ย 5.3 ± 1.3 ซม. ซึ่งเพียงพอสำหรับการผ่าตัด

สรุป: จากลักษณะทางกายวิภาค แนะนำให้ใช้แขนง penetrating ในการผ่าตัด superior gluteal artery perforator flap
