

Case Report

Iatrogenic Chylothorax in Major Burn Patient: Case Report and Literature Review

Pornprom Muangman MD*,
Jeffrey R Scott MD**, Saipin Muangman MD***,
Rachanee Benjathanung HN*, Supaparn Suvanchote RN*

* Burn Unit, Trauma Division, Department of Surgery, Faculty of Medicine Siriraj Hospital,
Mahidol University, Bangkok, Thailand

** Division of Plastic Surgery, Harborview Medical Center, University of Washington, Seattle, USA

*** Department of Anesthesiology, Faculty of Medicine Siriraj Hospital, Mahidol University, Bangkok, Thailand

Chylothorax is a potentially life-threatening form of pleural effusion containing lymphatic fluid. Its etiology may be either traumatic (either post-operative or a direct result of injury), a congenital abnormality of the thoracic duct, or non-traumatic. This is a case report of a left iatrogenic chylothorax, which developed 2 days after internal jugular vein catheterization, in a patient with 50% total body surface area (TBSA) burns. This complication was treated successfully by tube thoracostomy and oral supplementation with a low fat, high carbohydrate, high protein diet. Further, the authors review the etiology, pathogenesis, clinical presentation and recommended management of catheter-related chylothorax.

Keywords: Chylothorax, Burn, Catheter

J Med Assoc Thai 2008; 91 (3): 417-20

Full text. e-Journal: <http://www.medassocthai.org/journal>

Chylothorax is a relatively uncommon, but potentially life-threatening disorder with profound respiratory, nutritional and immunologic consequences. It is usually caused by a traumatic injury to the thoracic duct or one of the other major lymphatics in the thorax⁽¹⁻³⁾.

Catheter-related chylothoraces have only occasionally been reported⁽⁴⁻⁶⁾ despite the frequent use of the central veins for total parenteral nutrition (TPN) and hemodynamic monitoring. An additional indication for central venous catheterization is present in burn patients who require massive fluid resuscitation. In the present paper, the authors describe a case of iatrogenic chylothorax after internal jugular vein catheterization in a major burn patient, and a review of iatrogenic chylothorax.

Case Report

A 58-year-old man with clinical burn wound sepsis was admitted to Siriraj Burn Unit, Siriraj Hospital, in Bangkok, Thailand. He was referred from a rural hospital with a diagnosis of burn wound sepsis. The patient had sustained a 50% body surface area flame burn with a concomitant right hemothorax following an automobile explosion. His right hemothorax was managed by continuous drainage of the pleural space with thoracostomy tube. On the day following admission to our burn unit, the dead tissues on his burn wounds were removed by tangential excision (Fig. 1). On postoperative day 3, the patient developed a high fever and a leukocytosis. A central venous line in his left femoral vein was removed due to erythematous change. A replacement catheter was inserted into the left internal jugular vein at the junction of the sternal and clavicular heads of the sternocleidomastoid muscle as shown in Fig. 2. The next day, the patient became tachypneic, dyspneic, and hypoxic. Breath sounds over the left chest were decreased on auscultation compared with the right chest. A plain chest radiograph revealed

Correspondence to: Muangman P, Burn Unit, Trauma Division, Department of Surgery, Faculty of Medicine, Siriraj Hospital, Mahidol University, Bangkok Thailand. Phone: 02-2453049, 08-9015-0884, E-mail: pmuangman@yahoo.com, muangman@u.washington.edu

near-total ground-glass appearance of the left hemithorax with minimal shift of trachea to the right (Fig. 3).

A diagnostic thoracentesis was performed, which yielded a milky pleural fluid (Fig. 4). On laboratory analysis, it demonstrated 95,378 red blood cells/ μ l and 76,000 white blood cells/ μ l (82% lymphocytes, 18% monocytes/macrophages). The lactate dehydrogenase (LDH) of the fluid was 204 U/L, sugar was 115 mg/dl, protein was 3.4 g/dl, and amylase was 55 IU/L. The triglycerides were 485 mg/dl and total cholesterol was 40 mg/dl. A standard 30 French thoracostomy tube was placed into his left pleural space and 1400 milliliters of

pinkish, milky-appearing chylous fluid was drained. The patient symptomatically improved immediately after the thoracostomy tube insertion, however; he went on to require mechanical ventilatory support due to burn wound sepsis. He was then placed on a low-fat, high-protein, high-carbohydrate enteral diet. Thoracostomy tube output decreased rapidly over the following four days (1400 ml on the first day, 700 ml on the second day, 240 ml on the third day and less than 50 ml/day from the fourth day). The color of fluid also changed to a clear, yellow color 4 days later. Due to burn sepsis, he required mechanical ventilatory support. The chest tube

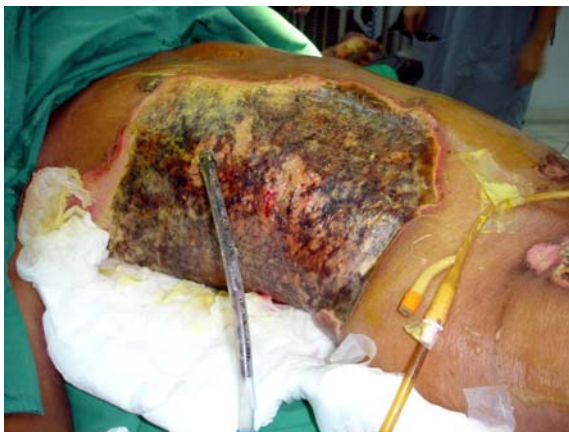

Fig. 1 Characteristic of burn wound

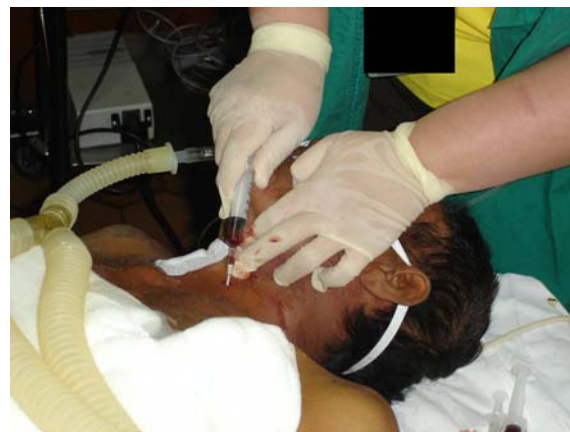

Fig. 2 Internal jugular vein catheterization

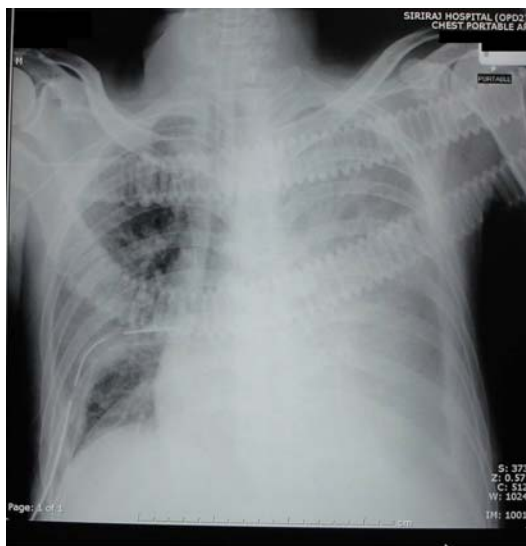


Fig. 3 Left hemothorax with minimal shift of trachea to the right

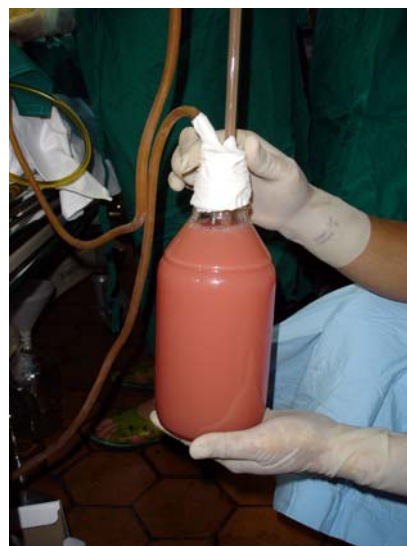

Fig. 4 Iatrogenic chylothorax

was removed on the seventh day, and no recurrent effusion was noted on the follow-up chest radiograph in the burn ICU. The patient died 10 days later, ultimately succumbing to burn wound sepsis.

Discussion

Chylothorax is a life-threatening form of pleural effusion. Its etiology may be either a traumatic, iatrogenic or congenital anomaly of the thoracic duct⁽¹⁾. Usually, the thoracic duct arises from the cisterna chyli at the first lumbar vertebra level. It travels upward through the abdominal and chest cavities and extends behind the left subclavian artery up to 4 cm above the clavicle. It then angles forward acutely and enters the venous system near the junction of the left subclavian and internal jugular vein. Iatrogenic chylothorax due to central venous catheterization have rarely been described in the literature. The degree of injury varies. It may involve disruption of the thoracic duct, catheter-induced intrinsic thrombosis of lymphatic-venous system or extrinsic venous compression from the extravasated fluid⁽⁴⁻⁷⁾. Venogram and the time elapsed before chylothorax appears helpful to differentiate among them.

Previous publications have reported that a latent period of less than 2 weeks and rarely more than a month⁽⁸⁻⁹⁾ often elapses between the trauma and the appearance of chylous fluid. In this patient, there was a delay of only 1 day before the chylothorax became clinically apparent. Given such a short latent period, the most likely cause is direct injury of the thoracic duct. The principal function of the thoracic duct is to convey absorbed fat, and predominantly triglyceride and cholesterol, from intestinal lymphatics into the venous circulation. Chyle fluid is milky in color, odorless, exudative, bacteriostatic and lymphocyte predominant.

The diagnosis is based on the lipid composition of the fluid (high triglycerides, lymphocyte predominance and the presence of chylomicrons with low cholesterol⁽²⁾). In addition, the lipid profile differentiates chylothorax from pseudochylothorax, a fluid with a chyle-like appearance but with no lymphatic connection, containing very high concentrations of cholesterol but no triglycerides or chylomicrons. Pseudochylothorax can develop when fluid is present for a long time in the pleural space or in the setting of fibrotic pleura.

It is possible to differentiate chylothorax from empyema by a screening triglyceride level. Triglyceride level in pleural fluid greater than 110mg/dl has a 99% chance of being chylous in origin, as opposed to a 5%

chance with level less than 50 mg/dl. Further lipoprotein analysis should be done if the results are indeterminate⁽¹⁰⁾. The initial treatment for chylothorax consists of thoracostomy drainage and dietary manipulation. Three possible dietary options have been utilized in treating patients with chylothorax. Fat-free, high-protein, high-carbohydrate diets, high-protein, high-carbohydrate diet using medium chain triglycerides as a sole source of fat, and bowel rest with TPN are three dietary methods which have been proposed. All have been applied successfully in the reported catheter-related chylothoraces⁽⁹⁾. Previous studies have demonstrated an advantage of TPN over enteral nutrition in treatment of chylothorax⁽¹¹⁾. The principle of reduction of chyle production drives the various dietary manipulations.

In the present case, the authors did not choose bowel rest with TPN due to a spontaneous rapid reduction of chyle output and absence of severe metabolic or immunologic consequences. The authors utilized a low-fat, high-protein, high-carbohydrate diet initially, with observation of the daily chyle output from the thoracostomy tube. In addition, judicious use of PEEP in this patient might have helped seal the injured thoracic duct against the pleura, as described by Kurtz and Hsu⁽¹²⁾.

Usually, the conservative treatment should be attempted for 2 weeks. Surgical intervention should be considered when the following criteria are met: (1) chylous drainage for more than 14 days; (2) drainage greater than 1,500 ml/day for adults or greater than 100ml/year-age/day for children over 5 years of age; (3) metabolic complications⁽¹³⁾. Once the decision to perform surgery is made, thoracic duct ligation, often by supradiaphragmatic approach, is generally the most favored approach. Unfortunately, difficulty in identifying the leaking site frequently complicates the procedure. In this situation, the pleurodesis or pleurectomy to obliterate the pleural space might be considered. Pleuroperitoneal shunting has also been performed with success, but mainly for non-traumatic chylothorax⁽¹⁴⁾.

On the basis of this clinical report and of a review of the literature, it is concluded that adequate conservative management should be initially the treatment of choice. Surgical treatment should be reserved for the cases in which clinical improvement does not occur within 2 weeks.

References

1. David WJ, Richard HF. Chylothorax. *Chest Surg*

- Clin N Am 1994; 4: 617-28.
2. Valentine VG, Raffin TA. The management of chylothorax. Chest 1992; 102: 586-91.
 3. Staats BA, Ellefson RD, Budahn LL, Dines DE, Prakash UB, Offord K. The lipoprotein profile of chylous and nonchylous pleural effusions. Mayo Clin Proc 1980; 55: 700-4.
 4. Thurer RJ. Chylothorax: a complication of subclavian vein catheterization and parenteral hyperalimentation. J Thorac Cardiovasc Surg 1976; 71: 465-8.
 5. Ruggiero RP, Caruso G. Chylothorax - a complication of subclavian vein catheterization. JPEN J Parenter Enteral Nutr 1985; 9: 750-3.
 6. Schiller G. Chylothorax as a complication of central venous catheter-induced superior vena cava thrombosis. Bone Marrow Transplant 1992; 9: 302.
 7. Hinckley ME. Thoracic-duct thrombosis with fatal chylothorax caused by a long venous catheter. N Engl J Med 1969; 280: 95-6.
 8. Selle JG, Snyder WH, III, Schreiber JT. Chylothorax: indications for surgery. Ann Surg 1973; 177: 245-9.
 9. Ferguson MK, Little AG, Skinner DB. Current concepts in the management of postoperative chylothorax. Ann Thorac Surg 1985; 40: 542-5.
 10. Paes ML, Powell H. Chylothorax: an update. Br J Hosp Med 1994; 51: 482-90.
 11. Ramos W, Faintuch J. Nutritional management of thoracic duct fistulas. A comparative study of parenteral versus enteral nutrition. JPEN J Parenter Enteral Nutr 1986; 10: 519-21.
 12. Kurtz TW, Hsu CH. Resolution of chylothorax after positive end-expiratory pressure ventilation. Arch Surg 1980; 115: 73-4.
 13. Marts BC, Naunheim KS, Fiore AC, Pennington DG. Conservative versus surgical management of chylothorax. Am J Surg 1992; 164: 532-4.
 14. Little AG, Kadowaki MH, Ferguson MK, Staszek VM, Skinner DB. Pleuro-peritoneal shunting. Alternative therapy for pleural effusions. Ann Surg 1988; 208: 443-50.

ภาวะท่อน้ำเหลืองรั่วในผู้ป่วยบาดเจ็บไขสันหลังรุนแรง: รายงานผู้ป่วย และบททบทวนความรู้

พรพรหม เมืองแมน, เจฟฟรีย์ สกอตต์, สายพิณ เมืองแมน, รัชณี เบญจฉนัง, สุภาพรรณ สุวรรณโชติ

ภาวะท่อน้ำเหลืองรั่วนั้นเป็นภาวะที่ก่อให้เกิดภัยคุกคามเป็นอันตรายถึงชีวิตได้จากน้ำเหลืองที่รั่วเข้าไปมากจนเกิดภาวะน้ำท่วมปอด สาเหตุของภาวะนี้อาจเกิดจากการบาดเจ็บต่อท่อน้ำเหลืองในทรวงอก (ภายหลังผ่าตัดหรือ จากการบาดเจ็บต่อท่อน้ำเหลืองโดยตรง), ภาวะพิการที่เป็นมาแต่กำเนิดของท่อน้ำเหลือง หรือ ภาวะที่ไม่ได้เกิดจากสาเหตุอุบัติเหตุ ผู้ป่วยรายนี้เกิดภาวะท่อน้ำเหลืองรั่วในบริเวณช่องอกซึ่งเกิดขึ้นสองวันหลังจากใส่สายสวนผ่านทางหลอดเลือดดำอินเทอร์นัลจูกลาร์ ภาวะแทรกซ้อนนี้สามารถรักษาได้สำเร็จด้วยการใส่ท่อระบายทรวงอกและการให้สารอาหารที่มีไขมันต่ำ คาร์โบไฮเดรต และโปรตีนสูง นอกจากนี้แล้ว เราได้รวบรวมค้นคว้าถึงสาเหตุพยาธิสภาพ ลักษณะอาการทางคลินิกและวิธีการรักษาภาวะท่อน้ำเหลืองบาดเจ็บในช่องทรวงอกจนเกิดมีน้ำเหลืองรั่วเข้าไปในช่องปอดภายหลังการใส่สายสวนเข้าทางหลอดเลือดดำ
