

# Estimation of the Proper Length of Nasotracheal Intubation by Chula Formula

Anchalee Techanivate MD\*, Kunya Kumwilaisak MD\*,  
Wipra Worasawate MD\*, Ampawan Tanyong MD\*

\* Department of Anesthesiology, Faculty of Medicine, Chulalongkorn University, Bangkok

**Objectives:** To assess whether Chula formula can predict the proper length of nasotracheal intubation.

**Material and Method:** This was a prospective study of 100 patients (50 males and 50 females) who underwent general anesthesia with nasotracheal intubation (number 8.0 for male and 7.0 for female) between December 2005 and March 2007. The Chula formula was used to calculate the length of endotracheal tube (ETT) at the right external naris =  $9 + (\text{body height}/10)$  cm. After intubation, a fiberoptic bronchoscope was inserted into the ETT to measure the distance from the tip of ETT to the carina and the distance from the upper border of the cuff of ETT to the vocal cords.

**Results:** The mean length of nasotracheal tube at the right external naris calculated by Chula formula was 25.4 cm in males and 24.4 cm in females. The mean distance from the tip of ETT to the carina was 3.9 cm in males and 3.1 cm in females. The mean distance from the upper border of the cuff of ETT to the vocal cords was 2.6 cm in males and 3.0 cm in females. Ninety-three patients with upper border of the cuff of ETT had it placed at least 2 cm below the vocal cords, and in seven patients, the distance from the tip of ETT to the carina was found to be 1 to 1.9 cm. In every patient, it was found that the tip of ETT was placed at least 2 cm cephalad to the carina.

**Conclusion:** In the present study, the Chula formula could be used to predict the proper length of nasotracheal intubation in 93 of 100 patients.

**Keywords:** Length, Nasotracheal intubation, Chula formula

*J Med Assoc Thai* 2008; 91 (2): 173-80

**Full text. e-Journal:** <http://www.medassocthai.org/journal>

Nasotracheal intubation has several advantages. Nasal tube is thought to be better tolerated than oral tube. Nasotracheal intubation could be used as "first line" treatment in patients with an anticipated intermediate to long intubation duration such as patients with asthma, COPD exacerbation, drug overdose, CVA, congestive heart failure, trauma, or other critical care medicine. Nasotracheal intubation is required in general anesthesia for the patient undergoing operation of lips, mouth, intraoral surgery, and for patients with temporomandibular joint ankylosis. The blind intubation is also preferable with the nasal route.

A malpositioned endotracheal tube (ETT) is potentially a hazard for an intubated patient. Insertion of an excessively long ETT may lead to right endobronchial intubation, which is associated with left-sided atelectasis and right-sided tension pneumothorax<sup>(1-3)</sup>. On the contrary; insertion of an ETT that is too short may lead to accidental extubation, vocal cords trauma and laryngeal paralysis as a result of pressure injury by the cuff of ETT<sup>(4)</sup>.

Conrardy et al<sup>(5)</sup> demonstrated that flexion and extension of the neck might result in a mean movement of 1.9 cm of the tip of ETT toward and away from the carina. Therefore, the proper position of ETT has been determined where the tip of ETT should be located at the midpoint of the trachea, and it should be placed at least 2 cm cephalad to the carina to reduce the risk of mainstem bronchial intubation with the patient's head movement; and the proximal end of the cuff of ETT

Correspondence to : Techanivate A, Department of Anesthesiology, Chulalongkorn Memorial Hospital, Rama 4 Rd, Patumwan, Bangkok 10330, Thailand. Phone: 0-2256-4215, 0-2256-4295, 0-2252-1699, Fax: 0-2256-4294, Mobile phone: 081-840-0283

should be placed at least 2 cm below the vocal cords to reduce any impingement on the vocal cords when the patient moves his/her neck.

Several formulas and other methods have been proposed to estimate the optimal ETT length for tracheal intubation<sup>(7-13,16,17)</sup>. The authors' preliminary study<sup>(6)</sup> (Abstract, the Journal of the Medical Association of Thailand 2005, 88; 775-81) found that there were correlations between the length of 2 cm above the carina to the right external naris and the body height of the patient. The relation is formed into a formula named "Chula formula":

$$\text{Length of nasotracheal tube} = 9 + \text{Height}/10 \text{ cm}$$

The aim of the present study was to access whether the Chula formula could be used to predict the optimal length of ETT for nasotracheal intubation.

### Material and Method

The protocol of this prospective study was approved by the Ethics Committee of King Chulalongkorn Memorial Hospital and written informed consent was obtained from each recruited subject.

One hundred Thai patients, 50 males and 50 females, who required nasotracheal intubation for general anesthesia were recruited into the present study. All patients were above 20 yr, ASA physical status I and II. The patients who had nasal or nasopharyngeal obstruction, blood-clotting abnormality, severe facial or head trauma, which was a risk for cranial entry of the nasotracheal tube through a disrupted cribriform plate, were excluded from the present study.

Before the present study, the length of nasal ETT (Portex Profile Cuff, Portex Ltd, Hythe, Kent, UK) was calculated by Chula formula (9 + body height/10) and marked on the side of the ETT. With the patient's head rested on a standard pillow, general anesthesia was induced and muscle relaxation was given. The ETT number 8.0 for males or 7.0 for females was nasally intubated by an anesthesiologist. They placed the mark (that was calculated by Chula formula) on the side of the ETT that lay at the right external naris of the patient. Capnography was used to document the placement of the ETT within the trachea.

After five minutes of ventilation with 2% isoflurane in 100% oxygen 6 L/min, the ventilator tubing was disconnected from the ETT and a fiberoptic bronchoscope (Olympus) was passed through the ETT. When the bronchoscope tip was positioned at the carina, the tip of ETT and the vocal cords (the laryngoscope was used to identify the light of bronchoscope

at the vocal cords), the consensus about the best positions were discussed between the two anesthesiologists, and the sequential mark with tapes were performed around the bronchoscope where it entered the connector of ETT as mark 1, mark 2 and mark 3 (Fig. 1A, 1B and 1C; respectively).

The bronchoscope was then removed, and ventilation recommenced. Then the authors used a ruler to measure the distance in centimeters. Three distances were measured and calculated (Fig. 2):

1. The distance from the tip of ETT to the carina (mark 1- mark 2).
2. The distance from the vocal cords to the carina or tracheal length (mark 1- mark 3).
3. The distance from the upper border of the cuff of ETT to the vocal cords (mark 2- mark 3 - 6.5 for ETT number 8.0 and mark 2 - mark 3 - 6 for ETT number 7.0, Fig. 3A and 3B; respectively).

The ideal proper position of the ETT was indicated when the distance from tip of ETT to the carina and the distance from the upper border of the cuff of ETT to the vocal cords were found to be at least 2 cm. If the ETT was not found in the proper position, the ETT should then be adjusted.

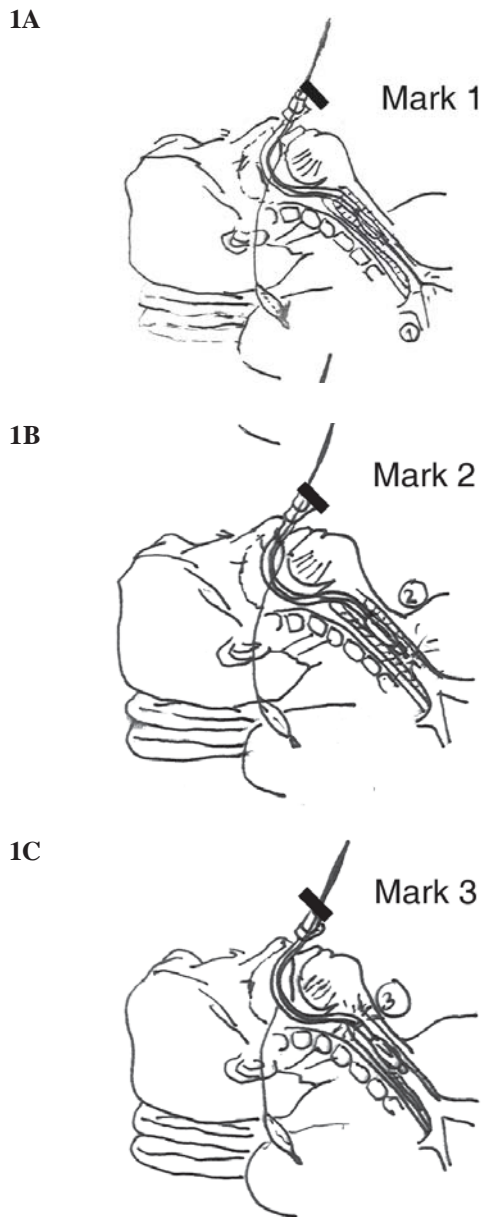
Sample size was determined by equation 1. As for the calculation of the sample size, the authors estimated 40% incidence of ETT malposition, based on reported rates of 11-43% from previous studies<sup>(6-10)</sup>. Regarding significance level was 0.05 (95% confidence interval (CI),  $Z_{\alpha/2} = 1.96$ ), successful intubation rate was 40% ( $p = 0.4$ ,  $q = 0.6$ ) and acceptable error of estimation was 0.10; then the sample size estimated that a minimum of 100 subjects would be needed.

$$\begin{aligned} \text{Equation 1} \quad n &= \frac{(Z_{\alpha/2})^2(p)(q)}{\Delta^2} \\ &= \frac{(1.96)^2(0.4)(0.6)}{(0.10)^2} = 92.19 \end{aligned}$$

All statistical analysis was performed with SPSS version 11.0. The data was presented by mean  $\pm$  SD, number of patients and percent.

### Results

The demographic data of the subjects, 50 males and 50 females, are exhibited in Table 1. The mean length of nasal ETT that was calculated from the Chula formula was  $25.4 \pm 0.8$  cm in males and  $24.4 \pm 0.5$  cm in females (Table 2). The minimum length of nasal ETT was 23.0 cm and the maximum length of nasal ETT was 27.0 cm (Fig. 4).

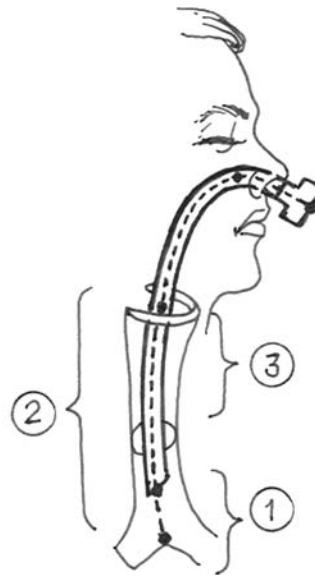


**Fig. 1** The three marks of tapes were performed around the bronchoscope where it entered the connector of ETT

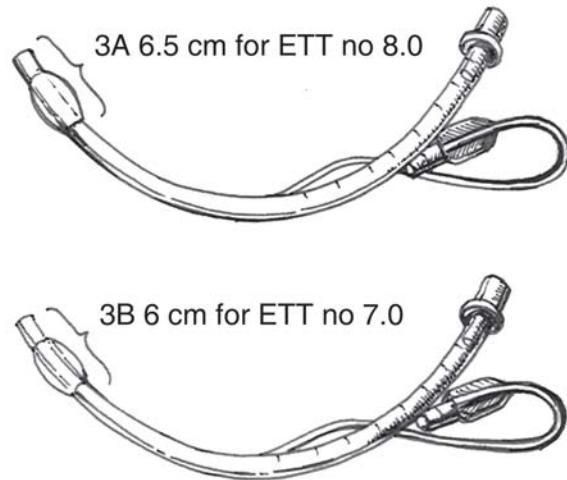
1A: When the bronchoscope tip was positioned at the carina, tapes around the bronchoscope tube were performed as mark 1

1B: When the bronchoscope tip was positioned at the tip of ETT, tapes around the bronchoscope tube were performed as mark 2

1C: When the bronchoscope tip was positioned at the vocal cords, tapes around the bronchoscope tube were performed as mark 3  
(ETT = endotracheal tube)



**Fig. 2** Three distances were measured and calculated:  
1 = The distance from the tip of ETT to the carina  
2 = The distance from the vocal cords to the carina or tracheal length  
3 = The distance from the upper border of the cuff of ETT to the vocal cords  
(ETT = endotracheal tube)



**Fig. 3** The distance from the upper border of the cuff to the tip of Portex Profile Cuff ETT (Portex Ltd, Hythe, Kent, UK):

3A: 6.5 cm for ETT number 8.0

3B: 6 cm for ETT number 7.0

(ETT = endotracheal tube)

**Table 1.** Demographic data and length of nasal ETT calculated from the Chula formula

	Male	Female
Age (yr)	54.9 ± 13.4 (22-82)	50.6 ± 13.8 (26-78)
Weight (kg)	61.1 ± 9.8 (43-83)	55.3 ± 10.7 (39-92)
Height (cm)	164.5 ± 8.2 (145-180)	154.5 ± 5.6 (140-170)
Length of nasal ETT that calculated from Chula formula (cm)	25.4 ± 0.8 (23.5-27)	24.4±0.5 (23-26)

Value present mean ± SD (minimum-maximum)

ETT = endotracheal tube

**Table 2.** Three measured and calculated distances

	Male (n = 50)	Female (n = 50)
The distance from the tip of ETT to the carina (cm)	3.9 ± 0.9 (2.4-6.2)	3.1 ± 0.8 (2-6)
Tracheal length (cm)	13.0 ± 1.0 (11-16.2)	12.2 ± 1.4 (10-16)
The distance from the upper border of the cuff of ETT to the vocal cords (cm)	2.6 ± 0.5 (1.5-4)	3.0 ± 1.2 (1-8)

Value present mean ± SD (minimum-maximum)

ETT = endotracheal tube

The distance from the tip of ETT to the carina was  $3.9 \pm 0.9$  cm in males and  $3.1 \pm 0.8$  cm in females; the minimum distance was 2 cm; the maximum distance was 6.2 cm. None had the distance from the tip of ETT to the carina less than 2 cm (Fig. 5). The tracheal length was  $13.0 \pm 1.0$  cm in males and  $12.2 \pm 1.4$  cm in females. The shortest trachea was 10.0 cm in females. The distance from the upper border of the cuff of ETT to the vocal cords was  $2.6 \pm 0.5$  cm in males and  $3.0 \pm 1.2$  cm in females; the minimum distance was 1 cm; the maximum distance was 7.2 cm. There were 7 patients that the distance from the upper border of the cuff of ETT to the vocal cords was less than 2 cm; 1 cm in one female, 1.5 cm in each sex, 1.6 cm in each sex, 1.8 cm in one female, and 1.9 cm in one female (Fig. 6).

The proper length of nasotracheal intubation was defined that the tip of ETT should be placed at least two cm cephalad to the carina and the upper border of the cuff of ETT should be placed at least two cm below the vocal cords. Therefore, the rate of success for placing ETT to its proper length was 93% (93 from 100 patients) according to the Chula formula. There were two male and four female patients whose ETT cuffs were too close to their vocal cords.

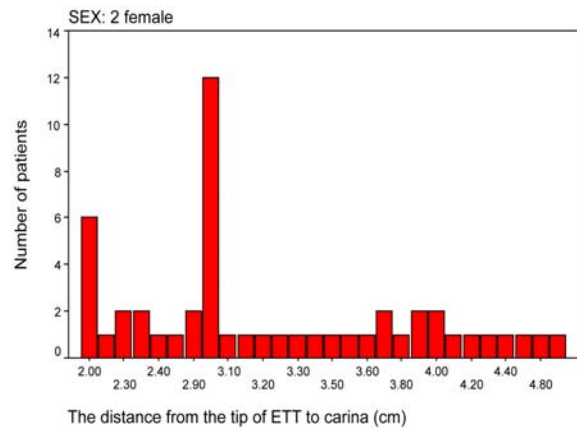
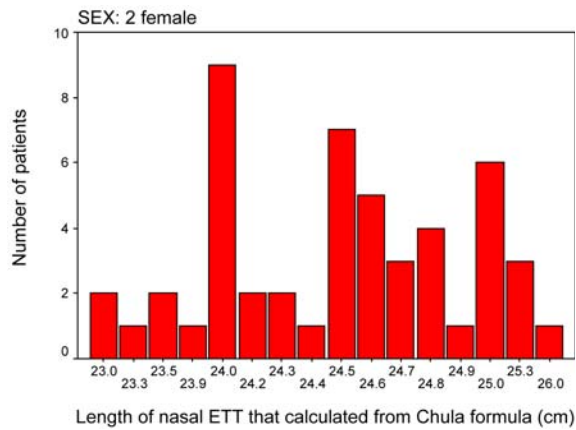
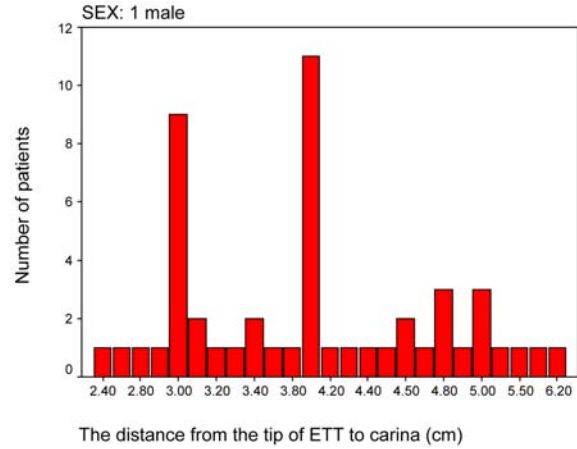
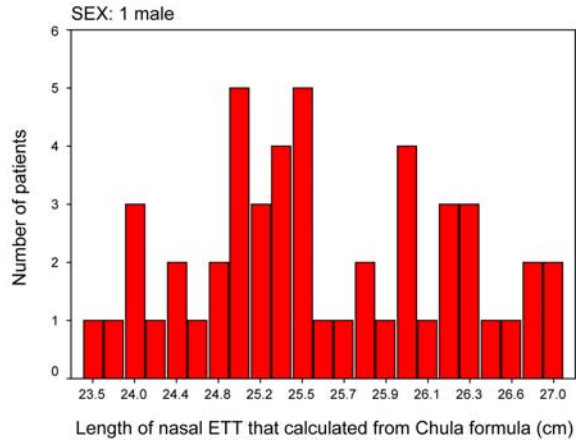
## Discussion

According to the ASA Closed Claim Project, the combination of inadvertent extubation and mainstem

intubation accounts for 2% of adverse respiratory events in adult patients<sup>(14)</sup>. Unrecognized mainstem intubation can lead to hypoxemia, so it is emphasized that an ETT must always be confirmed in the proper position<sup>(15)</sup>.

In 1976, Conrardy et al reported an average length of 3.8 cm movement of ETT toward the carina when the patient's head was moved from full extension to full flexion (in some patients this movement reached as far as 6.4 cm). This resulted in an average movement of ETT of about 1.9 cm when the head is moved from its neutral position to full extension. It is unlikely that extubation would occur if the tip of ETT is placed at the middle of the trachea or at least 2 cm above the carina<sup>(5)</sup>.

In the present study, no endobronchial intubation or impingement of the ETT cuff on the vocal cords was found. The average distances from the tip of ETT to the carina were 3.9 cm in males and 3.1 cm in females. The average distances from the vocal cords to the upper border of ETT cuff were 2.6 cm in males and 3 cm in females. The authors found that there were 7 patients (2 males and 5 females) whose distances from the vocal cords to the upper border of ETT cuff were less than 2 cm (1 cm for 1 patient, 1.5 cm for 2 patients, 1.6 cm for 2 patients, 1.8 cm for 1 patient, and 1.9 cm for 1 patient). This finding suggested that the Chula formula is accurate about 93% in estimation of the



**Fig. 4** The frequency (n) of the length of nasal ETT that calculated from the Chula formula (cm) in males and females (ETT = endotracheal tube)

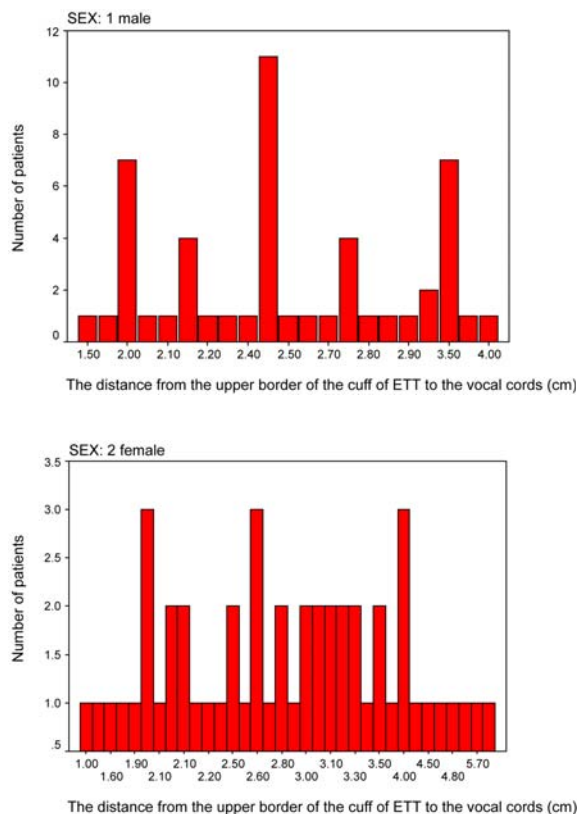
**Fig. 5** The frequency (n) of the distance from the tip of ETT to carina (cm) in males and females (ETT = endotracheal tube)

proper position for nasotracheal intubation, similar to a reference from Conrardy et al. In the 7 cases whose cuff of ETT was just below the vocal cords (1-1.9 cm), the medical physician should be aware or prohibit the extending patient's head that the ETT cuff would positioned more distally and a sump would be opened up between the vocal cords. Therefore, the event might allow either inadvertent laryngeal extubation or vocal cord injury.

There is a variety of techniques suggested to confirm the proper placement of the ETT. Subhash et al described the cuff palpitation at the suprasternal notch to confirm that the tip of ETT is not in the mainstem bronchus; however, this may occur with an inadvertent esophageal intubation<sup>(7,8)</sup>. Ford et al described a technique of passing ETT so that its cuff advanced 2 cm

beyond the vocal cords, but this maneuver should be attempted when the intubation is performed under direct laryngoscope<sup>(9)</sup>. Brunel et al reported that 60% of mainstem bronchial intubations occurred despite the presence of equal breath sounds from the bilateral chest<sup>(10)</sup>. Schwartz et al verified the proper position with an auscultation of bilateral breath sounds, symmetrical chest expansion and palpitation of the cuff at the suprasternal notch; however, in 15.5% of the cases according to radiological assessment ETT malposition was found with a higher incidence in females than males<sup>(11)</sup>. Eagle had determined the height (cm)/10 + 8 formula as a distance from nose to midpoint of trachea but this formula has no foolproof in the clinical setting<sup>(12)</sup>. Kazuna *et al* suggested that the fiberoptic bronchoscope is more reliable than chest auscultation





**Fig. 6** The frequency (n) of the distance from the upper border of the cuff of ETT to the vocal cords (cm) in males and females (ETT = endotracheal tube)

to confirm the position of ETT but it is not routinely performed<sup>(13)</sup>.

In the conventional method, a nasotracheal tube should be advanced until the cuff is 2 cm below the vocal cords<sup>(16)</sup> or until the external markings are 24 cm for females and 26 cm for males (3 cm more than oral tube) at the nares<sup>(17)</sup>.

The proper placement of ETT does not only depend on its tip and its upper border should be at least 2 cm away from the carina and the vocal cords, but also on the relationship between the tracheal length and the distance from the upper border of the cuff to the tip of ETT (approximately 6-6.5 cm in Portex ETT, Fig. 3). The tracheal length must be approximately 4 cm longer than the distance, so that laryngeal trauma and mainstem bronchial intubation will not occur. A patient who has a short trachea but was chosen to have a longer distance from the upper border of the cuff to the tip of ETT, the cuff of ETT may impinge on the vocal cords if the anesthesiologist intends to place the tip of

ETT above the carina at least 2 cm. On the other hand, if the anesthesiologist intends to place the cuff of ETT at least 2 cm below the vocal cords, the tip of ETT could be close to the carina. For example, in a patient whose tracheal length is about 11 cm, the distance from the upper border of the cuff to the tip of ETT must be shorter than 7 cm. In fact, the distance from the upper border of the cuff to the tip of ETT varies between 5.3-7.0 cm, according to the size, model and the brand of ETT<sup>(18)</sup> (for example, the distance from the upper border of the cuff to the tip of Portex Profile Cuff, Portex Ltd, Hythe, Kent, UK ETT number 7.0-8.0 is approximately 6-6.5 cm; Fig. 3).

From the authors' previous study of measurement the airway distances with fiberoptic bronchoscope in Thai patients, it was found that there were correlations between the distance from the right external naris to the carina and the body height (Pearson correlation 0.654;  $p < 0.01$ ). Furthermore, the authors got a formula of linear regression that was calculated by subtracting two cm from the distance from the right external naris to the carina, hence, the authors named it "*Chula formula*". The authors also suggested that the patients who were short and had short trachea should be intubated by a shorter distance from the upper border of the cuff to the tip of the ETT, which decreases the risk of vocal cords injury when they extended their heads.

One limitation of the Chula formula was that the patients who do not know their height, the proper length of the ETT cannot be calculated.

The present formula can be applied in the operating room, intensive care unit and emergency room. In difficult airway intubation patient such as in patients whose laryngoscopic view is class 3 or 4, in patient who cannot be used for direct intubation and those who need a light wand for intubation, the authors cannot identify the vocal cords to pass down the ETT. Therefore, the cuff may be advanced 2-3 cm beyond the vocal cords in routine practice<sup>(16)</sup>. The authors can use the Chula formula to calculate the proper length of ETT in nasotracheal intubation.

### Conclusion

The Chula formula is useful to determine the optimal position of ETT in most patients who require nasotracheal intubation. The success rate of proper positioned of ETT is achieved when the tip of ETT was above the carina at least 2 cm and the upper border of ETT was at least 2 cm below the vocal cords, which was about 93% in the present study.

### Acknowledgement

The present study was supported by Rachadapiseksompoj Fund of Chulalongkorn University, Bangkok, Thailand.

### References

1. Blanc VF, Tremblay NA. The complications of tracheal intubation: a new classification with a review of the literature. *Anesth Analg* 1974; 53: 202-13.
2. Zwillich CW, Pierson DJ, Creagh CE, Sutton FD, Schatz E, Petty TL. Complications of assisted ventilation. A prospective study of 354 consecutive episodes. *Am J Med* 1974; 57: 161-70.
3. Breivik H, Grenvik A, Millen E, Safar P. Normalizing low arterial CO<sub>2</sub> tension during mechanical ventilation. *Chest* 1973; 63: 523-31.
4. Cavo JW Jr. True vocal cord paralysis following intubation. *Laryngoscope* 1985; 95: 1352-9.
5. Conrardy PA, Goodman LR, Lainge F, Singer MM. Alteration of endotracheal tube position. *Crit Care Med* 1976; 4: 8-12.
6. Techanivate A, Rodanant O, Charoenraj P, Kumwilaisak K. Depth of endotracheal tubes in Thai adult patients. *J Med Assoc Thai* 2005; 88: 775-81.
7. Chander S, Feldman E. Correct placement of endo-tracheal tubes. *N Y State J Med* 1979; 79: 1843-4.
8. Stirt JA. Endotracheal tube misplacement. *Anaesth Intensive Care* 1982; 10: 274-6.
9. Ford RW. Confirming tracheal intubation - a simple manoeuvre. *Can Anaesth Soc J* 1983; 30: 191-3.
10. Brunel W, Coleman DL, Schwartz DE, Peper E, Cohen NH. Assessment of routine chest roentgenograms and the physical examination to confirm endotracheal tube position. *Chest* 1989; 96: 1043-5.
11. Schwartz DE, Lieberman JA, Cohen NH. Women are at greater risk than men for malpositioning of the endotracheal tube after emergent intubation. *Crit Care Med* 1994; 22: 1127-31.
12. Eagle CC. The relationship between a person's height and appropriate endotracheal tube length. *Anaesth Intensive Care* 1992; 20: 156-60.
13. Sugiyama K, Yokoyama K. Reliability of auscultation of bilateral breath sounds in confirming endotracheal tube position. *Anesthesiology* 1995; 83: 1373.
14. Caplan RA, Posner KL, Ward RJ, Cheney FW. Adverse respiratory events in anesthesia: a closed claims analysis. *Anesthesiology* 1990; 72: 828-33.
15. Schwartz DE, Lieberman JA, Cohen NH. Women are at greater risk than men for malpositioning of the endotracheal tube after emergent intubation. *Crit Care Med* 1994; 22: 1127-31.
16. Clinton JE, Rutz E. Respiratory procedures. In: Robert JR, Nedges JR, editors. *Clinical procedures in emergency medicine*. 2<sup>nd</sup> ed. Philadelphia: WB Saunders; 1991: 8-18.
17. Benumof JL. Conventional (laryngoscopic) orotracheal and nasotracheal intubation (single lumen tube). In: Benumof JL, editor. *Airway management: principle and practice*. St. Louis: Mosby Yearbook; 1996: 261-76.
18. Chong DY, Greenland KB, Tan ST, Irwin MG, Hung CT. The clinical implication of the vocal cords-carina distance in anaesthetized Chinese adults during orotracheal intubation. *Br J Anaesth* 2006; 97: 489-95.

---

## ความลึกในการใส่ท่อหายใจทางจมูกที่เหมาะสมโดยใช้ส้อมตรวจ

อัญชลี เตชะนิเวศน์, กัญญา คำวิไลศักดิ์, วิปรา วรเศวต, อัมพวัน ตันหยง

**วัตถุประสงค์:** เพื่อทดสอบส้อมตรวจว่าสามารถนำมาใช้ในการคาดคะเนความลึกที่เหมาะสมของการใส่ท่อหายใจทางจมูกในคนไทยได้

**วัสดุและวิธีการ:** ทำการศึกษาในผู้ป่วย 100 คน (ชาย 50 คน และ หญิง 50 คน) ที่มารับบริการระดับความรู้สึกที่ต้องใส่ท่อหายใจทางจมูก (ขนาด 8.0 สำหรับชาย และ 7.0 สำหรับหญิง) โดยใช้ส้อมตรวจ คำนวณหาความลึกของท่อหายใจระหว่าง ธันวาคม พ.ศ. 2548 – มีนาคม พ.ศ. 2550 และทุกคน จะถูกใส่ให้ความลึกเท่ากับที่คำนวณไว้ที่ตำแหน่งรูจมูกขวา ความลึกของท่อหายใจทางจมูก =  $9 + (\text{ความสูง (ซม.)} / 10)$  ซม. หลังการใส่ท่อหายใจ ใช้ fiberoptic bronchoscope ใส่เข้าไปในท่อหายใจ เพื่อวัดระยะทางจากปลายท่อหายใจ ถึง carina และระยะจากสายเสียงถึงขอบบนสุดของ cuff ของท่อหายใจ และระยะทั้งสองต้องไม่ต่ำกว่า 2 ซม. จึงถือว่า ท่อหายใจมีความลึกที่เหมาะสม

**ผลการศึกษา:** ความลึกเฉลี่ยที่คำนวณจากส้อมตรวจเท่ากับ 25.4 ซม. ในผู้ป่วยชาย และ 24.4 ซม. ในผู้ป่วยหญิง ระยะทางเฉลี่ยจากปลายของท่อหายใจถึง carina เท่ากับ 3.9 ซม. ในผู้ป่วยชาย และ 3.1 ซม. ในผู้ป่วยหญิง ระยะทางเฉลี่ยจากสายเสียงถึงขอบบนของ cuff ของท่อหายใจเท่ากับ 2.6 ซม. ในผู้ป่วยชาย และ 3.0 ซม. ในผู้ป่วยหญิง ผู้ป่วยจำนวนทั้งหมด 93 รายที่พบว่าขอบบนสุดของ cuff ของท่อหายใจอยู่ในตำแหน่งอย่างน้อยที่สุด 2 ซม. ต่ำกว่าสายเสียง โดยมีผู้ป่วย 7 ราย เป็นชาย 2 ราย และหญิง 5 ราย ที่พบว่าขอบบนสุดของ cuff ของท่อหายใจอยู่ต่ำกว่าสายเสียงเท่ากับ 1; 1.5; 1.6; 1.8 และ 1.9 ซม. จำนวน 1; 2; 2; 1 และ 1 รายตามลำดับ และผู้ป่วยทุกรายพบว่า ปลายท่อหายใจอยู่เหนือ carina อย่างน้อย 2 ซม.

**สรุป:** ในการศึกษาครั้งนี้พบว่าส้อมตรวจสามารถใช้ในการใส่ท่อหายใจทางจมูกในคนไทยให้มีความลึกที่เหมาะสมได้สำเร็จร้อยละ 93

---