

Preliminary Report

Reducing Postoperative Seroma by Closing of Axillary Space

Vit Benjasirichai MD*, Akanist Piyapant MD*,
Chairat Pokawattana MD*, Jirapong Dowreang MD**

* Department of Surgery, Rajavithi Hospital, Bangkok
** Department of Radiology, Rajavithi Hospital, Bangkok

Background: Seroma is a common complication after mastectomy. Most postoperative seroma occur at the axilla. Many previous studies had tried to reduce seroma formation after mastectomy by multimodalities. Closing the dead space gave a good result for many previous retrospective studies but limited number of randomized control study.

Objective: To reduce postoperative seroma by closing the axillary space as a randomized control study and to evaluate the incidence of seroma formation at the axilla as a prospective randomized control trial in axillary space closure by suturing a skin flap to the underlying chest wall after MRM.

Material and Method: Total consecutive 16 patients who were diagnosed with breast cancer at Rajavithi Hospital by pathologic examination from May 2005 to May 2006 and signed informed consent was obtained in the present study. All patients were randomized after mastectomy before wound closure into the control group or study group. In the control group, the wound was closed conventionally. In the study group, axillary space was closed by suturing the skin flap to the underlying muscle, 3 points at mid axillary line. Patients' characteristics and operative related factors were recorded and compared between the two groups. All patients received ultrasonographic examination at axilla two weeks after discharge.

Results: There were eight patients in the control group and eight patients in the study group. The patients' characteristic and tumor characteristics were recorded and compared. There was no statistical significance of BMI, tumor size, and hormonal status between the two groups. In the study group, the patient's age was significantly higher. There was no statistical significance of seroma thickness at the axilla between control group and study group (1.77 ± 1.00 vs. 1.00 ± 0.22 , $p = 0.067$).

Conclusion: There was no statistically significant difference of seroma thickness at the axilla between the two groups. Further study with a larger sample size is required.

Keywords: Closing of axillary space, Seroma, Mastectomy

J Med Assoc Thai 2007; 90 (11): 2321-5

Full text. e-Journal: <http://www.medassocthai.org/journal>

Seroma is the common postoperative complication after mastectomy, and can occur in 35-60% of patients undergoing mastectomy and axillary lymph node dissection⁽¹⁻⁴⁾ and is also associated with an increased incidence of lymph edema, flap necrosis, wound break down and arm lymph edema^(2,5,6). Axilla is the most common site of postoperative seroma. It was found in one study that age was a very important

etiologic factor, the frequency of seroma formation increased with age⁽⁷⁾ and a significant positive relationship between BMI and seroma production⁽⁸⁾.

Many modalities from previous studies such as pressure garment⁽⁹⁻¹¹⁾, fibrin glue⁽¹²⁾, ultrasound scissors⁽¹³⁾ were used but the result was not satisfactory. Closing of the dead space after mastectomy had a good result from previous retrospective studies⁽¹⁴⁻¹⁶⁾ but a limited number of randomized control studies. The present study tried to reduce postoperative seroma by closing the axillary space as a randomized control trial.

Correspondence to : Benjasirichai V, Department of Surgery, Rajavithi Hospital, Bangkok 10400, Thailand

Objective

To evaluate the incidence of seroma formation at axilla as a prospective randomized control trial in axillary space closure by suturing the skin flap to the underlying chest wall after modified radical mastectomy.

Material and Method

From May 2005 to May 2006, 16 consecutive patients who were diagnosed with breast cancer by pathologic examination at Rajavithi Hospital with informed consents, undergoing modified radical mastectomy (MRM) were included in the present study. All patients were received the information before signing informed consents. There were five surgeons in the present study.

After MRM, each patient was randomized into the control group or study group by random number.

Research design

A prospective randomized control trial.

Inclusion criteria

All patients who were diagnosed as breast cancer at Rajvithi Hospital and underwent MRM, that had complete medical data and signed and an informed consents.

Exclusion criteria

Patients who refused to enter the present study and patients who were lost to follow up.

Sample size

From the study of Eamon C, Coveney EC, O'Dwyer PJ, Geraghty JG, O'Higgins NJ. Effect of closing dead space on seroma formation after mastectomy-a prospective randomized clinical trial⁽¹⁹⁾.

To evaluate the effect of closing the dead space on seroma formation after mastectomy, 39 patients undergoing 40 mastectomies with axillary node clearance were randomized to undergo suturing of skin flaps to underlying muscle or conventional skin closure. Fewer patients in the flap sutured group developed seromas, 5 (25%) vs. 17 (85%). $X^2 = 12.2$ $p < 0.001$, $Z\alpha$ ($\alpha = 0.05$) = 1.96, $Z\beta$ ($\beta = 0.1$) = 1.28, Power = $1 - \beta$.

$$p1 = 0.25, p = 0.55, p2 = 0.85$$

$$n = \frac{[Z\alpha\sqrt{2p(1-p)} + Z\beta\sqrt{p1(1-p1) + p2(1-p2)}]^2}{(p1-p2)^2}$$

$$n = \frac{[1.96\sqrt{2(0.55)} + \sqrt{1.28(1-0.25) + 0.85(1-0.85)}]^2}{(0.25-0.85)^2}$$

$$n = 7.55 \rightarrow 8 \text{ patients/group}$$

Surgical technique

1) Control group: Conventional MRM with placing two closed suction drains at the mastectomy site and axillary fossa and conventional skin closure.

2) Study group: Conventional MRM with placing two closed suction drains at the mastectomy site and axillary fossa and suturing the skin flap to underlying muscle 3 points at mid axillary line by subcuticular technique (Fig. 1).

Suture material

Polyglacin (Vicryl) 3-0

Postoperative monitoring

The mastectomy site was inspected daily for wound complication. Daily volume of each closed suction drain was recorded. The drain was removed when the lymphatic content was less than 30 cc/day for each drain. The patient was then discharged the next day.

Postoperative seroma formation was detected by ultrasonography at 2 weeks after the patient was discharged by a single radiologist. The ultrasound probe was placed at the axilla when the patient lay in the supine position. The maximum thickness of the seroma at the axilla was recorded.

Wound complication was recorded during admission and the time of follow-up.

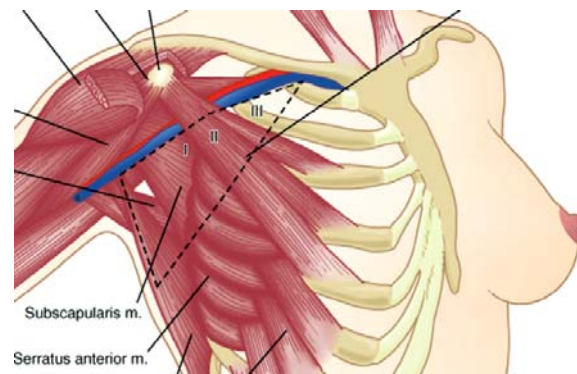


Fig. 1

Data collection

1. **Patients' characteristics:** Age, BMI

2. **Disease related factors:**

- Tumor size (cm)
- Hormonal status: ER, PR, HER2/neu (%)

3. **Operative related factors:**

- Operative time (minute)
- Closed suction drainage volume (cc/day)
- Presence of postoperative seroma
- Wound complication

Results

Eighteen patients were enrolled in the present study, eight patients in the study group and 10 patients in the control group. Patients and tumor characteristics are shown and compared.

There was no statistically significant difference of BMI, tumor size, baseline hematocrit and hormonal status between the two groups.

In the study group, the patient's age was significantly higher.

There was no statistically significant difference of operative time, drainage volume and seroma

thickness between the two groups.

No wound complication was found in both groups.

The operative related factors were show in Table 2.

Discussion

Suture skin flap to the under lying chest wall was first described by Halsted⁽¹⁷⁾. From previous retrospective studies^(14-16,19), suture skin flap to the underlying chest wall had a lower incidence of postoperative seroma but the surgical technique had to suture multiple points to obliterate the space that was more time consuming. Seroma frequency occur at axilla, In the present study the authors tried to close the axillary space by using of 3 points fixation suture as described above that were more rapid and easier to perform. By using ultrasonography, the detection of seroma was more accurate than the manual palpation performed by clinicians in previous studies.

In the present study, the postoperative seroma seems to be lower in study group but not statistically significantly different.

Table 1. Patient characteristics

Patients and tumor characteristics	Control group (n = 8)	Study group (n = 8)	p-value
Age (years)	47.75 ± 4.68	61.50 ± 12.75	0.019
BMI	21.71 ± 3.81	24.37 ± 4.30	0.211
Tumor size (cm)	2.76 ± 1.90	3.22 ± 1.95	0.639
Hormonal status			
• ER positive (%)	2 (25.0%)	3 (37.5%)	1.000
• PR positive (%)	3 (37.5%)	3 (37.5 %)	1.000
• HER2/neu Over expression	4 (50.0%)	5 (62.5 %)	1.000

Table 2. Operative related factors

Operative related factors details	Control group	Study group	p-value
Operative time (minutes)	164.38 ± 40.66	181.88 ± 48.25	0.446
• Median	172.50	180.00	
• Range	90-210	105-250	
Total drainage volume (cc)			
• Mean ± SD	657.5 ± 496.98	792.13 ± 461.22	0.583
• Median	555.00	653.50	
• Range	220-1760	480-1880	
Thickness of seroma at axilla (cm)			
• Mean ± SD	1.77 ± 1.00	1.00 ± 0.22	0.067
• Median	1.47	1.14	
• Range	0.5-3.0	0.7-1.45	

The authors tried to control the confounding factors in the present study but there were some limitations such as more than one surgeon in the present study, small sample size (rare complications may be found in the larger sample size and the result may be different from the present study), Timing of ultrasonography (some patients may develop seroma before or after two weeks) and volume of the breast that may effect the postoperative seroma because a large breast size will have more raw surface than a small breast, that will have more possibility of post-operative seroma.

Conclusion

There was no statistically significant difference of the thickness of the seroma at the axilla measured by ultrasonography between the two groups. Further study with a larger sample size is required.

References

- Budd DC, Cochran RC, Sturtz DL, Fouty WJ Jr. Surgical morbidity after mastectomy operations. *Am J Surg* 1978; 135: 218-20.
- Say CC, Donegan W. A biostatistical evaluation of complications from mastectomy. *Surg Gynecol Obstet* 1974; 138: 370-6.
- Tadych K, Donegan WL. Postmastectomy seromas and wound drainage. *Surg Gynecol Obstet* 1987; 165: 483-7.
- Hashemi E, Kaviani A, Najafi M, Ebrahimi M, Hooshmand H, Montazeri A. Seroma formation after surgery for breast cancer. *World J Surg Oncol* 2004; 2: 44.
- Aitken DR, Minton JP. Complications associated with mastectomy. *Surg Clin North Am* 1983; 63: 1331-52.
- Budd DC, Cochran RC, Sturtz DL, Fouty WJ Jr. Surgical morbidity after mastectomy operations. *Am J Surg* 1978; 135: 218-20.
- Menton M, Roemer VM. Seroma formation and drainage technic following mastectomy. *Fortschr Med* 1990; 108: 350-2.
- Bonnema J, van Geel AN, Ligtenstein DA, Schmitz PI, Wiggers T. A prospective randomized trial of high versus low vacuum drainage after axillary dissection for breast cancer. *Am J Surg* 1997; 173: 76-9.
- O'Hea BJ, Ho MN, Petrek JA. External compression dressing versus standard dressing after axillary lymphadenectomy. *Am J Surg* 1999; 177: 450-3.
- Chen CY, Hoe AL, Wong CY. The effect of a pressure garment on post-surgical drainage and seroma formation in breast cancer patients. *Singapore Med J* 1998; 39: 412-5.
- Lam CYW, Lim BH, Chiu PWY, Lee SW, Wu M, Chow TL, et al. Effects of pressure garment on patients undergoing modified radical mastectomy - a prospective randomized trial. *Ann Coll Surg Hong Kong* 2001; 5: A17.
- Gilly FN, Francois Y, Sayag-Beaujard AC, Glehen O, Brachet A, Vignal J. Prevention of lymphorrhea by means of fibrin glue after axillary lymphadenectomy in breast cancer: prospective randomized trial. *Eur Surg Res* 1998; 30: 439-43.
- Lumachi F, Brandes AA, Burelli P, Basso SM, Iacobone M, Ermani M. Seroma prevention following axillary dissection in patients with breast cancer by using ultrasound scissors: a prospective clinical study. *Eur J Surg Oncol* 2004; 30: 526-30.
- McCaul JA, Aslaam A, Spooner RJ, Loudon I, Cavanagh T, Purushotham AD. Aetiology of seroma formation in patients undergoing surgery for breast cancer. *Breast* 2000; 9: 144-8.
- Aitken DR, Hunsaker R, James AG. Prevention of seromas following mastectomy and axillary dissection. *Surg Gynecol Obstet* 1984; 158: 327-30.
- O'Dwyer PJ, O'Higgins NJ, James AG. Effect of closing dead space on incidence of seroma after mastectomy. *Surg Gynecol Obstet* 1991; 172: 55-6.
- Halsted WS. Developments in the skin-grafting operation for cancer of the breast. *JAMA* 1913; 60: 416-8.
- Petrek JA, Peters MM, Nori S, Knauer C, Kinne DW, Rogatko A. Axillary lymphadenectomy. A prospective, randomized trial of 13 factors influencing drainage, including early or delayed arm mobilization. *Arch Surg* 1990; 125: 378-82.
- Coveney EC, O'Dwyer PJ, Geraghty JG, O'Higgins NJ. Effect of closing dead space on seroma formation after mastectomy - a prospective randomized clinical trial. *Eur J Surg Oncol* 1993; 19: 143-6.
- Chilson TR, Chan FD, Lonser RR, Wu TM, Aitken DR. Seroma prevention after modified radical mastectomy. *Am Surg* 1992; 58: 750-4.

การลดการสะสมของน้ำเหลืองหลังการทำผ่าตัดเต้านมโดยการเย็บชั้นไขมันและผิวหนังติดกับผนังทรวงอก

วิช เบญจาศิริชัย, ชัยรัตน์ โกศาวัฒนา, อกนิษฐ์ ปิยะพันธุ์, จิรพงศ์ ดาวเรือง

วัตถุประสงค์: เพื่อศึกษาเปรียบเทียบการสะสมของน้ำเหลืองหลังการทำผ่าตัดเต้านม ระหว่างกลุ่มผู้ป่วยที่ได้รับการผ่าตัดเต้านมตามวิธีปกติและกลุ่มผู้ป่วยที่ได้รับการผ่าตัดเต้านมรวมกับการเย็บชั้นไขมันและผิวหนังติดกับผนังทรวงอกแบบ *prospective randomized control trial*

วัสดุและวิธีการ: ผู้ป่วยที่ได้รับการวินิจฉัยว่าเป็นมะเร็งเต้านมโดยการตรวจทางพยาธิวิทยาที่โรงพยาบาลราชวิถี ตั้งแต่เดือนพฤษภาคม พ.ศ. 2548 ถึง เดือนพฤษภาคม พ.ศ. 2549 ซึ่งได้รับการให้ข้อมูลเกี่ยวกับการวิจัยและเซ็นยินยอม เข้าร่วมโครงการวิจัยในกลุ่มควบคุมผู้ป่วยได้รับการผ่าตัดเต้านมและเย็บปิดแผลตามปกติ ในกลุ่มศึกษาหลังจากผ่าตัดเต้านมผู้ป่วยได้รับการเย็บชั้นผิวหนังและไขมันที่รักแร้จำนวน 3 จุดติดกับผนังทรวงอก ผู้ป่วยทุกคนได้รับการตรวจ *ultrasound* ที่รักแร้เพื่อดูการสะสมของน้ำเหลืองหลังจากผู้ป่วยออกจากโรงพยาบาลแล้ว 2 สัปดาห์โดยรังสีแพทย์

ผลการศึกษา: ผู้ป่วยมะเร็งเต้านมทั้งหมด 16 คนได้รับเข้าเป็นผู้ป่วยในโครงการวิจัยมีผู้ป่วยในกลุ่มศึกษา 8 คน และในกลุ่มควบคุม 8 คน พบว่าไม่มีความแตกต่างกันอย่างมีนัยสำคัญทางสถิติของ BMI, tumor size, hormonal status ระหว่าง 2 กลุ่ม อายุเฉลี่ยของผู้ป่วยในกลุ่มศึกษามากกว่าในกลุ่มควบคุม และพบว่าไม่มีความแตกต่างอย่างมีนัยสำคัญของความหนาของน้ำเหลืองที่สะสมที่รักแร้ระหว่าง 2 กลุ่ม (1.77 ± 1.00 vs. 1.00 ± 0.22 , $p = 0.067$)

สรุป: ไม่มีความแตกต่างทางสถิติอย่างมีนัยสำคัญของความหนาของน้ำเหลืองที่สะสมที่รักแร้ระหว่าง 2 กลุ่ม
