

Case Reports

Bisphosphonate-Related Osteonecrosis of the Jaws (ONJ): A Report of Two Cases

Chatlert Pongchaiyakul MD*, Krittinant Auraiwan DDS**,
Praew Kotruchin MD*, Churairat Kularbkaew MD***

* Department of Medicine, Srinagarind Hospital, Faculty of Medicine, Khon Kaen University, Khon Kaen

** Division of Oral Maxillofacial Surgery, Dental Department, Srinagarind Hospital, Faculty of Medicine, Khon Kaen University, Khon Kaen

*** Department of Pathology, Srinagarind Hospital, Faculty of Medicine, Khon Kaen University, Khon Kaen

Osteonecrosis of the jaw (ONJ) is strongly associated with the use of aminobisphosphonates. Herein, the authors report two cases of ONJ after intravenous bisphosphonate therapy including clinical presentations, X-ray, and pathological findings. Since there is no definite treatment for ONJ, the focus should be on prevention with a dental evaluation for all patients before starting bisphosphonates.

Keywords: Osteonecrosis of the jaw, Bisphosphonate, Thailand

J Med Assoc Thai 2007; 90 (11): 2494-8

Full text. e-Journal: <http://www.medassocthai.org/journal>

Osteonecrosis of the jaw (ONJ) is a newly recognized condition reported in patients treated with bisphosphonates (BPs), in particular the highly potent aminobisphosphonates. Most cases have developed in patients with multiple myeloma or metastatic cancer, but the condition has also been identified in patients with osteoporosis⁽¹⁻⁷⁾. The first reports of BP-ONJ associated with the use of zoledronic acid and pamidronate began in 2003^(3,8-10) and the majority of cases were linked with dental procedures such as tooth extraction. Less commonly, ONJ appeared to occur spontaneously in patients taking these drugs⁽¹⁾ and several cases of ONJ were associated with oral bisphosphonates (*i.e.*, alendronate, risedronate and ibandronate) for the treatment of osteoporosis^(2,4). It is not clear, however, if these patients had other conditions that would put them at risk for developing ONJ.

To the authors' knowledge, bisphosphonate-related ONJ has never before been reported in Thai patients. In this report, the authors present two cases of ONJ induced by bisphosphonate therapy.

Correspondence to : Pongchaiyakul C, Division of Endocrinology and Metabolism, Department of Medicine, Faculty of Medicine, Khon Kaen University, Khon Kaen 40002, Thailand. Phone: 043-363-664, 043-363-746, Fax: 043-347-542, E-mail: pchatl@kku.ac.th

Case Reports

Case 1

The first case was a 42-year-old woman with underlying breast cancer (Stage T1-2 N0 Mx), diagnosed in 2000. She had undergone a modified radical mastectomy with chemotherapy and radiation. In 2002, she had a relapse of the breast cancer with bony metastasis and was given intravenous zoledronic acid (4 mg monthly) for three years. In November 2005, she had painful exposed bone at the left body of the mandible and had an area of ulcerated mucosa. The symptoms developed two months after dental extraction despite no underlying dental disease.

The dentist found yellow-white discoloration of exposed bone, surrounding a soft tissue inflammation (Fig. 1). A radiological study showed bone destruction of the left body of the mandible (Fig. 2). Initially, conservative removal of exposed bone with primary closure was performed and systemic antibiotic given. Notwithstanding, she developed a non-healing socket surrounded by mucosal inflammation (Fig. 3); therefore, curettage, conservative otoplasty and saline irrigation was done.

The pathological examination revealed multiple small irregular fragments of necrotic bone trabeculae with no viable osteocyte in the lacunae.

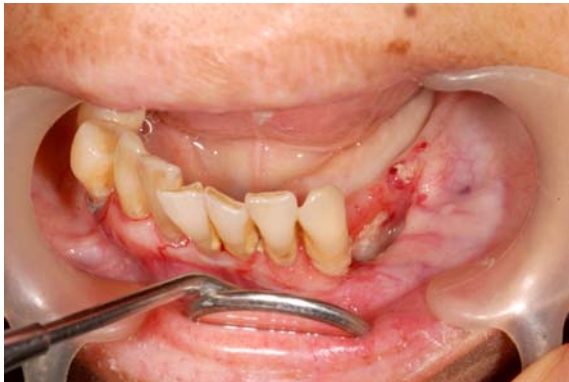

Fig. 1 Bone exposure at the left body of the mandible

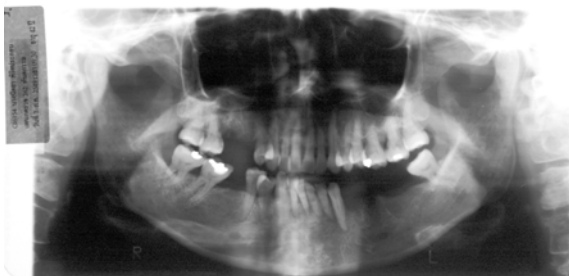

Fig. 2 Panoramic radiography shows bone destruction at left the body of the mandible

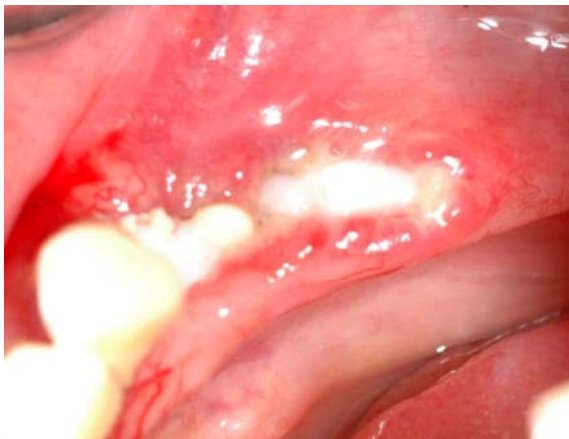


Fig. 3 Bone exposure and soft tissue infection at the second visit (mirror view)

The empty lacuna was enlarged. There was no evidence of inflammation or new bone formation (Fig. 4). The patient followed up with the dentist and underwent saline irrigation multiple times with minimal recovering of affected area, at the last visit she still had non-healed socket with mild soft tissue inflammation and finally

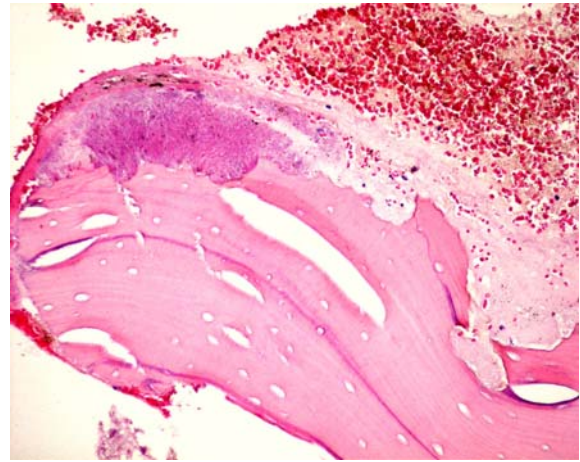


Fig. 4 Histopathologic section shows a small fragment of necrotic bone with an absence of inflammatory cells (Hematoxylin-eosin stain of demineralized tissue; original magnification 200 \times)

she was lost to follow up and died of her underlying disease in February 2007.

Case 2

The second case was a 61-year-old man with underlying multiple myeloma (Stage IIIB), first diagnosed in February 2000. He was treated with various regimens of chemotherapy due to relapses of the disease. For treatment of hypercalcemia, he had been given 37 doses of intravenous pamidronate (90 mg monthly) since December 2004. In March 2006, he had painful pus drainage from his previous molar denture. The dentist found an exposed maxillary bone and pamidronate was discontinued after he developed this dental problem.

Conservative removal of the exposed bone with primary closure was performed and systemic antibiotic was given. After the treatment, pus was drained from the edentulous area and the dentist found a sinus tract (Fig. 5).

A radiological study revealed an osteolytic lesion of the maxilla and a scattered area of bone destruction (*i.e.*, a moth-eaten appearance) (Fig. 6). Debridement and tissue biopsies were done. The pathological examination showed multiple small irregular fragments of bone necrosis, bone debris and multiple sheets of mild to moderate atypical plasma cells (Fig. 7). A conservative antibiotic was prescribed by the dentist. At his last visit with the dentist, the sinus tract was still presented and no new bone formation was observed.

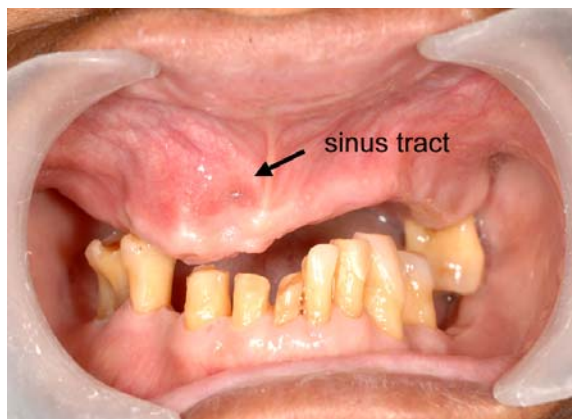


Fig. 5 Bone exposure at the anterior part of maxilla with fistula opening and pus drainage

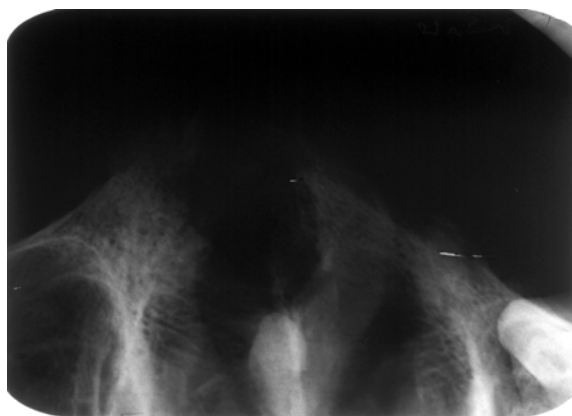
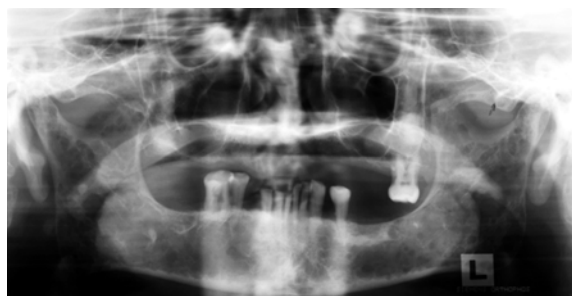

Fig. 6 Radiological study showing osteolytic lesion of the maxilla and scattered moth-eaten pattern of bone destruction

In October 2006, the patient was admitted to hospital due to subarachnoid hemorrhage and died from this condition.

Discussion

Bisphosphonates are used to treat metabolic bone diseases (i.e., osteoporosis, multiple myeloma

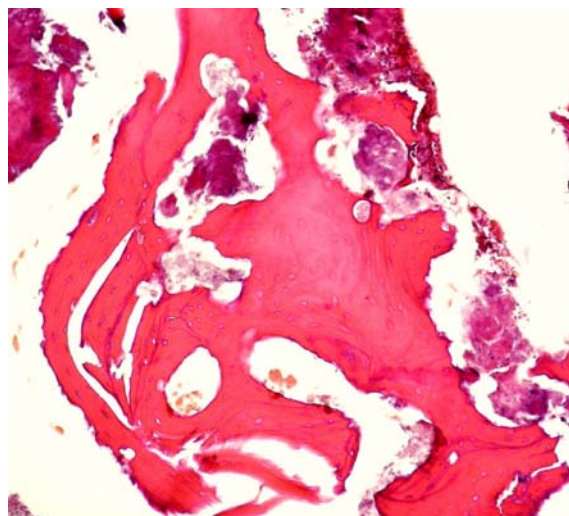


Fig. 7 Histopathologic section showing small fragments of dead bone and bone debris (Hematoxylin-eosin stain of demineralized tissue; original magnification 200 \times)

and skeletal events) associated with metastatic neoplasms. The non-aminobisphosphonates are metabolized by osteoclasts to inactive non-hydrolyzable adenosine triphosphate analogues that are directly cytotoxic to the cell and induce apoptosis^(11,12).

Aminobisphosphonates have two actions: (1) induction of another adenosine triphosphate analogue that induces apoptosis; and, (2) inhibition of farnesyl diphosphonate synthase, which is part of the mevalonate pathway of cholesterol synthesis, leading to inhibition of osteoclast function. In addition, aminobisphosphonates reduce recruitment of osteoclasts and induce osteoblasts to produce an osteoclast-inhibiting factor^(13,14). Bisphosphonates are not metabolized and have a strong binding affinity with osteoclasts. They can persist in bone for months and sometimes years after the drug has been discontinued^(15,16).

Though the exact nature of the relationship between BPs and ONJ is unknown, some researchers have postulated that BPs can prevent the formation of new blood vessels within jawbone tissue. Without being able to produce new blood vessels, the healing process of jawbone tissue is compromised, allowing for the degradation of bone mass⁽²⁾. In patients with high dosage and long-term treatment with BPs, particularly drugs with high bone affinity, it could induce an over-suppression of bone turnover^(15,16). In the last 4 years, there has been a significant increase of literature suggesting BP-use, especially intravenous preparations, may be associated with osteonecrosis of

Table 1. Clinical staging of bisphosphonate-related ONJ⁽¹⁹⁾

Stage	Clinical presentations
1	Exposed, necrotic bone that is asymptomatic
2	Exposed, necrotic bone associated with pain and infection
3	Exposed, necrotic bone in patients with pain, infection, and pathologic fracture, extraoral fistula, or osteolysis extending to the inferior border

the jaws. Increasing of ONJ has also been reported with the use of oral BPs^(2,4).

The typical clinical presentation of ONJ includes pain, soft-tissue swelling and infection, loosening of teeth, drainage and exposed bone^(2,18,19). These symptoms may occur spontaneously, or more commonly, at the site of previous tooth extraction. Patients may also present with feelings of numbness, heaviness and dysesthesias of the jaw. However, ONJ may remain asymptomatic for weeks or months, and may only become evident after finding exposed bone in the jaw^(2,4,19). The mandible is more commonly affected than the maxilla (2:1 ratio), and 60% of cases are preceded by a dental surgical procedure⁽²⁾. The extent of symptoms and clinical presentation can vary despite similar disease processes, bisphosphonate dosage regimens and treatment duration. A clinical staging of ONJ is presented in Table 1.

In the present report, the first case's clinical findings correlated with second stage ONJ at mandibular bone which occurred after dental procedure, these characteristics were in similar manners with most of the former case reports⁽⁴⁾. The second case is, however, compatible with third stage ONJ and the affected site was maxillary bone. Despite adequate debridement and antibiotics, the results were unsatisfactory in both cases.

Since this condition and its complications result in significant chronic pain, dysfunction, and disfigurement, which are difficult to treat, the focus should be on prevention. It is important that all health professionals, especially dentists, oncologists and oral surgeons, be aware of the possibility that patients being considered for dental extractions or other oral surgery are undergoing intravenous or oral BP-therapy. It is also important for patients to be informed of the risk of this complication of BP-therapy, so that they have the opportunity to assess the need for dental treatment before starting the medication^(19,20).

Prescribers, particularly endocrinologists, gynecologists and orthopedists, should be aware that ONJ can occur in association with oral BP-therapy for osteoporosis; therefore, a dental examination should be done before starting treatment with BPs. The BP labels now advise prescribers to consider having patients with these and other risk factors undergo dental evaluation and necessary preventive and non-invasive dental care before they start receiving BP-treatment.

Crucially, there is no definitive way to treat ONJ at present. Although there is recommendation to discontinue intravenous BPs in cancer patients⁽⁵⁾, there is no published evidence to support or oppose discontinuation of bisphosphonate therapy, once osteonecrosis develops or before required dental surgery. Because of the long half-life of bisphosphonates, the recovery of normal osteoclast function and bone turnover, after drug withdrawal, may be too gradual for this measure to have clinical significance. Consequently, conservative debridement of necrotic bone, pain control, infection management, use of antibiotics, and withdrawal of bisphosphonates are preferable to aggressive surgical measures for treating this condition. In rare cases, small sections of necrotic tissue can be surgically removed, though the surgery is potentially fatal and can result in a patient's inability to chew solid food, which will affect the quality of life.

Conclusion

The authors reported two cases of bisphosphonate-related osteonecrosis of the jaw (ONJ). Both cases were associated with intravenous bisphosphonate therapy (*i.e.*, zoledronic acid and pamidronate). Therefore, the focus should be on prevention by attending to any necessary dental treatment before bisphosphonate therapy begins.

Acknowledgments

The authors wish to thank the Faculty of Medicine, Khon Kaen University, for support and Mr. Bryan Roderick Hamman for his assistance with the English-language presentation of the manuscript.

References

1. Woo SB, Hande K, Richardson PG. Osteonecrosis of the jaw and bisphosphonates. *N Engl J Med* 2005; 353: 99-102.
2. Woo SB, Hellstein JW, Kalmar JR. Narrative [corrected] review: bisphosphonates and osteonecrosis of the jaws. *Ann Intern Med* 2006; 144: 753-61.

3. Marx RE. Pamidronate (Aredia) and zoledronate (Zometa) induced avascular necrosis of the jaws: a growing epidemic. *J Oral Maxillofac Surg* 2003; 61: 1115-7.
4. Ruggiero SL, Mehrotra B, Rosenberg TJ, Engroff SL. Osteonecrosis of the jaws associated with the use of bisphosphonates: a review of 63 cases. *J Oral Maxillofac Surg* 2004; 62: 527-34.
5. Krueger CD, West PM, Sargent M, Lodolce AE, Pickard AS. Bisphosphonate-induced osteonecrosis of the jaw. *Ann Pharmacother* 2007; 41: 276-84.
6. Watts NB, Harris ST, McClung MR, Bilezikian JP, Greenspan SL, Luckey MM. Bisphosphonates and osteonecrosis of the jaw. *Ann Intern Med* 2006; 145: 791-2.
7. Advisory Task Force on Bisphosphonate-Related Osteonecrosis of the Jaws, American Association of Oral and Maxillofacial Surgeons. American Association of Oral and Maxillofacial Surgeons position paper on bisphosphonate-related osteonecrosis of the jaws *J Oral Maxillofac Surg* 2007; 65: 369-76.
8. Mehrotra B, Fantasia J, Nissel-Horowitz S, Vinarsky S, Ruggiero S. Osteonecrosis of the maxilla: an unusual complication of prolonged bisphosphonate therapy: a case report. *Proc Am Soc Clin Oncol* 2003; 22: 795.
9. Rosenberg TJ, Ruggiero S. Osteonecrosis of the jaws associated with the use of bisphosphonates. *J Oral Maxillofac Surg* 2003; 61(Suppl 1): 60.
10. Migliorati CA. Bisphosphonates and oral cavity avascular bone necrosis. *J Clin Oncol* 2003; 21: 4253-4.
11. Fleisch H. Bisphosphonates: mechanisms of action. *Endocr Rev* 1998; 19: 80-100.
12. Russell RG, Croucher PJ, Rogers MJ. Bisphosphonates: pharmacology, mechanisms of action and clinical uses. *Osteoporos Int* 1999; 9(Suppl 2): S66-80.
13. Hughes DE, MacDonald BR, Russell RG, Gowen M. Inhibition of osteoclast-like cell formation by bisphosphonates in long-term cultures of human bone marrow. *J Clin Invest* 1989; 83: 1930-5.
14. Vitte C, Fleisch H, Guenther HL. Bisphosphonates induce osteoblasts to secrete an inhibitor of osteoclast-mediated resorption. *Endocrinology* 1996; 137: 2324-33.
15. Mashiba T, Mori S, Burr DB, Komatsubara S, Cao Y, Manabe T, et al. The effects of suppressed bone remodeling by bisphosphonates on microdamage accumulation and degree of mineralization in the cortical bone of dog rib. *J Bone Miner Metab* 2005; 23(Suppl): 36-42.
16. Odvina CV, Zerwekh JE, Rao DS, Maalouf N, Gottschalk FA, Pak CY. Severely suppressed bone turnover: a potential complication of alendronate therapy. *J Clin Endocrinol Metab* 2005; 90: 1294-301.
17. Carter G, Goss AN, Doecke C. Bisphosphonates and avascular necrosis of the jaw: a possible association. *Med J Aust* 2005; 182: 413-5.
18. Expert panel recommendations for the prevention, diagnosis, and treatment of osteonecrosis of the jaws. *LDA J* 2005; 64: 21-4.
19. Ruggiero SL, Fantasia J, Carlson E. Bisphosphonate-related osteonecrosis of the jaw: background and guidelines for diagnosis, staging and management. *Oral Surg Oral Med Oral Pathol Oral Radiol Endod* 2006; 102: 433-41.
20. Ruggiero SL, Gralow J, Marx RE, Hoff AO, Schubert MM, Huryn JM, et al. Practical guidelines for the prevention, diagnosis and treatment of osteonecrosis of the jaw in patients with cancer. *J Clin Oncol Pract* 2006; 2: 7-14.

การเกิดกระดูกขากรรไกรตายจากยาบิสฟอสโฟเนต รายงานผู้ป่วย 2 ราย

ฉัตรเลิศ พงษ์ไชยกุล, กฤตินันท์ อุไรวรรณ, แพรว โคตรอุฉิน, จุไรรัตน์ กุหลาบแก้ว

กระดูกขากรรไกรตายพบว่ามีความสัมพันธ์กับการใช้ยากลุ่มอะมิโนบิสฟอสโฟเนต รายงานฉบับนี้ได้ นำเสนอผู้ป่วยจำนวน 2 รายที่เกิดกระดูกขากรรไกรตายจากการได้รับยาบิสฟอสโฟเนตชนิดฉีดเข้าทางหลอดเลือด โดยได้นำเสนออาการ อาการแสดงทางคลินิก ผลตรวจเอกซเรย์และผลตรวจทางพยาธิวิทยา เนื่องจากในปัจจุบัน ยังไม่มีวิธีการรักษาที่ได้ผลดีในผู้ป่วยที่เกิดกระดูกขากรรไกรตาย ดังนั้นการป้องกันจึงเป็นวิธีการที่ดีที่สุด โดยก่อนเริ่มการรักษาด้วยยาบิสฟอสโฟเนต ผู้ป่วยทุกรายควรได้รับการตรวจฟันจากทันตแพทย์ก่อน และระหว่างการรักษาด้วยยาบิสฟอสโฟเนต