

Case Report

Salmonella Gas-forming Femoral Osteomyelitis and Pyomyositis: the First Case and Review of the Literature

Opass Pucharoen MD*,
Chusana Suankratay MD, PhD*

* Division of Infectious Diseases, Department of Medicine, Faculty of Medicine, Chulalongkorn University

The authors describe the first case of *Salmonella* serogroup D gas-forming femoral osteomyelitis and pyomyositis in a 51-year-old man with non-Hodgkin lymphoma. The patient was successfully treated with surgical debridement as well as clindamycin plus ceftriaxone, and then switched to ciprofloxacin. However, he eventually died due to multidrug-resistant *Acinetobacter baumannii* pneumonia. In addition, five cases of *Salmonella* gas-forming pyomyositis in the literature were reviewed.

Keywords: *Salmonella*, Pyomyositis, Gas-forming, Osteomyelitis, Non-Hodgkin lymphoma

J Med Assoc Thai 2007; 90 (9): 1943-7

Full text. e-Journal: <http://www.medassocthai.org/journal>

Salmonella infections usually arise at the gastrointestinal tract. Bacteremia and extra-intestinal infections are rarely observed in immunocompetent hosts⁽¹⁻³⁾. The individuals at greater risk of these complications are those with impaired cell-mediated immunity including steroid or immunosuppressive therapy, malignancies, transplantations, connective tissue diseases, and acquired immune deficiency syndrome (AIDS). The site of localized infections commonly reported includes pulmonary, central nervous system, intra-abdominal, osteoarticular, and soft tissue infections⁽¹⁻³⁾. *Salmonella* osteoarticular and soft tissue infections were rarely reported. The authors describe the first case of *Salmonella* gas-forming osteomyelitis and pyomyositis in a patient with non-Hodgkin lymphoma (NHL).

Case Report

A 51-year-old man was admitted to King Chulalongkorn Memorial Hospital, Bangkok, Thailand due to a low-grade fever and progressive pain of both thighs for three weeks. The patients developed watery diarrhea lasting two days without antibiotic treatment, four weeks prior to his present illness. He was diagnosed as NHL five years ago, and received a complete

course of chemotherapy including cyclophosphamide, doxorubicin, vincristine, prednisolone, and fludarabine one year prior to admission.

On admission, physical examination revealed a body temperature of 37.5°C, pulse rates of 110/minute, respiratory rates of 24/min, and a blood pressure of 110/60 mmHg. There were markedly swollen, tender, warm thighs without the presence of crepitation. Other examinations were unremarkable. A complete blood count revealed a hematocrit of 31%, a white blood cell count of 6,580 cells/mm³ (91% neutrophils, 6% lymphocytes, and 3% monocytes), and a platelet count of 116,000 cells/mm³. Blood sugar was 149 mg/dL, and other blood chemistry tests were normal. Blood cultures were taken. Initial chest radiography was normal. Plain radiography showed multiple air collections in the subcutaneous tissues of both thighs. A needle aspiration at left thigh was performed and revealed a small amount of purulent discharge. Gram staining of the pus revealed numerous Gram-negative bacilli. The patient was empirically treated with intravenous clindamycin and ceftriaxone. Computed tomography of the abdomen and upper thighs exhibited multiple fluid collections, consistent with abscesses, in both thighs. Multiple air bubbles were also observed within the medullary parts of the femoral heads and thigh muscles, indicating gas-forming osteomyelitis and pyomyositis (Fig. 1). An immediate surgical debridement was then performed, with long incisions at the

Correspondence to : Suankratay C. Division of Infectious Diseases, Department of Medicine, Chulalongkorn University Hospital, Bangkok 10330, Thailand. Phone & Fax: 0-2256-4578, E-mail: chusana.s@chula.ac.th

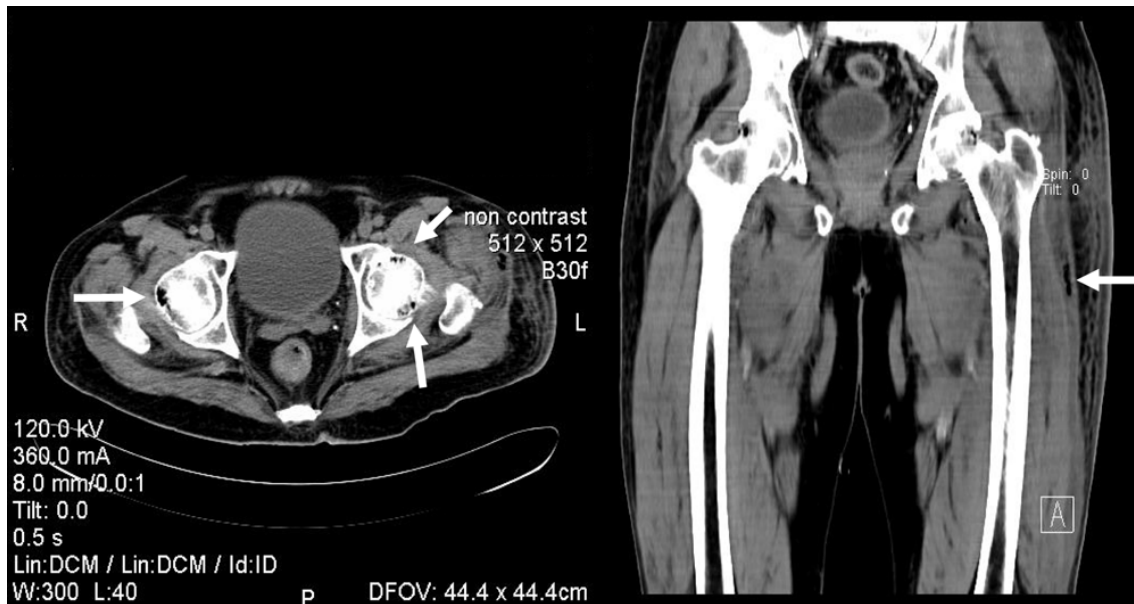


Fig. 1 Computed tomography exhibited multiple air bubbles within the medullary parts of the femoral heads and thigh muscles (arrows), indicating gas-forming osteomyelitis and pyomyositis

lateral aspect of both thighs. Intra-operative findings revealed multiple pus collections at both vastus lateralis muscles. Immediately after operation, the patient developed acute respiratory failure requiring the respiratory support. Pus and blood cultures eventually grew *Salmonella* serogroup D, resistant to ampicillin, tetracycline, chloramphenicol, and trimethoprim-sulfamethoxazole, but were susceptible to ciprofloxacin and ceftriaxone. The minimal inhibitory concentration (MIC) for ciprofloxacin was 0.125 µg/dL. The antibiotics were then switched to intravenous ciprofloxacin (400 mg every 8 hours), and his clinical condition gradually improved. However, the patient developed multidrug-resistant *Acinetobacter baumannii* nosocomial pneumonia, and eventually expired eight weeks after hospitalization.

Discussion

Extra-intestinal infections are very rare, representing 5% to 10% of all patients with *Salmonella* bacteremia⁽¹⁻³⁾. The occurrence of soft tissue infections accounts for 3% to 12% of these complications^(3,4). Only a minority of the patients can recognize a history of diarrhea prior to their present illness, probably due to a long incubation period and other non-intestinal entry routes of infection^(4,5). A retrospective review by Collazos et al demonstrated the mean duration between previous salmonellosis and the present soft tissue in-

fection was approximately 13 weeks⁽⁴⁾. In the presented patient, a history of watery diarrhea was noted four weeks prior to the present illness. *S. Enteritidis* accounts for the most common serotypes associated with *Salmonella* soft tissue infections, followed by *S. Typhimurium*, *S. Choleraesuis*, and *Salmonella* serogroup B. However, a wide variation in the causative serotypes is observed among different countries, probably due to the differences in the study period, epidemiology, sanitation, and consumption behavior. The present patient had *Salmonella* serogroup D infection.

The presence of air collections in the soft tissue is caused by many processes including both infectious and non-infectious processes. For infectious process, a wide variety of bacteria has been reported to cause gas-forming skin and soft tissue infections. Anaerobic bacteria including *Clostridium*, *Bacteroides*, and anaerobic streptococci are the most common isolated pathogens, followed by mixed aerobic and anaerobic bacteria. However, gas-forming infections caused by strict aerobic or facultative anaerobic bacteria have been reported⁽⁶⁻⁹⁾. These include *Klebsiella*, *Escherichia coli*, *Streptococcus*, and *Staphylococcus*. Even though most *Salmonella* are capable of fermenting carbohydrates with gas formation, to the best of the authors' knowledge, there have been five cases of *Salmonella* gas-forming pyomyositis in the literature (Table 1)⁽¹⁰⁻¹⁴⁾. All were immuno-compromised patients

Table 1. Summary of six case reports of *Salmonella* gas-forming pyomyositis from the English literature

Year, country	Age, sex (years)	Underlying disease	Subspecies or serotype of <i>Salmonella</i>	Antecedent of diarrhea, duration PTA	Infection site	Treatment		Outcome
						Medication	Surgery	
1971, the US ⁽¹⁰⁾	Male, 43	SLE with steroid treatment	<i>S. Typhimurium</i>	Yes, 2 months	Thighs, knee, buttock	Colistin, chloramphenicol, gentamicin, penicillin	Yes	Died due to persistent infection
1990, Israel ⁽¹¹⁾	Female, 19	SLE with steroid treatment	<i>S. Enteritidis</i>	NA	Legs, hands, elbows	Cotrimoxazole, ceftriaxone, pefloxacin	Yes	Survived with 3 months of pefloxacin
1991, the US ⁽¹²⁾	Male, 72	Diabetes mellitus, hypertension, CVD, atherosclerotic heart disease	<i>Salmonella</i> serogroup B	Yes, 3 months	Leg	Ampicillin, gentamicin, clindamycin	Yes, with amputation	Survived
1994, Denmark ⁽¹³⁾	Male, 65	Diabetes mellitus	<i>S. Enteritidis</i>	Yes, 5 weeks	Leg	Penicillin, gentamicin, metronidazole, ciprofloxacin	Yes	Survived with 6 weeks of ciprofloxacin
2004, Thailand ⁽¹⁴⁾	Female, 31	SLE with steroid and immunosuppressive treatment	<i>Salmonella</i> serogroup B	Yes, several months	Arm, forearm	Meropenem, metronidazole, levofloxacin	Yes	Survived with 4 weeks of antibiotics
2006, Thailand (present report)	Male, 51	NHL with immunosuppressive treatment	<i>Salmonella</i> serogroup D	Yes, 4 weeks	Thighs, femurs	Ceftriaxone, clindamycin, ciprofloxacin	Yes	Died due to nosocomial pneumonia

US: United States of America, PTA: prior to admission, SLE: systemic lupus erythematosus, CVD: cerebrovascular disease, NA: not applicable, NHL: non-Hodgkin lymphoma

including three systemic erythematosus (SLE) with steroid treatment and two diabetes mellitus. All but one patient survived with a combination of extensive surgical debridement and appropriate antibiotic treatment. *Salmonella* serogroup B was the most common causative bacteria, followed by *S. Enteritidis*. This observation is in contrast with that described in non-gas-forming pyomyositis, which was commonly caused by *S. Typhimurium*^(4,5). Four patients (80%) with gas-forming pyomyositis presented with leg muscle involvement, alone or in association with other muscles (Table 1). In contrast, psoas muscle was mostly involved in the patients with *Salmonella* non-gas-forming pyomyositis. This may be due to different pathogenesis between the two conditions. *Salmonella* gas-forming pyomyositis is usually associated with systemic bacteremia secondary from gastroenteritis, in comparison with a high occurrence of contiguous in-

fection like aortitis or lumbar spondylitis in *Salmonella* non-gas-forming pyomyositis. Accordingly, in contrast to the observation in *Salmonella* non-gas-forming pyomyositis^(4,5), most patients with gas-forming pyomyositis had an antecedent of self-limited diarrhea.

David et al reported the first case of *Salmonella* gas-forming pyomyositis in 1971⁽¹⁰⁾. The patient was a 43-year-old man with SLE who was receiving corticosteroid and presented with crepitant pyomyositis of the thighs, knee, and buttock due to *S. Typhimurium*. He died due to persistent *Salmonella* infection despite aggressive surgical debridement and antibiotic treatment. The second case was described in a 19-year-old woman with SLE and steroid treatment⁽¹¹⁾. She developed bilateral *S. Enteritidis* leg abscesses and osteomyelitis mimicking deep venous thrombosis. She survived and had received oral pefloxacin for three months after discharge from the hospital. Quale and

Lonano reported *Salmonella* serogroup B crepitant pyomyositis in an elderly man with diabetes mellitus⁽¹²⁾. He had an extensive necrosis of several leg muscles and chronic arterial insufficiency, requiring the amputation of the leg. The fourth case of *S. Enteritidis* crepitant pyomyositis of the leg was described by Jorring et al⁽¹³⁾. The treatment included an extensive debridement in accordance with intravenous penicillin, metronidazole, and ciprofloxacin. Jidpugdeebodin and Panyakupta reported the fifth case in 2004⁽¹⁴⁾. A 31-year-old Thai woman with SLE presented with *Salmonella* serogroup B crepitant pyomyositis of the left arm. She survived and had received oral levofloxacin for four weeks.

Salmonella pyomyositis in accompanying with osteomyelitis is rarely described. Only two cases have been reported by Cohen et al⁽³⁾ as well as Shamiss et al⁽¹¹⁾. Gas-forming osteomyelitis has been reported to be associated with *Clostridium*, *Bacteroides*, *E. coli*, *Klebsiella*, *Streptococcus*, and *Mycobacterium*^(15,16). To the authors' knowledge, the presented patient is the first case of gas-forming osteomyelitis caused by *Salmonella* serogroup D.

A widespread inappropriate use of antibiotics in livestock industry to prevent bacterial infections and for growth promotion is increasing^(17,18). Hence, the prevalence of drug-resistant non-typhoidal salmonellosis has increased in parallel with this practice. Some *Salmonella* isolates from animals have an elevated level of MIC to commonly used antibiotics for treatment of salmonellosis including fluoroquinolones, ampicillin, cephalosporins, and cotrimoxazole. The presented patient was infected with multidrug-resistant *Salmonella* resistant to ampicillin, tetracycline, chloramphenicol, and cotrimoxazole. The MIC for ciprofloxacin was 0.125 µg/mL, indicating reduced susceptibility to this antibiotic⁽¹⁹⁾.

In conclusion, the authors describe the first case of gas-forming osteomyelitis and pyomyositis caused by *Salmonella* serogroup D in a patient with NHL. In addition, five cases of *Salmonella* gas-forming pyomyositis in the literature were reviewed in the present report.

References

1. Parry CM, Hien TT, Dougan G, White NJ, Farrar JJ. Typhoid fever. *N Engl J Med* 2002; 347: 1770-82.
2. Hohmann EL. Nontyphoidal salmonellosis. *Clin Infect Dis* 2001; 32: 263-9.
3. Cohen JI, Bartlett JA, Corey GR. Extra-intestinal manifestations of *Salmonella* infections. *Medicine (Baltimore)* 1987; 66: 349-88.
4. Collazos J, Mayo J, Martinez E, Blanco MS. Muscle infections caused by *Salmonella* species: case report and review. *Clin Infect Dis* 1999; 29: 673-7.
5. Ramos JM, Garcia-Corbeira P, Aguado JM, Ales JM, Soriano F. Classifying extraintestinal nontyphoid *Salmonella* infections. *QJM* 1996; 89: 123-6.
6. DiGioia RA, Kane JG, Parker RH. Crepitant cellulitis and myonecrosis caused by *Klebsiella*. *JAMA* 1977; 237: 2097-8.
7. Durlach RA, Rigou RM, Fernandez L. Crepitant cellulitis caused by *Klebsiella pneumoniae*. *Medicina (BAires)* 1983; 43: 659-64.
8. Bruno-Murtha LA, Sedghivaziri MA, Arbeit RD. Crepitant myonecrosis caused by *Klebsiella pneumoniae* in an immunocompromised diabetic patient. *J Infect Dis* 1990; 162: 1415-6.
9. Merino AJ, Pastor RA, Montejo Baranda JM, Martinez LF, Aguirre EC. *E. coli* bacteremia and non-Clostridial crepitant cellulitis after transrectal prostatic biopsy in a diabetic patient. *Rev Clin Esp* 1983; 169: 271-2.
10. David DS, Brennan L, Grieco MH. Gas production with *Salmonella typhimurium* infection. *Am J Med Sci* 1971; 262: 255-60.
11. Shamiss A, Thaler M, Nussinovitch N, Zissin R, Rosenthal T. Multiple *Salmonella* enteritidis leg abscesses in a patient with systemic lupus erythematosus. *Postgrad Med J* 1990; 66: 486-8.
12. Quale JM, Lonano F. *Salmonella* myonecrosis in a patient with diabetes mellitus. *Am J Med Sci* 1991; 301: 335-6.
13. Jorring S, Kolmos HJ, Klareskov B. Myonecrosis in the leg caused by *Salmonella* enteritidis. *Scand J Infect Dis* 1994; 26: 619-21.
14. Jidpugdeebodin Suwanee PS. *Salmonella* crepitant pyomyositis in a patient with systemic lupus erythematosus. *J Infect Dis Antimicrob Agents* 2004; 21: 11-5.
15. Bielecki DK, Sartoris D, Resnick D, Van Lom K, Fierer J, Haghighi P. Intraosseous and intradiscal gas in association with spinal infection: report of three cases. *AJR Am J Roentgenol* 1986; 147: 83-6.
16. Chen CW, Yang CJ, Huang JJ, Chuang YC, Young C. Gas-forming vertebral osteomyelitis in diabetic patients. *Scand J Infect Dis* 1991; 23: 263-5.
17. Gay K, Robicsek A, Strahilevitz J, Park CH, Jacoby G, Barrett TJ, et al. Plasmid-mediated quinolone resistance in non-Typhi serotypes of *Salmonella enterica*. *Clin Infect Dis* 2006; 43: 297-304.
18. Varma JK, Marcus R, Stenzel SA, Hanna SS, Gettner

S, Anderson BJ, et al. Highly resistant *Salmonella* Newport-MDR AmpC transmitted through the domestic US food supply: a FoodNet case-control study of sporadic *Salmonella* Newport infections, 2002-2003. *J Infect Dis* 2006; 194: 222-30.

19. Crump JA, Barrett TJ, Nelson JT, Angulo FJ. Reevaluating fluoroquinolone breakpoints for *Salmonella enterica* serotype Typhi and for non-Typhi *Salmonellae*. *Clin Infect Dis* 2003; 37: 75-81.

การติดเชื้อชนิด gas-forming ของกระดุกพีเมอร์และกล้ามเนื้ออักเสบเป็นหนอง จาก *Salmonella*: รายงานแรกและการรวบรวมผู้ป่วยทั้งหมด

โอภาส พุทธเจริญ, ชุษณา สอนกระต่าย

การรายงานผู้ป่วยรายแรกที่มีการติดเชื้อชนิด gas-forming ของกระดุกพีเมอร์และกล้ามเนื้ออักเสบเป็นหนอง (pyomyositis) จาก *Salmonella* serogroup D ในผู้ป่วยเพศชายอายุ 51 ปี ที่เป็นมะเร็งต่อมน้ำเหลืองชนิด non-Hodgkin ผู้ป่วยตอบสนองต่อการรักษาด้วยการผ่าตัดและยาปฏิชีวนะ clindamycin ร่วมกับ ceftriaxone แล้วเปลี่ยนเป็น ciprofloxacin อย่างไรก็ตามในที่สุดผู้ป่วยถึงแก่กรรมเนื่องจากเกิดการติดเชื้อในปอดจาก *Acinetobacter baumannii* ที่ติดต่อจากยาปฏิชีวนะหลายขนาน นอกจากนั้นยังมีการรวบรวมผู้ป่วย 5 ราย ที่มีรายงานการติดเชื้อชนิด gas-forming ของกล้ามเนื้ออักเสบเป็นหนอง