

Case Report

Laparoscopic Nephrectomy, Hysterectomy and Rectovaginal Endometriotic Mass Removal in a Single Session

Kittinut Kijvikai MD*,
Chartchai Srisombut MD**, Yada Tingthanatikul MD**

* Section of Minimally Invasive Surgery, Division of Urology, Department of Surgery, Faculty of Medicine, Ramathibodi Hospital, Mahidol University

** Gynecologic Endoscopy Unit, Division of Reproductive Medicine, Department of Obstetrics and Gynecology, Faculty of Medicine, Ramathibodi Hospital, Mahidol University

The authors reported the first case of endometriosis with ureteral involvement causing nonfunctioning kidney, which was managed by laparoscopic nephrectomy, hysterectomy, and endometriotic mass removal in a single session.

Keywords: Laparoscopic nephrectomy, Endometriosis, Hysterectomy

J Med Assoc Thai 2007; 90 (9): 1934-6

Full text. e-Journal: <http://www.medassocthai.org/journal>

Ureteral endometriosis involving the urinary tract is uncommon and is estimated to occur in about 0.08% to 1% of patients with endometriosis⁽¹⁾. A high index of suspicion should be maintained because the sequelae of the disease process can result in loss of a renal unit. Because of this rare occurrence of urinary tract involvement, treatment recommendations so far rely on case reports. Current therapeutic recommendations for women with ureteral endometriosis who do not desire further pregnancies include resection of the endometriosis and bilateral oophorectomy with or without hysterectomy⁽²⁻⁴⁾. However, if the kidney is severely impaired, then nephrectomy is recommended^(5,6). With the development of minimally invasive surgery, the authors reported the first case of endometriosis invading left ureter with endometriotic mass. This was managed by laparoscopic surgery in a single session.

Case Report

A 40-year-old multiparous woman presented with pelvic pain and prolonged menstruation for 9

Correspondence to : Kijvikai K, Division of Urology, Department of Surgery, Faculty of Medicine, Ramathibodi Hospital, Mahidol University, 270 Rama 6 Rd, Tungphayatai, Rajathevee, Bangkok 10400, Thailand. Phone: 0-2201-1315, Fax: 0-2201-1316, E-mail: kittinutk@hotmail.com

months. No specific urologic symptom was detected. Pelvic examination revealed red spot around cervical os, enlargement of the uterus and rectovaginal (RV) mass at cul-de-sac. Transvaginal ultrasonogram showed RV mass 2.5 x 1.5 cm, which was suspected as an endometriotic mass. Cystoscopy was within normal limits. The intravenous pyelogram showed a normally functioning right kidney and non-functioning left kidney. An ultrasonogram demonstrated a severe left hydronephrosis with paper-thin cortex and ^{99m}Tc-DTPA revealed nonfunction of the left kidney and normal function of the right kidney. After having been explained about the risk, benefits, and possible complications of different therapeutic options, the patient gave consent to undergo a laparoscopic hysterectomy, endometriotic mass removal and nephrectomy.

The patient was placed in the lateral decubitus (left side elevated) with a flexion of the table for retroperitoneoscopic nephrectomy. Three 10-mm ports were placed in a standard fashion (Fig. 1A). With the use of a self-styled balloon dilator to create retroperitoneal space, the hilar vessel were identified, dissected, clipped, and divided. The kidney was mobilized and the ureter was followed, ligated, and cut as long as possible. Then, the kidney and ureter were entrapped in a specimen bag and put into the pelvic region.

Finally, the patient was placed in the modified lithotomy and Trendelenburg position for laparoscopic hysterectomy and rectovaginal endometriotic mass removal. Four more ports (5 mm x 3, 10 mm x 1) were inserted in a fan-shape fashion (Fig. 1B). By the standard technique of laparoscopic hysterectomy, the uterus and endometriotic rectovaginal mass were removed. Then, the peritoneum was opened and the kidney was pulled into the abdominal cavity and removed through the vaginal opening. The vaginal stump was closed by intracorporeal laparoscopic suture. The total operative time was 260 minutes: 100 minutes for nephrectomy and 160 minutes for hysterectomy and endometriotic mass removal. The total operative blood loss was 250 ml: 50 ml for nephrectomy and 200 ml for the rest. Drain was removed on the postoperative day 3. Only 6 mg of morphine was used for postoperative pain relief and the patient was discharged from the hospital on postoperative day 4. Histopathology confirmed endometriosis invading the ureter, endometriotic rectovaginal mass and adenomyosis of the uterus. The patient was doing well after surgery.

Discussion

The incidence of endometriosis involving urinary tract (bladder or ureter) ranges from 16 to 24 percent^(7,8). The most serious urologic complication of endometriosis is ureteral involvement. Permanent loss of renal function has been reported in 25 to 46 percent of patients with ureteral endometriosis^(6, 9-12). With the current therapeutic recommendations for women with ureteral endometriosis conservative surgery to relieve ureteral obstruction and remove endometriosis is the management of choice⁽¹⁾. However, in cases with severely impaired ipsilateral kidney (less than 10% to 15% on scintigraphy) or non-functioning kidney who do not desire further pregnancies, hysterectomy, endometriotic mass removal, and nephrectomy are considered⁽¹⁻⁶⁾.

By traditional open surgery, the authors may perform hysterectomy and endometriotic mass removal through a low midline or Pfannenstiel incision and perform a nephrectomy through a flank incision. These incisions cause a significant postoperative pain, less cosmetic and prolonged the period of return to normal activities.

At present, laparoscopic surgery is replacing traditional open surgery because of less operative blood loss, less postoperative pain, more precise dissection and better preservation of anatomical structures. In addition, it also has a better cosmetic result than the

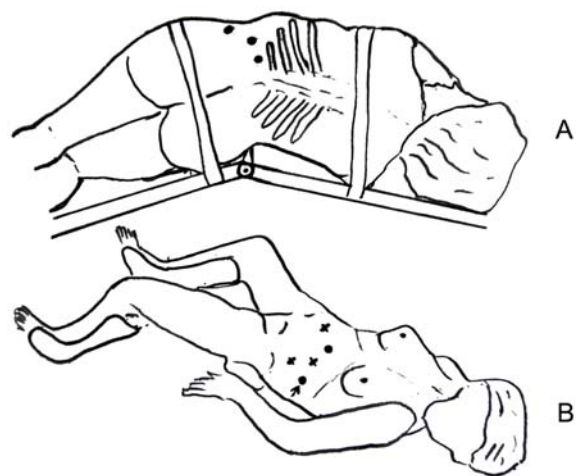


Fig. 1 Patient position and port placement, (A) position for retroperitoneoscopic nephrectomy, port placement (10 mm port x 3) is shown as indicated by black spots, (B) position for laparoscopic hysterectomy and endometriotic mass removal, four more ports (x 5 mm port, • = 10 mm port) were added in a fan shape fashion, the arrow shows one of the three previous nephrectomy ports

open surgery. It is believed that any concomitant pathology feasible to laparoscopic surgery can also be dealt with in the same session⁽¹³⁾. In the present case, the authors increased 110 minutes more operation time and 50 ml more operative blood loss for laparoscopic nephrectomy without increasing any morbidity. Moreover, the authors could reduce the abdominal wound for kidney extraction by removing the kidney specimen through the vaginal opening.

The authors have chosen retroperitoneoscopic nephrectomy because they were familiar with this technique and this approach was less time consuming to control the renal pedicle. If the authors were to perform transperitoneal approach, although it may decrease the number of port placement, it would not be more advantageous than the authors' familiar technique. This is because the less operative time and familiarity are considered more important. The authors recommended that nephrectomy should be performed first because it was easier and caused less bleeding when compared with hysterectomy in the case of endometriosis. Moreover, if the authors performed nephrectomy after hysterectomy, the authors might have to adjust the patient position three times because the patient had to be turned to the hysterectomy position again for suturing the vaginal stump. It would be difficult to close the vaginal stump in the lateral position.

Conclusion

This is the first case report in the literature where laparoscopic nephrectomy, hysterectomy, and endometriotic mass removal have been performed in a single session. This operation is safe and feasible. The authors' initial results encourage this minimally invasive concomitant organ surgery for rectovaginal endometriosis with severely impaired kidney from ureteral involvement.

Acknowledgements

The authors wish to thank Professor Amnuay Thithapandha for his help and advice concerning the preparation of this manuscript. The authors also wish to thank Dr. Piyaphan Punyatanasakchai and Dr. Charuspong Dissaranan for their assistance in the operation.

References

1. Donnez J, Nisolle M, Squifflet J. Ureteral endometriosis: a complication of rectovaginal endometriotic (adenomyotic) nodules. *Fertil Steril* 2002; 77: 32-7.
2. Shook TE, Nyberg LM. Endometriosis of the urinary tract. *Urology* 1988; 31: 1-6.
3. Magrina JF, Cornella JL, Nygaard IE, Fenner DE, Lidner TK, Lee RA, et al. Endometriosis involving the lower urinary tract. Part II: Results of surgical treatment. *J Pelvic Sur* 1996; 2: 176-81.
4. Langmade CF. Pelvic endometriosis and ureteral obstruction. *Am J Obstet Gynecol* 1975; 122: 463-9.
5. Rivlin ME, Krueger RP, Wisner WL. Danazol in the management of ureteral obstruction secondary to endometriosis. *Fertil Steril* 1985; 44: 274-6.
6. Jepsen JM, Hansen KB. Danazol in the treatment of ureteral endometriosis. *J Urol* 1988; 139: 1045-6.
7. Redwine DB. The distribution of endometriosis in the pelvis by age groups and fertility. *Fertil Steril* 1987; 47: 173-5.
8. Williams TJ, Pratt JH. Endometriosis in 1,000 consecutive celiotomies: incidence and management. *Am J Obstet Gynecol* 1977; 129: 245-50.
9. Appel RA. Bilateral ureteral obstruction secondary to endometriosis. *Urology* 1988; 32: 151-4.
10. Kane C, Drouin P. Obstructive uropathy associated with endometriosis. *Am J Obstet Gynecol* 1985; 151: 207-11.
11. Moore JG, Hibbard LT, Growdon WA, Schifrin BS. Urinary tract endometriosis: enigmas in diagnosis and management. *Am J Obstet Gynecol* 1979; 134: 162-72.
12. Klein RS, Cattolica EV. Ureteral endometriosis. *Urology* 1979; 13: 477-82.
13. Nabi G, Hemal AK. Laparoscopic repair of vesicovaginal fistula and right nephrectomy for non-functioning kidney in a single session. *J Endourol* 2001; 15: 801-3.

การผ่าตัดไต มดลูก เยื่อบุมดลูกเจริญผิดที่ ด้วยการผ่าตัดครั้งเดียวผ่านกล้อง

กิตติณัฐ กิจวิทย์, ซาติชัย ศรีสมบัติ, ญาดา ดิงธนาธิกุล

รายงานเทคนิค และผลของการผ่าตัดในผู้ป่วยภาวะเยื่อบุมดลูกเจริญผิดที่ และลูกกลมไปที่หลอดไต ซึ่งมีผลทำให้ไตสูญเสียการทำงานถาวร โดยใช้วิธีการผ่าตัดผ่านกล้อง การผ่าตัดทำสำเร็จโดยการนำไต มดลูก เยื่อบุมดลูกที่เจริญผิดที่ออกได้ในการผ่าตัดครั้งเดียว รายงานนี้เป็นรายงานแรกเท่าที่มีการสืบค้นได้ของวรรณกรรมที่มีรายงานมาก่อนหน้านี้