

Manual Sutureless Cataract Surgery with Foldable Intraocular Lens Using the Kongsap Technique: The Results of 95 Cases[□]

Pipat Kongsap MD*

[□] Presented in part at the 21th Congress of the Asia-Pacific Academy of Ophthalmology, Singapore, June 13, 2006

* Department of Ophthalmology, Prapokklao Hospital, Chanthaburi

Objective: To evaluate the visual outcome and complications of the small incision cataract surgery with foldable intraocular lens implantation using the Kongsap technique.

Study Design: Prospective, non-comparative study.

Material and Method: This prospective study was conducted at Prapokklao Hospital, Chanthaburi between December 2005 and May 2006. The ninety-five eyes of 95 patients underwent cataract surgery using the Kongsap technique. The best-corrected visual acuity, intra-operative and post operative complications, and the corneal endothelial cell loss were then evaluated. Follow-up visits were scheduled at one week, one month, three months, and six months.

Results: Best corrected visual acuity (BCVA) was 20/40 or better in 83 eyes (87.37%) at one week postoperatively, in 86 eyes (90.53%) at one month, in 87 eyes (91.58%) at 3 months, and in 85 eyes (89.48%) at 6 months. The most common intra-operative complication was iris prolapse (7.37%). Other intra-operative complications were posterior capsule rupture (2.11%), transient intracameral bleeding (2.11%), and capsulorhexis tear (2.11%). The most significant post operative complication was transient corneal edema located at the corneal wound, which developed in seven eyes (7.37%). No other significant complications were noted during the six-month follow up period. Mean endothelial cell loss was 5.3% at one month and 7.1% at three months post operatively.

Conclusion: Manual sutureless cataract surgery with foldable intraocular lens using the Kongsap technique when performed by an experienced surgeon was a safe procedure with good visual recovery and no need for a phaco machine.

Keywords: Cataract surgery, Manual cataract surgery, Visual acuity, Complication, Intraocular lens

J Med Assoc Thai 2007; 90 (8): 1627-32

Full text. e-Journal: <http://www.medassocthai.org/journal>

Phacoemulsification has become the routine procedure for cataract extraction in industrialized countries due to faster visual recovery, and better uncorrected visual acuity than sutured manual extracapsular cataract extraction (ECCE)⁽¹⁾.

However, in developing countries, whilst there has been a shift to surgery with an intraocular lens (IOL), phacoemulsification has played a limited role

due to the expense of equipment and the consumables required for this procedure.

Ophthalmologists working within developing countries are now exploring possible alternatives to phacoemulsification to obtain the advantages of a self-sealing sutureless incision at a significantly lower cost. Possible alternatives to phacoemulsification could ideally satisfy the economic restrictions that the medical profession within these struggling economies faces on a day-to-day basis. These factors are often unrecognized within more industrialized western medical communities.

Correspondence to : Kongsap P, Department of Ophthalmology, Prapokklao Hospital, Chanthaburi 22000, Thailand. Phone: 039-324-975 ext 1450, 081-863-2668, Fax: 039-324-861, E-mail: pkongsap@yahoo.com, pkongsap@gmail.com

Several techniques have been devised to perform ECCE without phacoemulsification. These have included the Quarters extraction, Phacosection, Manual multiphacofragmentation, Nylon Loop technique, and Prechop manual phacofragmentation⁽²⁻¹⁰⁾.

The Kongsap technique refers to small incision cataract surgery, in which the lens nucleus is divided into three fragments prior to manual removal through a relatively small incision, using inexpensive instrumentation⁽¹¹⁾. The foldable IOL is placed in the capsular bag and the wound is closed with no suture. The purpose of the present study was to determine the visual outcomes of this technique and to determine intra-operative and post operative complications.

Material and Method

This prospective study was conducted at Prapokklao Hospital, Chanthaburi from December 2005 to May 2006. The technique was undertaken on the ninety- five eyes of 95 patients (42 men and 53 women) in an age range of 48-81 years (mean age of 65.78) and all those who underwent cataract surgery using the Kongsap technique were included in the present study. Any patients with ocular pathology or previous ocular surgery were excluded from the present study.

A complete ophthalmologic examination was undertaken on all patients prior to surgery. This included a slitlamp examination with pupil dilatation, tonometry, keratometry, and A-scan biometry together with the usual investigations according to the protocols of cataract surgery. Written informed consent was obtained from all enrolled patients in the present study.

Surgical technique

All cataract surgery was performed by the same surgeon (PK). Lidocaine 2% was administered to achieve retrobulbar anesthesia. Two-side port, at the 3 and 7 o'clock position in the right eye was performed with a 15-degree stab knife. The anterior chamber maintainer (ACM) was introduced into the 3 o'clock side port incision. A 6-6.5 mm continuous curvilinear capsulorhexis (CCC) was performed with a 27 G bent needle when the anterior chamber was filled with balanced salt solution. Hydrodissection subsequently followed by hydrodelineation was performed until the golden ring was present. Anterior cortical debris was removed as much as possible in order to manipulate the hard-core nucleus easily. A 4 - mm temporal clear corneal wound was made using a 3- mm. keratome. The infusion was then either closed or the anterior chamber maintainer removed in order to make space for the

nucleus manipulation and the viscoelastic was then injected into the anterior chamber. The nucleus was dislocated out of the bag to the anterior chamber using a spatula and a Sinsky hook. Viscoelastic was also injected below and above the nucleus, facilitating this maneuver. The nuclear supporter (made from a 3-mm keratome, Fig. 1) was held by the left hand and the nuclear cutter by the right. The platform of nuclear supporter was passed under the nucleus and the nuclear cutter was placed over the nucleus. The nucleus was slightly manipulated and a trisection was made by gently pushing the nuclear supporter and the nuclear cutter against each other (Fig. 2). The nucleus was divided into three fragments and the final size of each fragment was approximately 3.0-3.5 mm. Viscoelastic was then again injected below and above the nucleus. The nuclear supporter was then passed under the first fragment whilst the nuclear cutter was placed over it and it was then pulled out (Fig. 3). The second and third fragments were also extracted using the same technique. Once the nuclear fragments were extracted, the BSS from the anterior chamber maintainer was opened. The epinucleus and lens cortex were flushed out by gentle pressure on the sclera posterior to the incision. The residual cortex was removed through the side port incision by a cortex extractor that was attached to an extension tube and a 10- ml syringe. The cortex removal was made possible by using a standard Simcoe canula instead of an anterior chamber maintainer and a cortex extractor. Viscoelastic was then injected into the anterior chamber and a foldable intraocular lens was implanted into the capsular bag using either forceps or the injector (Fig. 4). The wound was then closed with no suture.



Fig. 1 A nuclear supporter

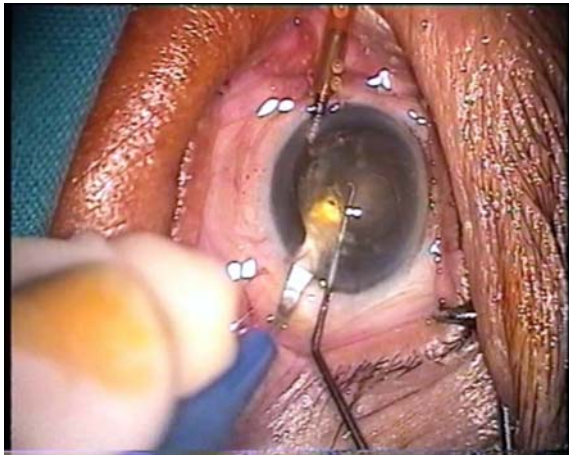


Fig. 2 Nuclear fragmentation using a nuclear suporter and a nuclear cutter

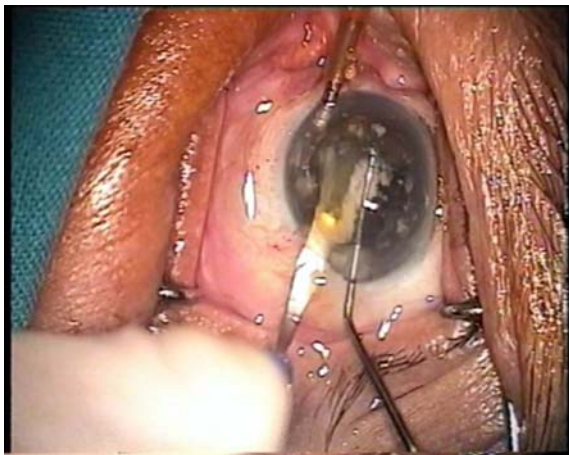


Fig. 3 Nuclear removal through the corneal incision

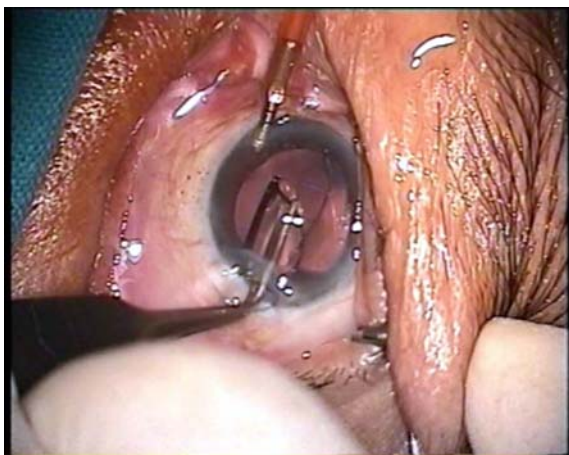

Fig. 4 The foldable intraocular lens implantation using the forceps

Post operative evaluations were performed at one week, one month, three months, and six months. Intra-operative/post operative complications and visual acuity were evaluated. The corneal endothelium was measured pre-operatively, 1 month, and 3 months after surgery using a confocal specular microscope.

Statistical analysis

Descriptive statistics with number and percentage, mean, standard deviation (SD) were used to describe the results of postoperative evaluations.

Results

The Kongsap technique was successfully performed in all 95 eyes of the 95 patients. Ten patients (10.53%) had soft nuclear cataracts, 79 patients (83.17%) had intermediate nuclear-cortical cataracts, and six (6.32%) had dense hard cataracts. Seventy patients had pre-operative visual acuity of 20/50 to 20/200 and 25 patients had visual acuity of worse than 20/200. The mean total surgical time was 13.14 minutes (range, 7 to 16 minutes). At the end of surgery, 92 eyes (96.84%) were unsutured and three eyes (3.16%) had one interrupted suture because of wound leakage.

Table 1 shows postoperative visual acuity. Best corrected visual acuity (BCVA) was 20/40 or better in 83 eyes (87.37%) after one week postoperatively, in 86 eyes (90.53%) at one month, in 87 eyes (91.58%) at 3 months, and in 85 eyes (89.48%) at 6 months. One eye with pre-existing high astigmatism had visual acuity of 20/100.

Table 2 shows the intra-operative and post-operative complications. Two cases had slight transient intracameral bleeding caused by accidental capture of the iris during IOL implantation. Posterior capsule rupture occurred in two eyes (2.11%) during the cortex aspiration and the intraocular lens was placed in the sulcus. Iris prolapse in cases of early perforation of the wound was seen in seven eyes (7.37%) while anterior capsular tear occurred in two eyes (2.11%).

Clear cornea was observed on the first post-operative day in 88 eyes (92.63%); minimal corneal edema occurred in seven eyes (7.37%) and responded well to topical steroid administration within a few days. An intraocular pressure increase of more than 25 mm Hg was observed the day after surgery in one eye (1.05%); pressure returned to normal within a few days.

Iritis was observed in one eye but it was resolved within 5 days after topical steroid administration. In one eye, the wound was sutured in the first day after the surgery because an aqueous humor leakage

Table 1. Postoperative visual acuity (n = 95)

BCVA	Follow-up visits			
	1 week No. (%)	1 month No. (%)	3 months No. (%)	6 months No. (%)
20/20 - 20/40	83 (87.37)	86 (90.53)	87 (91.58)	85 (89.48)
20/50 - 20/70	11 (11.58)	8 (8.42)	7 (7.37)	9 (9.47)
20/100 - 20/200	1 (1.05)	1 (1.05)	1 (1.05)	1 (1.05)

Table 2. Intraoperative and postoperative complications (n = 95)

Complications	Number of eyes	%
Intraoperative		
Iris prolapse	7	7.37
Transient intracameral bleeding	2	2.11
Capsule break without vitreous loss	2	2.11
Capsulorhexis tear	2	2.11
Postoperative		
Transient corneal edema	7	7.37
Ocular hypertension	1	1.05
Iritis	1	1.05
Endophthalmitis	0	
Corneal decompensation	0	

Table 3. Endothelial cell count and cell loss (n = 95)

Examination	Mean \pm SD	
	Count (cells/mm ²)	Loss (%)
Preoperative	2354 \pm 251	-
Postoperative		
1 month	2235 \pm 256	5.3 \pm 6.5
3 months	2150 \pm 278	7.1 \pm 6.6

was observed; in this case, early perforation into the anterior chamber had occurred during the surgery. There were no cases of endophthalmitis or corneal decompensation during the six - month follow up period.

Mean endothelial cell counts and the percentage of cell loss are shown in Table 3. Preoperatively, the mean endothelial cell count was 2354 \pm 251 cell/mm².

The mean endothelial cell loss was 5.3 \pm 6.5% at one month and 7.1 \pm 6.6% at three months postoperatively. The eyes that had developed corneal edema

did have a higher endothelial cell loss rate than those without corneal edema.

Discussion

The aim of all manual small incision cataract surgery is to reduce the size of any cataractous lens intraocularly so it can be manipulated and extracted through a relatively small incision. The incision size depends upon the dimensions and hardness of the nuclear fragments, which will be extracted from the anterior chamber. Usually, the nucleus is divided into 2 fragments, which with a soft cataract can be extracted through a 5.0 to 6.0 mm incision and the wound can be sutured with one stitch. With the hard nuclei, it is usually necessary to increase the wound size to a 5.5 to 7.0 mm incision to avoid damaging the iris and corneal endothelium.

With the Kongsap technique, the cataractous lens was placed on the nuclear supporter and divided into 3 fragments in the anterior chamber using the nuclear cutter or Sinsky hook. For intermediate nuclear-cortical cataract and soft nuclei, the fragment size is about 3.0-3.5 mm and this can be removed through a 3.5-4.0 mm incision. It is then possible to implant the foldable intra-ocular lens and close the wound with no suture. The instrument used for this technique can be made anywhere by the surgeon. The nuclear supporter is crafted from a keratome or crescent knife and the nuclear cutter can be made from a Sinsky hook.

Good visual outcomes were achieved for most cataract patients operated on with the Kongsap technique. Visual acuity of 20/40 or better was achieved in 83 eyes (87.37%) at the end of first post operative week and this result remained stable to 85 eyes (89.48%) at the end of six months. One patient achieved the visual acuity less than 20/100 because of pre-operative high astigmatism.

Iris prolapse (7.37%), the most frequent intra-operative complication, occurred during the removal

of the nucleus. It occurred because of early perforation into anterior chamber of the wound. All of them were observed in the first 30- eyes of the surgery using this technique.

Of the two cases of posterior capsule rupture, no eye was caused by the instrument, the nuclear supporter. Both cases occurred during vacuuming of the residual cortex from the cortex extractor. The intra-ocular lens can be placed in the ciliary sulcus.

The most significant post operative complication to occur was transient corneal edema, which developed in seven eyes (7.37%). This occurred in six out of seven eyes in the first 30 cases. However, the incidence of transient postoperative corneal edema in the Kongsap technique is no higher than those in Quarters Extraction technique (10%), Manual Multiphacofragmentation (10%), Nylon Loop technique (7.6%), or Prechop technique (8.55%)^(2,6-9). The corneal endothelial cell loss at 3 months postoperatively was 7.1%. These showed that the endothelial related complications are no higher than other techniques.

Because this technique is performed mostly in the anterior chamber, corneal endothelial damage may occur during nuclear luxation, nuclear fragmentation, and nuclear removal through the clear corneal incision. The author believes that the damage observed during the follow-up was caused due to the newness of the technique and within what could be described as the "learning curve period". Once proficiency, expertise, and knowledge were gained, corneal damage no longer occurred. Damage can be avoided if a good viscoelastic is frequently injected into the anterior chamber and the surgeon holds the nuclear supporter and the nuclear cutter still.

Patient selection is also important for surgical success. The guidelines are similar to the ones used for phacoemulsification. Nuclear hardness of +2 to +3 according to the Lens Opacities Classification System II allows easier nuclear fragmentation. The author does not recommend this technique for cataract surgery in hard cataract with a large nucleus because there is a narrow space for manipulation in the anterior chamber; thus the nucleus is hard for nuclear fragmentation and the central fragment is thick. The incision should be enlarged in order to make the nuclear removal easier and the wound to be sutured with one stitch.

In summary, manual sutureless cataract surgery with foldable intraocular lenses using the Kongsap technique when performed by an experienced surgeon was a safe procedure with good visual recovery and no need for a phaco machine. However, these results

were based on a small series with a short-term follow-up period. The author will continue to improve the surgical technique to reduce the incidence of post operative corneal edema and continue to study endothelial cell loss for one year. The comparative study between this technique and phacoemulsification is also on-going.

References

1. Minassian DC, Rosen P, Dart JK, Reidy A, Desai P, Sidhu M, et al. Extracapsular cataract extraction compared with small incision surgery by phacoemulsification: a randomised trial. *Br J Ophthalmol* 2001; 85: 822-9.
2. Akura J, Kaneda S, Ishihara M, Matsuura K. Quarters extraction technique for manual phacofragmentation(1). *J Cataract Refract Surg* 2000; 26: 1281-7.
3. Bond BF. The small incision phacosection planned extracapsular manual technique. *Highlights Ophthalmol* 1997; 25: 15-25.
4. Kansas PG, Sax R. Small incision cataract extraction and implantation surgery using a manual phacofragmentation technique. *J Cataract Refract Surg* 1988; 14: 328-30.
5. Keener GT Jr. The nucleus division technique for small incision cataract extraction. In: Rozakis GW, editor. *Cataract surgery: alternative small incision techniques*. Thorofare, NJ: Slack; 1990: 163-95.
6. Gutierrez-Carmona FJ. Manual multiphacofragmentation through a 3.2 mm clear corneal incision. *J Cataract Refract Surg* 2000; 26: 1523-8.
7. Kongsap P. Manual small incision cataract surgery: nylon loop technique. *J Prapokklao Hosp Clin Med Educ Cent* 2005; 22: 181-8.
8. Kongsap P. Cataract surgery using the Nylon loop technique. *Asian J Ophthalmol* 2006; 8: 135-8.
9. Wiriyaluppa C, Kongsap P. Visual outcome and complications of cataract surgery using prechop manual phacofragmentation: the 339 cases series. In: *Proceedings the 19th congress of Asia-pacific academy of ophthalmology*. Bangkok: Mediplus; 2004: 179-81.
10. Wiriyaluppa C, Kongsap P. Prechop manual phacofragmentation: cataract surgery without a phacoemulsification machine. *Asian J Ophthalmol* 2002; 4: 7-9.
11. Kongsap P. Sutureless ECCE with foldable IOL: the Kongsap technique. *Asian J Ophthalmol* 2006; 8: 212.

ผลการผ่าตัดต้อกระจก และใส่เลนส์แก้วตาเทียมชนิดนิ่มพับได้โดยวิธี Kongsap technique ในผู้ป่วยต้อกระจกจำนวน 95 ราย

พิพัฒน์ คงทรัพย์

วัตถุประสงค์: เพื่อประเมินผลระดับสายตา และภาวะแทรกซ้อนจากการผ่าตัดต้อกระจกและใส่เลนส์แก้วตาเทียมชนิดนิ่มพับได้โดยวิธี Kongsap technique

วิธีการศึกษา: การศึกษาไปข้างหน้า โดยไม่มีกลุ่มเปรียบเทียบ

วัสดุและวิธีการ: ผู้รายงานทำการศึกษาในผู้ป่วยจำนวน 95 รายที่มารับการผ่าตัดต้อกระจกที่โรงพยาบาลพระปกเกล้า ตั้งแต่เดือนธันวาคม พ.ศ.2548 ถึงเดือนพฤษภาคม พ.ศ. 2549 ผู้ป่วยได้รับการประเมิน ระดับสายตา, ภาวะแทรกซ้อน และการสูญเสียเซลล์กระจกตาชั้นในจากการผ่าตัด โดยนัดตรวจ 1 สัปดาห์, 1 เดือน, 3 เดือน และ 6 เดือนหลังผ่าตัด

ผลการศึกษา: ผลการผ่าตัดพบว่าระดับสายตาดีกว่าหรือเท่ากับ 20/40 จำนวน 83 ตา (87.37%), 86(90.53%), 87 ตา (91.58%) และ 85 ตา (89.48%) ที่ 1 สัปดาห์, 1 เดือน, 3 เดือน และ 6 เดือน หลังผ่าตัด ตามลำดับ ภาวะแทรกซ้อนระหว่างผ่าตัดที่พบบ่อยคือ iris prolapse (7.37%) ภาวะแทรกซ้อนอื่น ๆ ได้แก่ posterior capsule rupture, intra-cameral bleeding และ capsulorhexis tear พบ อย่างละ 2.11% ภาวะแทรกซ้อนหลังผ่าตัดที่พบบ่อย คือ corneal edema พบ 7 ตา (7.37%) ทั้งนี้ไม่พบภาวะแทรกซ้อนที่รุนแรงอื่น ๆ ในช่วง 6 เดือนหลังผ่าตัด ค่าเฉลี่ยการสูญเสียเซลล์กระจกตา เท่ากับ 5.3% ที่ 1 เดือน และ 7.1% ที่ 3 เดือนหลังผ่าตัด

สรุป: การผ่าตัดต้อกระจกและใส่เลนส์แก้วตาเทียมชนิดนิ่มพับได้โดยวิธี Kongsap technique โดยจักษุแพทย์ที่มีประสบการณ์ เป็นวิธีการผ่าตัดที่ปลอดภัยและให้ผลการมองเห็นที่รวดเร็วโดยไม่ต้องใช้เครื่องมือสลายต้อกระจก
