

# Anatomic Safe Zone for Proximal Ulnar Fixation: A Cadaver Study

Tala Thammaroj MD\*,  
Surut Jianmongkol MD\*, Kimaporn Kamanarong MD\*\*

\* Departments of Orthopedic Surgery, Khon Kaen University, Khon Kaen

\*\*Department of Anatomy, Khon Kaen University, Khon Kaen

---

**Objective:** To study the location and characterization of the safe zone with respect to bony landmarks on volar surface of proximal ulna for the protrusion of various ulnar fixations.

**Material and Method:** The present study was done on 39 upper extremities from 20 embalmed human, adult cadavers. The average ages of the cadavers were  $67.28 \pm 10.96$  years (range from 40 to 82 years), 10 females, and 29 males. The safe zone dimensions, both in coronal and sagittal planes, were measured.

**Results:** The distance between median nerve and volar surface of proximal ulna in sagittal plane at 2 cm and 4 cm distal to tip of coronoid process were  $0.99 \pm 0.15$  cm (range from 0.76-1.32 cm) and  $0.85 \pm 0.17$  cm (range from 0.64-1.75 cm), respectively. The distances between the lateral border of the proximal ulna and medial border of the median nerve in coronal plane at 2 cm and 4 cm distal to the tip of the coronoid process were  $0.95 \pm 0.19$  cm (range from 0.66-1.36 cm) and  $0.82 \pm 0.14$  cm (range from 0.52-1.14 cm), respectively.

**Conclusion:** Based on the present results, if intra-medullary screws or K-wire fixations were used, it should theoretically be long enough to reach their proximal ulna in order to bite into the cortical bone, but should not be so long as to cut out into its lateral part and, in the sagittal plane, the protrusion should not be longer than 0.92 cm. Orthopedic surgeons must remain vigilant with regard to any types of fixation in the upper extremity because the risk of neurovascular injury is high.

**Keywords:** Proximal ulna, Safe zone, Fixation, Anatomical

*J Med Assoc Thai* 2007; 90 (8): 1616-20

**Full text. e-Journal:** <http://www.medassocthai.org/journal>

---

Until now, trauma is still the major health problem. Because motor-vehicle accidents are the initial leading causes of death in Thailand and around the world, even if patients do not die they will suffer from disabilities and be a social burden. Seventy-eight percent of trauma patients have musculoskeletal injuries. Treatments of musculoskeletal trauma have to prevent not only the patient's disabilities from injuries but also the iatrogenic complications especially in the period of medical legal conundrum.

From the literature review, many iatrogenic complications have been reported<sup>(1,2)</sup>. Upper extremity fixation had higher risks when compared with lower extremity fixation because of the close proximity of

neurovascular structures to bone and less surrounding soft tissue protection. Iatrogenic complications from proximal ulnar fixation have been reported with various fixations<sup>(3-5)</sup>. If there were parts of fixation protruding through the volar surface of ulna, it had a risk for neurovascular injuries, ulnar artery, and median nerve. Although a few cases have been reported<sup>(6)</sup>, all patients suffered from severe complications and multiple operations. The purpose of the present study was aimed at delineating the location and characterization of the safe zone with respect to bony landmarks on the volar surface of the proximal ulna for the protrusion of various ulnar fixations.

## Material and Method

The present study was done on 39 upper extremities from 20 embalmed human, adult cadavers. The average ages of the cadavers were  $67.28 \pm 10.96$

---

Correspondence to : Thammaroj T, Department of Orthopedics, Faculty of Medicine, Khon Kaen University, Khon Kaen 40002, Thailand. Phone: 043-348-360 ex. 4070, Fax: 043-348-398, E-mail: tekamo@kku.ac.th

years (range from 40 to 82 years), 10 females, and 29 males. None of the specimens had any evidence of previous elbow surgery or fracture of the ulna. One specimen was excluded because of damage of neurovascular structures from previous structure. All dissections were performed in the anatomical position of the upper extremities.

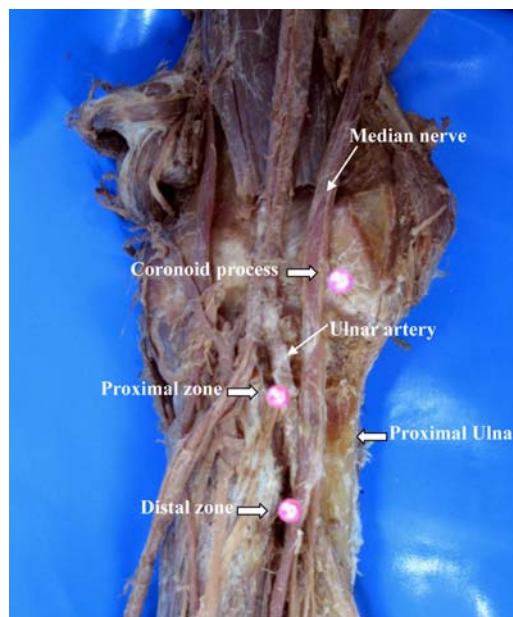
The initial dissection was carried out anteriorly to identify brachial, ulnar and radial artery that usually branched 1-2 cm. distal to the elbow joint. Median nerve usually accompanied brachial artery and ulnar artery was identified. The origin of the flexor pronator group of muscles was carefully removed from the medial epicondyle and medially retracted to identify brachial, ulnar, and radial artery and median nerve that lies on the flexor digitorum profundus muscle (Fig. 1). By using a vernier caliper, the authors measured the distance between the median nerve and volar surface of the proximal ulna at 2 cm and 4 cm distal to the tip of the coronoid process in the sagittal plane (Fig. 2). The level of proximal ulna at 2 cm distal to the tip of the coronoid process was defined as the proximal zone and the level at 4 cm distal to the tip of the coronoid process was defined as the distal zone. The next step was removal of the flexor digitorum profundus's origin from the proximal ulna to expose the volar surface of the proximal ulna then the authors measured the distance between the lateral border of the proximal ulna and the medial border of the median nerve at 2 cm and 4 cm distal to the tip of the coronoid process in the coronal plane (Fig. 3). All measurements were recorded in centimeters.

The range, mean, standard deviation (SD), and independent sample t-test was used to define the effect of sex and side to all measurements; statistical significance was determined at  $p < 0.05$ . From the SPSS software (version 11.0; SPSS, Chicago, Illinois), there was no statistical significance for all analyses.

## Results

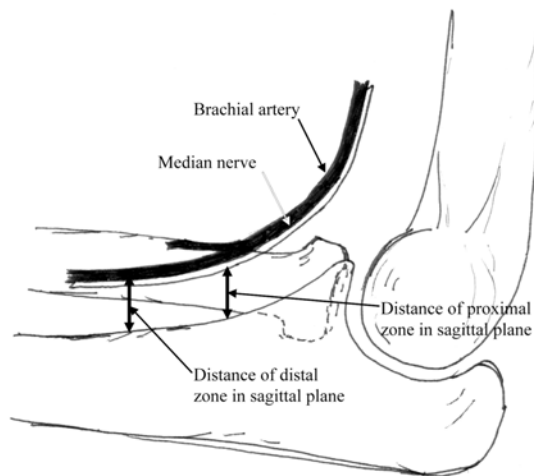
### Safe zone of proximal ulna

The distance between the median nerve and the volar surface of the proximal ulna in the sagittal plane at 2 cm and 4 cm distal to the tip of the coronoid process, the distances of the proximal and distal zone in the sagittal plane, were  $0.99 \pm 0.15$  cm (range from 0.76-1.32 cm) and  $0.85 \pm 0.17$  cm (range from 0.64-1.75 cm), respectively. The distance between the lateral border of the proximal ulna and the medial border of the median nerve in the coronal plane at 2 cm and 4 cm distal to the tip of the coronoid process, and the



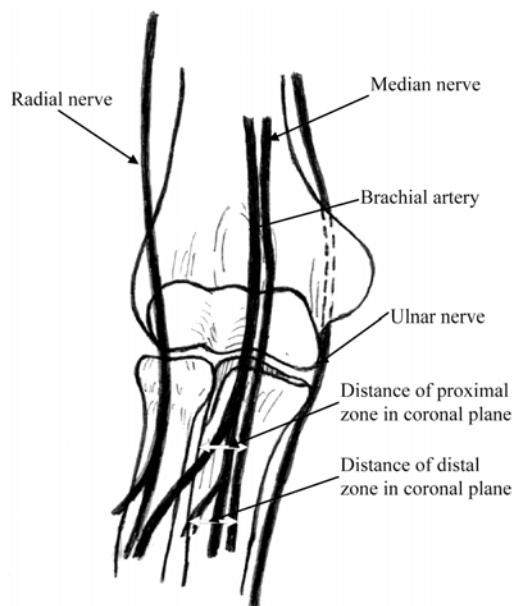
**Fig. 1** Picture of the gross specimen of the elbow shows location of median nerve and ulnar artery related to proximal ulna

Median nerve and ulnar artery pass anterior and medial to the volar cortex of proximal ulna  
The location of measurements are proximal, 2 cm from coronoid process, and distal zone, 4 cm from coronoid process (block arrow)



**Fig. 2** Schematic diagram shows median nerve and brachial artery surrounding the elbow. Median nerve and brachial artery pass anterior to the volar cortex of proximal ulna

The distances from median nerve to volar cortex of proximal ulna at proximal and distal zone were shown with thick arrows



**Fig. 3** Schematic diagram shows median, ulnar and radial nerves surrounding the elbow Median nerve and ulnar artery pass anterior to the volar cortex of proximal ulna  
The distance from lateral border of proximal ulna and medial border of median nerve at proximal and distal zone were shown with white thick arrows

distances of the proximal and the distal zone in the coronal plane, were  $0.95 \pm 0.19$  cm (range from 0.66-1.36 cm) and  $0.82 \pm 0.14$  cm (range from 0.52-1.14 cm), respectively.

#### Sex and Side variables

The distance of the proximal and distal zone in the sagittal plane of male cadavers was  $1.03 \pm 0.15$

cm and  $0.87 \pm 0.18$  cm, respectively. The distance of the proximal and distal zone in the sagittal plane of female cadavers was  $0.89 \pm 0.10$  cm and  $0.80 \pm 0.11$  cm, respectively. The distance of the proximal and distal zone in the coronal plane of the male cadavers was  $0.96 \pm 0.18$  cm and  $0.83 \pm 0.13$  cm, respectively. The distance of the proximal and distal zone in the coronal plane of the female cadavers was  $0.92 \pm 0.23$  cm and  $0.81 \pm 0.19$  cm, respectively. The side variable was delineated, by means  $\pm$  SD, as sex variable in Table 1. By using the Independence sample *t*-test, no significant differences were detected for all variables at  $p < 0.05$ .

#### Discussion

It is well accepted that a displaced fracture is still an indication for operative fixation of proximal ulna and tension-band wiring is usually the best internal fixation construct to use in these fractures<sup>(1,7,8)</sup>. Traditionally, K-wire has been used in the tension-band construct except for some large olecranon fragments, a long screw can be used in place of the K-wire. Both of them can produce iatrogenic neurovascular complications if it protruded the volar surface of the proximal ulna.

Although, complications of operative treatment of olecranon are not uncommon<sup>(3-5)</sup>, symptomatic hardware has been reported up to 80% of patients and may require removal after the fracture is solidly healed<sup>(2)</sup>. However, the neurological complications from this injury are rare. Ulnar nerve symptoms have been reported in 10% of patients<sup>(9)</sup>. To the authors' knowledge, median nerve palsy from the operative treatment of olecranon has been reported from K-wire protrusion in only one case<sup>(6)</sup>. Although median nerve palsy from the internal fixation of olecranon is rare, a missed or delayed diagnosis can be problematic in

**Table 1.** The variable factors and average distances of proximal and distal zone in all planes

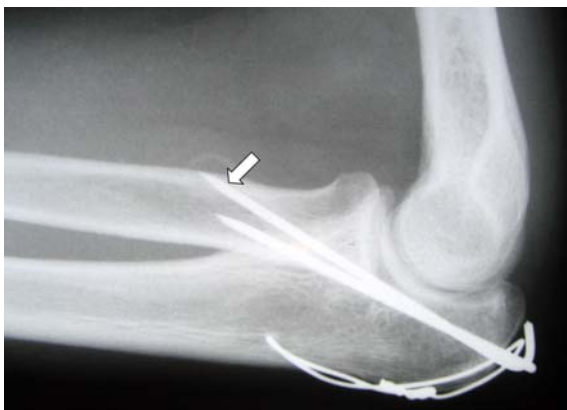Variable factors	No.	Measurement location (means $\pm$ SD) in cm			
		DPS	DDS	DPC	DDC
Male	29	$1.03 \pm 0.15$	$0.87 \pm 0.18$	$0.96 \pm 0.18$	$0.83 \pm 0.13$
Female	10	$0.89 \pm 0.10$	$0.80 \pm 0.11$	$0.92 \pm 0.23$	$0.81 \pm 0.19$
Right side	20	$0.99 \pm 0.15$	$0.85 \pm 0.17$	$0.95 \pm 0.19$	$0.83 \pm 0.15$
Left side	19	$0.99 \pm 0.16$	$0.86 \pm 0.17$	$0.95 \pm 0.20$	$0.82 \pm 0.13$

DPS, distance of proximal zone in sagittal plane  
DDS, distance of distal zone in sagittal plane  
DPC, distance of proximal zone in coronal plane  
DDC, distance of distal zone in coronal plane

that it can result not only in delayed surgical decompression but also in increasing malpractice claims. The authors cannot assure that this complication is iatrogenic or a by chance event but the modern clinical practice is further clouded by the medical/legal conundrum. While malpractice risk management is of prime importance to practicing orthopedic surgeons, few scientific data are available on strategies to reduce the risk of a malpractice claim.

Findings from dissection showed that the lateral part of the proximal ulna had a high risk for neurovascular injuries because the brachial artery branched off the radial artery laterally then continuing to be ulnar artery on the volar surface of the proximal ulna. Median nerve accompanied the brachial artery then the ulnar artery and lies laterally beside them. The distance measured between the lateral border of the ulna to the medial border of the median nerve including all important structures, brachial artery, and median nerve. The measurements in the sagittal plane were measure from the median nerve to the volar surface of the ulna, which usually results from the thickness of muscle mass of the flexor digitorum profundus.

From the present study, the suggested safe zone, when the internal fixations, both K-wire and screws, protruded through the volar cortex of proximal ulna were the medial part of the proximal ulna around 0.88 cm from the medial border of the proximal ulna in the coronal plane and 0.92 cm in the sagittal plane, even so the length of the instrument should not protrude more than 0.92 cm beyond the volar cortex of the proximal ulna (Fig. 4). This safe zone is naturally devoid of important structures, the brachial artery and



**Fig. 4** Plain radiograph show the protrusion of K-wires through the volar cortex of ulna (arrow) causing the median nerve injury

median nerve, and only muscle mass of the flexor digitorum profundus left in this area, so the protrusions of any fixations through the volar cortex of the proximal ulna will not cause any complications. However, the implication of data from the present study should be carefully used because the measurements from the X-ray image have some magnification, usually 10-15% of real measurement.

In conclusion, while neurovascular injuries from K-wire protrusion of operative treatment of an olecranon fracture are uncommon on a per person basis, these may result in serious complications for the patient, such as nerve palsy or limb ischemia. Orthopedic surgeons must remain vigilant with regard to any types of fixation in the upper extremity because the risk of neurovascular injury is high. If intra-medullary screws or K-wire fixations are used, they should theoretically be long enough to reach their proximal ulna in order to bite into the cortical bone, but should not be so long as to cut out into its lateral part and, in the sagittal plane, the protrusion should not be longer than 0.92 cm.

## References

1. Mezera K, Hotchkin RN. Fractures and dislocations of the elbow. In: Bucholz RW, Heckman JD, editors. Rockwood and Green's fracture in adults. 5<sup>th</sup> ed. Philadelphia: Lippincott-Raven publishers; 2001: 921-52.
2. Matthewson MH, McCreath SW. Tension band wiring in the treatment of olecranon fractures. *J Bone Joint Surg* 1975; 57B: 399.
3. Finalyson D. Complications of tension-band wiring of olecranon fracture [letter]. *J Bone Joint Surg* 1986; 68A: 951-2.
4. Rowland SA, Burkhalter SS. Tension band wiring of olecranon fracture-a modification of the AO technique. *Clin Orthop* 1992; 227: 238-42.
5. Wolfgang G, Burke F, Bush D, Parenti J, Perry J, LaFollette B, et al. Surgical treatment of displaced olecranon fractures by tension band wiring technique. *Clin Orthop* 1987; 224: 192-204.
6. Thumroj E, Jianmongkol S, Thammaroj J. Median nerve palsy after operative treatment of olecranon fracture. *J Med Assoc Thai* 2005; 88: 1434-7.
7. Fyfe IS, Mossad MM, Holdsworth BJ. Methods of fixation of olecranon fractures. An experimental mechanical study. *J Bone Joint Surg Br* 1985; 67: 367-72.
8. Petraco DM, Koval FJ, Kummer FJ, Zuckerman JD. Fixation stability of olecranon osteotomies. *Clin*

---

## การศึกษาบริเวณปลอกดักยสำหรับการยึดตรึงกระดูกอัลนาส่วนต้นในศพดอง

ธรา ธรรมโรจน์, สุรัตน์ เจียรณมงคล, กิมาพร ชมะณะรงค์

**วัตถุประสงค์:** เพื่อศึกษาลักษณะและตำแหน่งบริเวณปลอกดักยของกระดูกอัลนาส่วนต้นด้านท้องแขนในการยึดตรึงกระดูกถ้ามีส่วนของวัสดุยึดตรึงยื่นออกมา

**วัสดุและวิธีการ:** การศึกษานี้ทำในศพดองของผู้ใหญ่ทั้งหมด 20 ตัวอย่าง 39 รยางค์บน อายุเฉลี่ยของศพดอง คือ 67.28 ปี (ช่วงระหว่าง 40-82 ปี) โดยมีรยางค์บนของเพศหญิง 10 รยางค์ และ เพศชาย 29 รยางค์ โดยได้ทำการบันทึกตำแหน่งของบริเวณปลอกดักยในระนาบซ้ายขวา และระนาบหน้าหลัง

**ผลการศึกษา:** ระยะจากเส้นประสาทมีเดียขึ้นไปยังปลอกกระดูกอัลนาด้านท้องแขนในระนาบหน้าหลังที่ระยะ 2 และ 4 ซม. จากส่วนยื่นโคโรนอยด์เท่ากับ  $0.99 \pm 0.15$  ซม. (ช่วงระหว่าง 0.76-1.32 ซม.) และ  $0.85 \pm 0.17$  ซม. (ช่วงระหว่าง 0.64-1.75 ซม.) ตามลำดับ ระยะระหว่างขอบนอกของกระดูกอัลนาส่วนต้นถึงขอบในของเส้นประสาทมีเดียที่ระยะ 2 และ 4 ซม. จากส่วนยื่นโคโรนอยด์ เท่ากับ  $0.95 \pm 0.19$  ซม. (ช่วงระหว่าง 0.66-1.36 ซม.) และ  $0.82 \pm 0.14$  ซม. (ช่วงระหว่าง 0.52-1.14 ซม.) ตามลำดับ

**สรุป:** จากผลการศึกษาพบว่าถ้ามีการใช้วัสดุยึดตรึงไม่ว่าจะเป็นลวดยึดตรึงกระดูกหรือตาปูควง ควรจะให้วัสดุยึดตรึงยาวพอถึงกระดูกเปลือก แต่ไม่ควรให้มีส่วนของวัสดุยึดตรึงทะลุเลยขอบกระดูกอัลนาด้านท้องแขนเกินกว่า 0.92 ซม. โดยเฉลี่ยเพราะอาจทำให้เกิดความเสี่ยงที่จะเกิดภัยอันตรายต่อเส้นเลือดเส้นประสาทสูง ซึ่งเป็นเรื่องที่ศัลยแพทย์ออร์โธปิดิกส์ควรจะต้องระมัดระวังอย่างมาก