

# The Results of Percutaneous Release of Trigger Digits by Using Full Handle Knife 15°: An Anatomical Hand Surface Landmark and Clinical Study<sup>†</sup>

Yolchai Jongjirasiri MD\*

<sup>†</sup> This paper was presented at The 6<sup>th</sup> Congress of the Asian Pacific Federation of Societies for Surgery of the Hand. On 18 November 2006 Shangri-La Hotel, Bangkok, Thailand

\* Department of Orthopedic Surgery, Bangkok Metropolitan Administration General Hospital

**Objective:** Know the results of percutaneous release of trigger digits by using full handle knife 15°.

**Material and Method:** The author identified 510 cadaveric digits to find the anatomical landmark of A1 pulley that relates to the knuckle and measurements of A1 pulley lengths. The proximal margin of the A1 pulleys on the perpendicular line from the knuckle to the palm was in the same line in 327 (64.1%) digits, while 464 (91.0%) digits were  $\leq 1$  mm and 509 (99.8%) were  $\leq 2$  mm. The average lengths of A1 pulleys in each digit were as follows: thumb; 5.30, index finger; 6.32, middle finger; 6.58, ring finger; 6.32, and little finger 5.30 mm. The average lengths of all fingers were 6.13 mm. A further 338 digits of trigger digit in 248 patients were treated by percutaneous release by using full handle knife 15° with these landmarks.

**Results:** Three hundred and thirty-eight trigger digits were treated. There was a complete resolution of symptoms in 314 digits (92.90%) when followed up 6 weeks after operation. One digit, an index finger had residual grade 1 after 3 weeks and complete resolution in 8 weeks. Three digits (0.89%), which were one thumb and two index fingers, underwent local steroid injection because of painful scar. Nineteen digits (5.62%) were stiff at proximal interphalangeal joint because of grade 4 triggering and osteoarthritis of the proximal interphalangeal joint but they increased the range of motion after 6 months. A case (0.30%) had numbness of the radial tip of the thumb, which may have been caused by injury to the radial digital nerve of the thumb. No one had open release of A1 pulley.

**Conclusion:** This technique was a safe and effective out patient procedure on 248 patients and had a complete resolution of symptoms 92.90%

**Keywords:** Trigger finger, Percutaneous release, Landmark, A1 pulley, Result

*J Med Assoc Thai* 2007; 90 (7): 1348-55

**Full text. e-Journal:** <http://www.medassocthai.org/journal>

Trigger finger or trigger thumb is common and treatment by local steroid injection is often recommended<sup>(1-15)</sup>. The success rate varies from 38% to 95%<sup>(3,4,7,8,10-16)</sup>. Although simple and low with morbidity, this has a high rate of recurrence and repeated injections may be required<sup>(2,3,5-15)</sup>. When conservative treatment fails, open release of the A1 pulley is usually recommended<sup>(1-3,7,9,16-19)</sup>. Lorthioir<sup>(20)</sup> first described a technique of percutaneous release by using a fine

tenotome. After that, there were several methods and using various instruments, have been reported with satisfactory results and few complications<sup>(1-3,7,16-18,20)</sup>. Knowledge of the location of the A1 pulley edges can facilitate safer release of the A1 pulley<sup>(1-3,20,21)</sup>. A1 pulley starts 2 mm proximal to the metacarpophalangeal joint<sup>(22)</sup>. Furthermore, the developing of a surface landmark to more consistently identify the location and reliability of percutaneous techniques of trigger digit release<sup>(1,2,7,9,16)</sup>.

The purpose of the present study was 2- fold; first, to identify hand surface landmark by measuring the length of A1 pulley and landmark of proximal edge

Correspondence to : Jongjirasiri Y, Department of Orthopaedic Surgery, Bangkok Metropolitan Administration General Hospital, 514 Laung Rd, Pomprabsatropai, Bangkok 10100, Thailand. E-mail: yolchai@hotmail.com

of A1 pulley which relates to knuckle line in a perpendicular line to the palm of its finger and thumb of cadaver dissections and second, describes the results of percutaneous trigger digit release by using full handle knife 15°.

### Material and Method

An anatomic study of a total of 510 cadaveric fingers and thumbs were dissected in 51 preserved cadavers. There were 25 females and 26 males whose ages at the time of death ranged from 48 to 89 years. On dissection, the pulleys were identified, and A1 pulley lengths of fingers and thumbs were measured with a 4X loupe using a caliper by one orthopedic surgeon. Also measurements of proximal A1 pulley margins in relation to the central tip of knuckle, which lines up perpendicular to palm were measured. The distance from the proximal edge of A1 pulley to the perpendicular line from the knuckle to the palm of each finger and thumb was measured, by using a large reduction. One point was fixed to the center of the knuckle gripped over the palm and the other to the flexor tendon while the hand was placed over the table with both the shaft and the handle of reduction with point perpendicular to the palm. Each distance was measured twice (Fig. 1).

In each of these 510 cadaveric fingers and thumbs dissections, the A1 pulley originated from the volar plate of the metacarpophalangeal joint. The margin from the proximal edge of A1 pulley to the perpendicular line from the knuckle to the palm was in the same line in 327 (64.1%) fingers and thumbs. There were 464 (91.0%) different fingers and thumbs  $\leq 1$  mm and 509 (99.8%)  $< 2$  mm. The overall mean difference was  $0.37 \pm 0.55$  mm. The margin from the proximal edge of A1 pulley of thumb, index, middle, ring, and little fingers were 65.7%, 57.85%, 60.80%, 67.65%, and 68.60% respectively to the same line in the perpendicular line from the knuckle to the palm. The thumb, index, middle, ring, and little fingers were 93.10%, 89.20%,

88.2%, 92.2%, and 92.2%, the differences were  $\leq 1$  mm to the line in the perpendicular line from the knuckle to the palm.

The length of A1 pulley averaged  $5.30 \pm 0.53$  mm for thumb,  $6.32 \pm 0.17$  mm for index,  $6.58 \pm 0.19$  mm for middle,  $6.32 \pm 0.19$  mm for ring, and  $5.30 \pm 0.49$  mm for small finger whereas the A1 pulley of small fingers were not significantly shorter ( $p > 0.05$ ) than the length of the A1 pulley for the index, middle, and ring fingers with a 95% confidence interval (Table 1-2).

Thereafter, between 1 January 2003 and 31 January 2006, 248 patients (338 digits with 297 visits) were clinically treated to release trigger digits. Hand surface landmark were used. All the procedures were done by one surgeon in the office. Two hundred and two patients were done in one visit, forty-three were done with two visits, and three were done with three visits. Two hundred and sixty-one patients were done on one digit, 31 were done on two digits, and five were done on three digits. There were 238 women and 59 men with a mean age of 57.5 years (26 to 88). In 338 digits, 69 (20.4%) were trigger thumb, 44 (13.0%) trigger index finger, 135 (39.9%) trigger middle finger, 85 (25.1%) trigger ring finger, and 5 (1.5%) were little finger.

The 338 digits were graded according to the severity of symptoms similar to that suggested by other authors. In grade 1, there were no triggering, but uneven finger movements. In grade 2, triggering was actively correctable. In grade 3, it was usually correctable by the other hand, and in grade 4 the digit was locked. There were four (1.2%) digits as grade 1, 50 (14.8%) digits as grade 2, 147 (43.5%) digits as grade 3 and 137 (40.5%) digits as grade 4. Of the grade 4, 49 were locked in flexion and 88 in extension (Table 3).

Of 297 visits, 78 (26.3%) were related to other conditions such as diabetes, hypertension, hyperlipidemia, gout, and a case with tendon sheath ganglion. The other 219 (73.7%) were not related to anything.



**Fig. 1** Landmarks for measurements of proximal A1 pulley margins with relation to the central tip of knuckle which lined up perpendicular to palm (A)  
The distance from the proximal edge of the A1 pulley (B) to the perpendicular line from the knuckle to the palm of each fingers (left) and thumbs (right) was measured

**Table 1.** Measurements of the distance from the proximal edge of the A1 pulley to the perpendicular line from the knuckle to the palm of each finger and thumb in 510 digits

Digit	Same line (digit)	%	≤ 1 mm (digit)	%	≤ 2 mm (digit)	%
Thumb	67	65.70	95	93.10	102	100
Index	59	57.80	91	89.20	102	100
Middle	62	60.80	90	88.20	102	100
Ring	69	67.60	94	92.20	102	100
Little	70	68.60	94	92.20	101	99.0
Average of all digits	327	64.10	464	91.00	509	99.8

**Table 2.** The length of A1 pulleys of 51 cadaveric digits

Digit	Length of A1 pulley (mm)	Maximum	Minimum	Mean
Thumb	4.4	6.50	5.30	0.53
Index	6.0	6.75	6.32	0.17
Middle	6.0	7.00	6.58	0.19
Ring	6.0	6.80	6.32	0.20
Little	4.1	6.40	5.30	0.49
Average of all digits	5.8	6.46	6.13	0.17

**Table 3.** Grading of trigger digits of 248 patients 338 digits

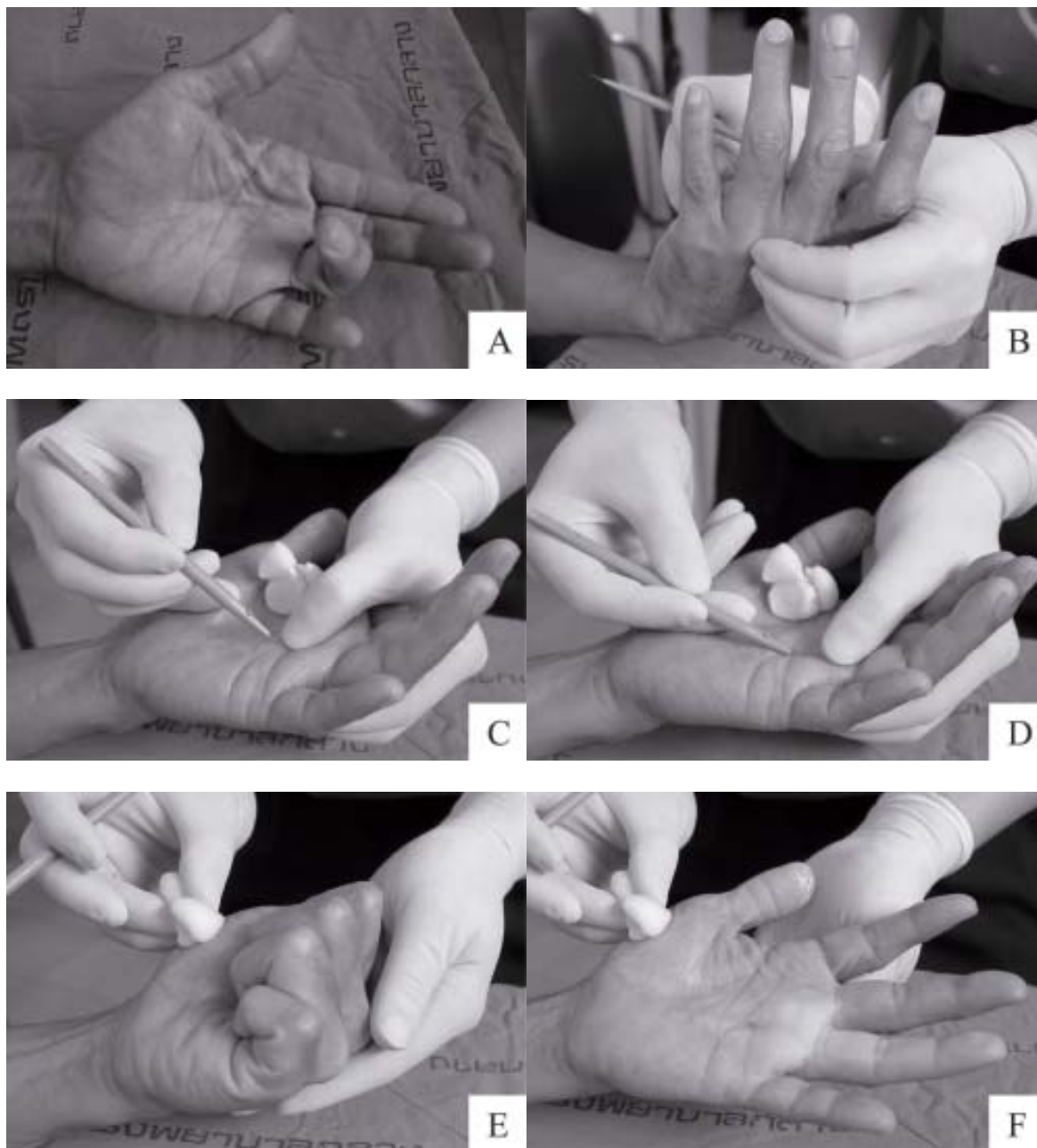
Grade	thumb	index	middle	ring	little	Total
1	-	-	3	-	1	4 (1.2%)
2	23	6	14	6	1	50 (14.8%)
3	15	19	67	43	3	147 (43.5%)
4	31	19	51	36	-	137 (40.5%)
Total	69 (20.4%)	44 (13.0%)	135 (39.9%)	85 (25.1%)	5 (1.5%)	338 (100%)

The procedure was done in the office under local anesthesia with 2% lidocain with adrenalin 2 cc, waiting about 10 minutes. The patients scrubbed the hand by themselves with betadine scrub, lay down on the bed, and placed the hand on the examining table. Thereafter, 70% alcohol or betadine paint was used to disinfect the skin. Once the hand was relaxed, test triggering of digit was done before the operation. The surgeon inserted the tip of the full handle knife 15°, (Fig. 2)



**Fig. 2** The picture of full handle knife 15° or ophthalmic knife

slope 45° to the palm, 2 mm proximal to the point that was perpendicular from the knuckle to the palm of each finger and thumb until the blade goes beneath the skin. The bevel of the knife was placed at 30° to the palm. The tip of the knife was pressed down to divide the step from the stoma of A1 pulley. It was then moved from proximal to distal and from superficial to over the A1 pulley. Grating sensation and sound indicated the cutting of the A1 pulley. When the grating sensation and sound stopped, the knife was withdrawn. The procedure was repeated until relief of clicking was confirmed by the patients flexing and extending the digit. If not, re-insertment of the full handle knife 15°, 5 mm distal or 3 mm proximal to the first penetration and additional release was performed (Fig. 3). For the operation of the thumb, the positioning of the thumb was in



**Fig. 3** (A) Technique of percutaneous A1 pulley release of ring finger Grade 3 of trigger finger  
 (B) Landmark from knuckle of ring finger perpendicular line to the palm will be the landmark of proximal margin of A1 pulley  
 (C) Insert tip of full handle knife 15°, slope 45° to the palm, 2 mm proximal to the point which perpendicular line from the knuckle to the palm  
 (D) The bevel of the knife was placed 30° to the palm the tip of the knife is pressed down to divide the step off the stoma of A1 pulley  
 (E) Grating sensation and sound stopped, the knife was withdrawn the procedure was repeated until relief of clicking was confirmed by the patients flexed  
 (F) Extended the digit

palmar abduction and flexing the wrist, the volar surface of the thumb was placed facing the surgeon. Using the same techniques as above, clinical release was defined as the relief of active triggering immediately after percutaneous release.

After surgery, an elastic bandage was applied for 4 days and the patients were advised to flex vigorously and extend the digit several times a day. The patients should assist full flexion and extension of the digit and massage around the penetrated skin with the opposite hand. The patients were examined once a week for 3 weeks, then every month for 6 months, and were reached by phone to determine if they had any symptom. The follow-up period ranged from three weeks to sixteen months (average seven months).

All cases were done by one surgeon in the office, between January 1, 2003 and January 31, 2006. The results were classified as satisfactory if the treated digit had no triggering and was comfortable, and as unsatisfactory if there was persistent discomfort or if local steroid injection or if open surgery had been required.

#### **Statistical analysis**

The results were presented with number, percent, average, mean, standard deviation (SD), and range. The significance was set up at  $p < 0.05$ .

#### **Results**

Of the 338 trigger digits that were treated, there was complete resolution of symptoms in 314 digits (92.90%) when followed up 6 weeks after operation. One digit, an index finger, had residual grade 1 after 3 weeks and resolved in 8 weeks, three digits (0.89%), which were 1 thumb and 2 index fingers, underwent local steroid injection because of painful scar, and 19 digits (5.62%) were stiff of proximal interphalangeal joint because of grade 4 triggering and osteoarthritis of the proximal interphalangeal joint, but they increased their range of motion after 6 months. A case (0.30%) had numbness of the radial tip of the thumb, which may be caused by injury to the radial digital nerve of the thumb. No one had open release of A1 pulley.

Significant complication, such as tear tendon, tendon bowstring due to excessive flexor tendon sheath release, infection, painful neuroma, and reflex sympathetic dystrophy were not encountered.

#### **Discussion**

The decision how to treat trigger digit is often based on personal experience rather than on scientific

fact. Up to 29% of patients may resolve the problem spontaneously. Because of the cost effectiveness and lack of complication, patients prefer to use steroid injection rather than surgery. Quinnell<sup>(10)</sup> reported a cure rate of 38% at 1 year, with a further 10% of the treated digits being improved. Rhoades et al<sup>(11)</sup> injected and used local anesthetic and combined this with 3 weeks of splint. Their cure rate was 64%, and 72% of their patients were satisfied, although a second injection was required. With a history of symptoms less than 4 months, the success rate is higher, with 93% satisfactory results. If there is a long history of symptoms, the success rate was only 41%<sup>(20)</sup>. Kolind-Sorensen<sup>(13)</sup> reported a success rate of 67% after a single injection and found that the success rate was lower when trigger digit was associated with other conditions such as rheumatoid arthritis and diabetes mellitus. In the present study, one quarter were related to other conditions. With careful attention of the injection technique, a success rate of 84%<sup>(14)</sup> and 79%<sup>(17)</sup> can be achieved after a single injection.

The author's technique of percutaneous release was done in the office and was convenient. Three hundred and fourteen of the 338 digits (92.90%) had complete relief of symptoms in 6 weeks.

Percutaneous technique to release A1 pulley has various techniques such as instruments, landmark, and technique. The oblique course of the flexor sheath and neurovascular bundles can be difficult to predict for the index and small fingers and prone to injury. The author had no difficulties when releasing the A1 pulley in the thumb, and the little and index finger. Pope and Wolfe<sup>(17)</sup> did not perform percutaneous release in the index finger. Bain et al<sup>(16)</sup> reported the same problem for the little finger. Longitudinal line of flexor tendon for index and little finger<sup>(9)</sup> and knuckle landmarks can be used to more accurate and efficiently manage percutaneous release. At the level of metacarpophalangeal joint of thumb, radial digital nerve were placed 2.19 mm beneath the dermis and 1.15mm directly anterior to the radial sesamoid bone. In this position, the nerve is vulnerable to injury by the knife blade<sup>(23)</sup>. Therefore, the surgeon should know the landmark of A1 pulley, tendons lining, and boundary A1 pulley exactly, especially the digital nerve of the thumb. One case in the present study had numbness of the radial tip of thumb that may be caused by injury to the radial digital nerve of the thumb. The patient refused the operation to repair the nerve.

Short-term stenosing tenosynovitis in any digit is probably best treated by steroid injection. In

the present study, only 1.2% grade 1 was done by percutaneous technique. This is because they had the other finger done before, thus, accepted this technique. However, when injection therapy does not succeed, percutaneous or open release is the best treatment.

To avoid a potentially painful scar at the palmar incision, percutaneous release of A1 pulley should be done gently and the surgeon should know the landmark of the A1 pulley. It is cost-effective because it can be performed in the office.

Tanaka<sup>(24)</sup> et al used a fine scalpel blade and Lyu<sup>(25)</sup> used a curved scalpel blade to perform percutaneous release and reported an excellent result. Eastwood<sup>(3)</sup> et al, Stothard and Kumar<sup>(26)</sup>, Patel and Moradia<sup>(8)</sup>, Bain et al<sup>(16)</sup>, and Pope and Wolfe<sup>(17)</sup> described excellent results by using a needle for percutaneous release. The studies described techniques that rely on skin creases to locate the A1 pulley. However, subtle variations in these skin creases can contribute to surgical error. In general, potential complications of percutaneous A1 pulley release include incomplete release, digital nerve injury, flexor tendon injury, and volar plate injury. Incomplete release of the distal pulley has been described to occur frequently, but it does not result in persistent or recurrent triggering because the proximal part is a more significant contributor to the triggering. Using the C0 line or 5 mm. proximal to locate the palmar digital crease<sup>(1)</sup> for distal release could facilitate complete A1 pulley release. Several studies report a high percentage of flexor tendon injuries with percutaneous release. However, there are no reports that this injury is significant enough to require flexor tendon repair.

In the author's experience with the release of the A1 pulley, using the tip of a 20 gauge needle at 1.5 inch successfully divided the A1 pulley 10 to 20 times and was non traumatic to the flexor tendon. As the author thought that the tip of the needle could not easily release the percutaneous, it was decided to use full handle knife 15, which is used in eye operations and has sharpness to cut the A1 pulley. While releasing the pulley, the author used the tip of the knife pressed down to divide the step off the stoma of the A1 pulley. It was then moved from proximal to distal and from superficial to over the A1 pulley. This technique should not injure the flexor tendon and volar plate.

After injecting the anesthesia, the triggering of the digit may decrease one grade, thus, from grade 4 will be grade 3 and can be done in the flexion stage. The finger should extend spontaneously after the com-

plete release of the A1 pulley. The grating sensation and sound should stop after the tip of the knife is pressed down to divide the step from the stoma of the A1 pulley. Triggering of the finger is an important sign to know that the percutaneous release has been completed.

## References

1. Wilhelmi BJ, Snyder N, Verbesey JE, Ganchi PA, Lee WP. Trigger finger release with hand surface landmark ratios: an anatomic and clinical study. *Plast Reconstr Surg* 2001; 108: 908-15.
2. Ha KI, Park MJ, Ha CW. Percutaneous release of trigger digits. *J Bone Joint Surg Br* 2001; 83: 75-7.
3. Eastwood DM, Gupta KJ, Johnson DP. Percutaneous release of the trigger finger: an office procedure. *J Hand Surg [Am]* 1992; 17: 114-7.
4. Lambert MA, Morton RJ, Sloan JP. Controlled study of the use of local steroid injection in the treatment of trigger finger and thumb. *J Hand Surg [Br]* 1992; 17: 69-70.
5. Clark DD, Ricker JH, MacCollum MS. The efficacy of local steroid injection in the treatment of stenosing tenosynovitis. *Plast Reconstr Surg* 1973; 51: 179-80.
6. Patel MR, Bassini L. Trigger fingers and thumb: when to splint, inject, or operate. *J Hand Surg [Am]* 1992; 17: 110-3.
7. Dunn MJ, Pess GM. Percutaneous trigger finger release: a comparison of a new push knife and a 19-gauge needle in a cadaveric model. *J Hand Surg [Am]* 1999; 24: 860-5.
8. Patel MR, Moradia VJ. Percutaneous release of trigger digit with and without cortisone injection. *J Hand Surg [Am]* 1997; 22: 150-5.
9. Wilhelmi BJ, Mowlavi A, Neumeister MW, Bueno R, Lee WP. Safe treatment of trigger finger with longitudinal and transverse landmarks: an anatomic study of the border fingers for percutaneous release. *Plast Reconstr Surg* 2003; 112: 993-9.
10. Quinnell RC. Conservative management of trigger finger. *Practitioner* 1980; 224: 187-90.
11. Rhoades CE, Gelberman RH, Manjarris JF. Stenosing tenosynovitis of the fingers and thumb. Results of a prospective trial of steroid injection and splinting. *Clin Orthop Relat Res* 1984; 190: 236-8.
12. Kamhin M, Engel J, Heim M. The fate of injected trigger fingers. *Hand* 1983; 15: 218-20.
13. Kolind-Sorensen V. Treatment of trigger fingers. *Acta Orthop Scand* 1970; 41: 428-32.
14. Marks MR, Gunther SF. Efficacy of cortisone

- injection in treatment of trigger fingers and thumbs. *J Hand Surg [Am]* 1989; 14: 722-7.
15. Freiberg A, Mulholland RS, Levine R. Nonoperative treatment of trigger fingers and thumbs. *J Hand Surg [Am]* 1989; 14: 553-8.
  16. Bain GI, Turnbull J, Charles MN, Roth JH, Richards RS. Percutaneous A1 pulley release: a cadaveric study. *J Hand Surg [Am]* 1995; 20: 781-4.
  17. Pope DF, Wolfe SW. Safety and efficacy of percutaneous trigger finger release. *J Hand Surg [Am]* 1995; 20: 280-3.
  18. Cihantimur B, Akin S, Ozcan M. Percutaneous treatment of trigger finger. 34 fingers followed 0.5-2 years. *Acta Orthop Scand* 1998; 69: 167-8.
  19. Stefanich RJ, Peimer CA. Longitudinal incision for trigger finger release. *J Hand Surg [Am]* 1989; 14: 316-7.
  20. Lorthioir J Jr. Surgical treatment of trigger-finger by a subcutaneous method. *J Bone Joint Surg Am* 1958; 40-A: 793-5.
  21. Jones MM, Amis AA. The fibrous flexor sheaths of the fingers. *J Anat* 1988; 156: 185-96.
  22. Strauch B, de Moura W. Digital flexor tendon sheath: an anatomic study. *J Hand Surg [Am]* 1985; 10: 785-9.
  23. Carrozzella J, Stern PJ, Von Kuster LC. Transection of radial digital nerve of the thumb during trigger release. *J Hand Surg [Am]* 1989; 14: 198-200.
  24. Tanaka J, Muraji M, Negoro H, Yamashita H, Nakano T, Nakano K. Subcutaneous release of trigger thumb and fingers in 210 fingers. *J Hand Surg [Br]* 1990; 15: 463-5.
  25. Lyu SR. Closed division of the flexor tendon sheath for trigger finger. *J Bone Joint Surg Br* 1992; 74: 418-20.
  26. Stothard J, Kumar A. A safe percutaneous procedure for trigger finger release. *J R Coll Surg Edinb* 1994; 39: 116-7.

---

## ผลการรักษาเนื้องอกด้วยวิธีเจาะผ่านผิวหนังโดยใช้มีดปลายแหลม 15 องศา พร้อมด้ามโดยใช้ตำแหน่งบนฝ่ามือเป็นจุดเจาะผ่านผิวหนัง

ยลชัย จงจิระศิริ

**วัตถุประสงค์:** ต้องการทราบผลการรักษาเนื้องอกด้วยวิธีการเจาะผ่านผิวหนังโดยใช้มีดปลายแหลม 15 องศา  
**วัสดุและวิธีการ:** ผู้รายงานได้หาตำแหน่งของปลอกหุ้มเอ็นเอ1 จาก 510 นิ้ว พบว่าอยู่ตำแหน่งเดียวกับปุ่มกระดูกหลังมือที่ลากมาตั้งฉากมาจากฝ่ามือ 327 นิ้ว (ร้อยละ 64.1) ที่ความผิดพลาดไม่เกินหรือเท่ากับ 1 และ 2 มิลลิเมตรเท่ากับ 464 นิ้ว (ร้อยละ 91.0) และ 509 นิ้ว (ร้อยละ 99.8) ตามลำดับ และความยาวของปลอกหุ้มเอ็นเอ1 เฉลี่ย นิ้วหัวแม่มือ นิ้วชี้ นิ้วกลาง นิ้วนาง และนิ้วก้อย เท่ากับ 5.30, 6.32, 6.58, 6.32 และ 5.30 มิลลิเมตรตามลำดับ ผู้รายงานได้รักษาผู้ป่วย 248 ราย ที่เป็นเนื้องอก 338 นิ้วด้วยวิธีการเจาะผ่านผิวหนังโดยใช้มีดปลายแหลม 15 องศา และใช้ตำแหน่งปุ่มกระดูกหลังมือที่ลากมาตั้งฉากมาจากฝ่ามือเป็นจุดที่เจาะ

**ผลการศึกษา:** หายจากอาการเนื้องอก 314 นิ้ว (ร้อยละ 92.90) ภายใน 6 สัปดาห์หลังจากผ่าตัด มีอาการเนื้องอกของนิ้วชี้ 1 นิ้ว (ร้อยละ 0.30) ในระดับ 1 และหายหลังจากผ่าตัด 8 สัปดาห์ มีอาการปวดบาดแผลบริเวณที่เจาะผ่านผิวหนังของฝ่ามือมี 3 นิ้ว (ร้อยละ 0.89) คือ นิ้วหัวแม่มือ 1 นิ้ว นิ้วชี้ 2 นิ้ว ผู้ป่วยได้รับการฉีดยาสเตียรอยด์เฉพาะที่ อาการดีขึ้น 19 นิ้ว (ร้อยละ 5.62) มีอาการข้อนิ้วตึงยึดของ ข้อนิ้วมือส่วนต้น เนื่องจากเนื้องอกก่อนผ่าตัดอยู่ในระดับ 4 และข้อเสื่อมของข้อนิ้ว มือ และสามารถเพิ่มการเคลื่อนไหวของข้อนิ้วได้ดีขึ้น หลังจากผ่าตัด 6 เดือน นิ้วหัวแม่มือ 1 นิ้ว มีอาการชาบริเวณปลายนิ้ว ด้านเรเดียล ซึ่งอาจเกิดจากการได้รับบาดเจ็บจากการผ่าตัด ไม่มีผู้ป่วยรายใดได้รับการเปิดบาดแผลผ่าตัดเพื่อคลายปลอกหุ้มเอ็นเอ1

**สรุป:** ผู้รายงานแนะนำให้ใช้วิธีนี้ในการรักษาเนื้องอกเนื่องจากปลอดภัย ประหยัดค่าใช้จ่าย และสามารถทำที่ห้องตรวจผู้ป่วยนอกได้

---