

Preliminary Report

Diagnostic Accuracy of MRI/MRSI for Patients with Persistently High PSA Levels and Negative TRUS-Guided Biopsy Results

Cathleeyakorn Bhatia MD*,
Sith Phongkitkarun MD*, Dechaphol Booranapitaksonti MD**,
Wachira Kochakarn MD**, Panas Chaleumsanyakorn MD***

* Department of Radiology, Faculty of Medicine, Ramathibodi Hospital, Mahidol University

** Department of Surgery, Faculty of Medicine, Ramathibodi Hospital, Mahidol University

*** Department of Pathology, Faculty of Medicine, Ramathibodi Hospital, Mahidol University

Objective: To prospectively evaluate the accuracy of transrectal ultrasonographic (TRUS)-guided biopsies by using combined magnetic resonance imaging (MRI) and magnetic resonance spectroscopic imaging (MRSI) in patients with persistently high prostate-specific antigen (PSA) levels and negative TRUS-guided biopsy results.

Material and Method: Twenty-one patients (age range 50-77 years, average 61.4 years) with negative TRUS biopsy were enrolled. Suspicious areas were identified by discrete low signal intensity in T2 on standard MRI. MRSI was interpreted by using spectral approach and given score of 1 (benign) to 5 (malignant). Suspicious voxels were localized for guided TRUS biopsy. All patients underwent sextant TRUS biopsies with up to four additional biopsies targeted at suspicious sites. Diagnostic accuracy of MRI/MRSI in patient-by-patient and voxel-by-core were analyzed.

Results: Prostate cancer was detected in 2 of 21 patients (9.5%). The sensitivity, specificity, PPV, NPV, and accuracy of combined MRI/ MRSI for detection of prostate cancer were 100%, 84%, 40%, 100%, and 86%, respectively. The site of positive biopsy correlated correctly with voxels were 80%, 85%, 21%, 99% and 85% on sensitivity, specificity, PPV, NPV and accuracy, respectively.

Conclusion: MRI/ MRSI have the potential to guide biopsy to cancer foci in patients with persistently high PSA levels and prior negative TRUS biopsy results.

Keywords: Prostate cancer, Magnetic resonance imaging, Spectroscopic imaging, Transrectal ultrasonography

J Med Assoc Thai 2007; 90 (7): 1391-9

Full text. e-Journal: <http://www.medassocthai.org/journal>

Prostate cancer is the fifth common malignancy in Thai males (4.8%) in 1996 and is the fourth common malignancy in Ramathibodi Hospital (6.2%) in 2004^(1,2). Prostate cancer is second only to lung cancer for male cancer mortality. The American Urological Association and the American Cancer Society recommend that men aged 50 years or older should undergo an annual digital rectal examination (DRE) combined

with prostate-specific antigen (PSA) level testing. Patients with a PSA level higher than 4 ng/mL should undergo transrectal ultrasonographic (TRUS) biopsy for histological confirmation of prostate cancer⁽³⁾. Although PSA is the indicator in the early detection of prostate cancer, there are several causes of PSA elevation, such as inflammatory conditions and benign prostatic hyperplasia (BPH), and these have restricted the diagnostic specificity of total PSA⁽⁴⁾. Moreover, a large number of patients with elevated PSA levels have negative biopsy result, and it has been recommended that these patients should undergo repeated biopsy⁽⁵⁾.

Correspondence to : Phongkitkarun S, Department of Radiology, Faculty of Medicine, Ramathibodi Hospital, Rama VI Rd, Rajchathewi, Bangkok 10400, Thailand. Phone: 0-2201-1260, Fax: 0-2201-1297, E-mail: rasih@mahidol.ac.th

Zackrisson et al⁽⁶⁾ reported that the simple repeated positive sextant rate in patients with persistently increasing serum PSA decreases gradually rate from 23% at the first round to a 17.6%, 11.7%, 8.7% and 0% at the second, third, fourth, and fifth rounds, respectively. The second diagnosis is almost comparable to the first biopsy because of the high false negative rates of the current TRUS biopsy technique in the patients. It is also largely due to the lack of sensitivity of TRUS for detection of prostate cancer. In this respect, there is a need for a more sensitive and reliable imaging modality to detect prostate cancer and direct biopsy.

Helical computed tomography (CT) and conventional magnetic resonance (MR) imaging of the prostate have improved the detection of cancer within the prostate^(7,8). Endorectal magnetic resonance imaging (MRI) has been used to image the prostate for years, mostly focusing on local staging in patients whose biopsies have been proven prostate cancer. There are only a few studies focusing on prostate cancer localization by using MRI. The accuracy of the technique has been reported in the literature ranging from 54% to 87%, and there is no agreement with regard to the value of MRI for this indication⁽⁹⁻¹¹⁾.

Many studies in the literature also confirm the variations of the sensitivity or specificity in combined MRI and MRSI with direct TRUS in patients with a previous negative TRUS biopsy. For example, Yuen et al⁽¹²⁾ and Delphine et al⁽¹³⁾ reported the sensitivity and specificity of 100% and 79.2%, and 73.3% and 96.3%, respectively.

Since there has been no research in Thai males, the purpose of the present study was to determine the accuracy of the combination of MR imaging and MR spectroscopic imaging for the detection of prostatic cancer in men with a PSA level greater than 4 ng/mL and negative prior TRUS-guided biopsy.

Material and Method

Patients

From January to October 2006, the patients who visited the Urology Department at Ramathibodi Hospital and whose PSA levels were persistently greater than 4 ng/mL with at least one negative prior sextant TRUS guided biopsy result, were included in the present study. MRI and MRSI were performed after informed consent. Patients with contraindications to MR imaging (e.g., cardiac pacemaker, cochlear transplant, claustrophobia) or use of an endorectal coil (e.g. perianal inflammation) were excluded from the present study.

MR imaging techniques

To eliminate hemorrhagic effects, the patients had to wait at least 8 weeks after TRUS biopsy before the MRI⁽¹⁴⁾. They were examined with 1.5-T whole-body MR imaging unit (CV/i & NV/i; GE Medical Systems, Milwaukee, Wis). The patients were imaged while in the supine position by using a body coil and a pelvic phased-array coil (Torso PA; GE Medical Systems). Axial spin-echo T1-weighted images were obtained from the aortic bifurcation to the symphysis pubis by using the following parameters: 600/12.6 (repetition time (TR), msec; and echo time (TE), msec), a 5-mm section thickness, a 1-mm intersection gap, a 32-cm field of view (FOV), a 256x160 matrix, an axial frequency direction, and one acquired signal. Thin section, high spatial resolution axial and coronal T2-weighted fast spinecho MR images of the prostate and seminal vesicles, combined with a balloon-covered expandable endorectal coil (Medrad, Pittsburgh, PA), were obtained by using the following parameters: 6000/96 (TR/TE effective), an echo train length of 16, a 3-mm section thickness, 0-mm intersection gap, a 16-cm FOV, a 512x256 matrix, an anteroposterior frequency direction.

Radiologists using axial T2-weighted MRI selected a spectroscopic MR imaging volume. The volume was selected to maximize coverage of the prostate while minimizing the inclusion of periprostatic fat and rectal air. Three dimensional MRSI data were acquired by using a water and lipid-suppressed double-spinecho point. Data sets were acquired as 16 x 8 x 8 phase-encoded spectral arrays (1024 voxels) by using a nominal spectral resolution of 0.24-0.34 cm, 1000/130 (TR/TE), and a 17-minute acquisition time.

Interpretation of MR imaging and MR spectroscopic imaging data

The results of the MRI and the MRSI were interpreted by an experienced radiologist (S.P.). In general, there are three different ways to analyze the MRI and MRSI, namely, normal, equivocal, and suspicious for prostate cancer.

MRI: Based on T2 signal intensity, an area would be called normal when it had homogeneous isosignal intensity. Equivocal was called in the area of slightly heterogeneous low signal intensity. Suspicious was called in the area of discrete and homogeneously low in signal intensity and when it did not correspond to the hemorrhagic areas with high signal intensity on T1-weighted images.

MRSI: The radiologists interpreted the voxels, which were suitable for analysis. Images would be

considered suitable if they were not contaminated by insufficiently suppressed water or lipids. There are two interpretation approaches to rate the five-point scoring system⁽¹⁵⁾. Firstly, it is the spectra interpretation from which the authors obtained the score from the spectral pattern. Secondly, the choline-plus-creatine-to-citrate (CC/C) ratio interpretation from which the authors obtained the score from the metabolism, which is called voxel scoring system^(15,16). After obtaining the voxel scoring system, the authors followed the steps as below;

1. A primary score of 1-5 was assigned on the basis of the mean normal choline-plus-creatine-to-citrate ratio (CC/C). Based on the results from a previously published study⁽¹⁷⁾ involving the use of the MR spectroscopic imaging data acquisition and processing techniques, the mean CC/C was determined to be 0.22 with standard deviation (SD) of 0.013.

2. To obtain the final voxel score, the authors had to adjust the 'primary score' step by step as follows:

- At the initial adjustment step, the primary voxel score was adjusted to account for elevation of the choline level relative to the creatine level.
- When the choline-to-creatine (CC) ratio was equal or more than 2 with a primary score of 2 and 3, the score was increased by 1 to be 3 and 4, respectively.
- When the CC ratio was less than 2 with a

primary score of 4 and 5, the score was decreased by 1 to be 3 and 4, respectively.

- For the final adjustment step, the score was made to account for poor spectral signal-to-noise ratios. The poor ratio was defined as a peak area-to-noise ratio <5 and <8 when the initial voxel score was 1 or 2 and 3 to 5, respectively. In the presence of a poor spectral signal-to-noise ratio, a score of 1 to 4 became to score 3, and the score of 5 became score 4.

Both of the two approaches were interpreted as normal when the voxel score was 1 and 2. The equivocal was judged for the voxel score of 3, while the other scores of 4 and 5 were judged for suspicious.

Core-needle biopsies

Within 1 month after MRI study, TRUS-guided prostate biopsy was performed by using an ultrasound machine with a convex 7.5 MHz sector probe. Prostatic cores were obtained using biopsy gun with an 18-gauge biopsy needle. The TRUS-guided biopsy was performed under general anesthesia. The routine 12 cores were performed as the standard located on peripheral zone (two cores of each sextant). Four additional cores were taken from the abnormal sites from MRI and MRSI findings (including equivocal and suspicious), which localized lesion by using specific landmark (urethra and apical prostate gland) (Fig. 1). All cores were labeled according to their location and corresponding abnormal voxels.

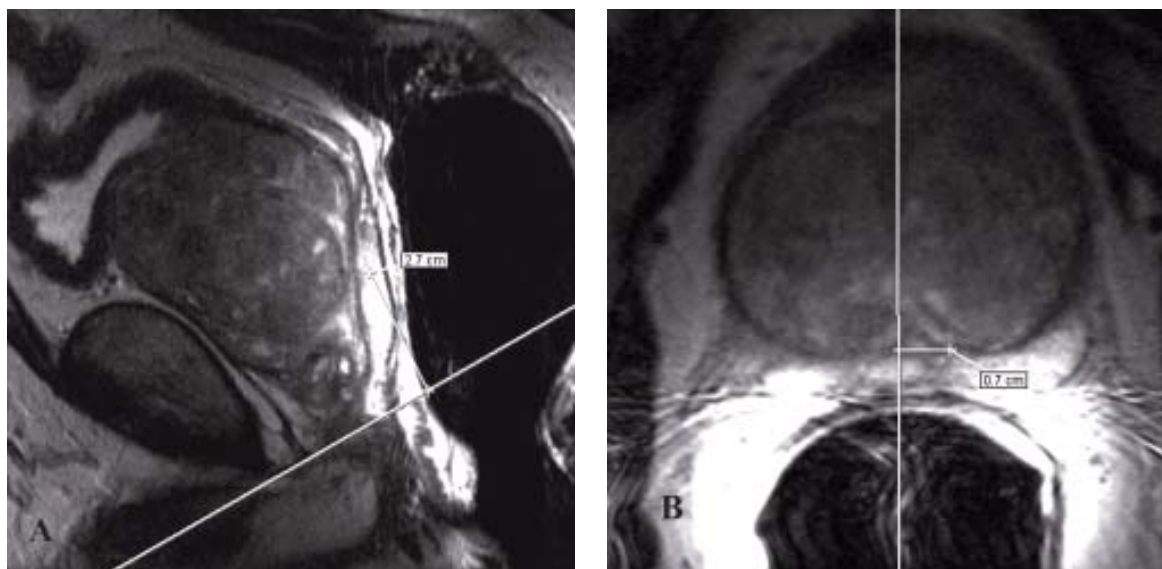


Fig. 1 Showing the localization technique for landmark of MRI/MRSI guided TRUS-guided biopsy by measuring from the apex (A) and midline (B)

Histopathologic analysis

All biopsy samples were analyzed histopathologically by a pathologist with experience in prostate pathology, and used as the standard of reference for the MR spectroscopic imaging findings. The histopathological analysis included determination of the positive or negative for malignancy; if positive for malignancy, the Gleason score was described.

Statistical analysis

All data were entered and analyzed by using basic 2 x 2 tables for sensitivity, specificity, and positive and negative predictive values and accuracy.

Results

Twenty-one consecutive patients underwent sextant biopsy (range 12-22 cores) between January and October 2006. Mean age was 61.4 years (range 50 to 77) and mean serum PSA levels were 13.1 ng/mL (range 4.3 to 46.6). Before the study, one, two, and three previous TRUS prostate biopsies had been done in 15, 5, and 1 patient, respectively.

In the MRI and MRSI analyses, the normal and equivocal categories were interpreted as negative for malignancy, while the suspicious category was interpreted as positive for malignancy. MRI, MRSI and combined MRI/MRSI showed suspicion for malignancy in 6, 7 and 5 patients, respectively. However, only two patients (9.5%) were diagnosed with prostate cancer by TRUS biopsy. The first patient whose previous biopsy revealed prostatic intraepithelial neoplasia (PIN) grade II had PSA 23.3 ng/mL. The other whose two previous biopsies revealed BPH had PSA 9.8 ng/mL. Both patients showed the Gleason score of 3 + 3 in the biopsy. The rest of patients, whose MRI and MRSI shown false positive, had either BPH or chronic prostatitis.

On patient by patient basis, MRI, MRSI and combined MRI/MRSI had 100%, 100% and 100% sensitivity, 79%, 74% and 84% specificity, 33%, 29% and 40% positive predictive value (PPV), 100%, 100% and 100% negative predictive value (NPV) and 81%, 80% and 86% accuracy for predicting prostate cancer detection (Table 1, 2 and 5).

There were 290 cores obtained from 21 patients. By using the spectra analysis, of which 14 cores were positive for cancer (15%). In this cohort, 53 cores of MRI, 65 cores of MRSI and 32 cores of combined MRI/MRSI revealed suspicious malignancy. Nine of 53 MRI (17%), 11 of 65 (17%) MRSI and 9 of 52 (17%) combined MRI/MRSI labeled suspicious voxels

Table 1. Accuracy of MRI in patient-by-patient basis (n = 21)

| | Pathologic results | | Total |
|---------------------------|---------------------|---------------------|------------|
| | Positive for cancer | Negative for cancer | |
| MR imaging | | | |
| Positive | 2 | 4 | 6 |
| Negative | 0 | 15 | 15 |
| Total | 2 | 19 | 21 |
| Sensitivity | | | 100 |
| Specificity | | | 79 (62-96) |
| Positive predictive value | | | 33 (13-54) |
| Negative predictive value | | | 100 |
| Accuracy | | | 81 (64-98) |

Table 2. Accuracy of combined MRI/MRSI in patient-by-patient basis (n = 21)

| | Pathologic results | | Total |
|---------------------------|---------------------|---------------------|-------------|
| | Positive for cancer | Negative for cancer | |
| Combined MRI/MRSI | | | |
| Positive | 2 | 3 | 5 |
| Negative | 0 | 16 | 16 |
| Total | 2 | 19 | 21 |
| Sensitivity | | | 100 |
| Specificity | | | 84 (69-100) |
| Positive predictive value | | | 40 (29-61) |
| Negative predictive value | | | 100 |
| Accuracy | | | 86 (71-100) |

Table 3. Accuracy of MRI in voxel-by-core basis (n = 290)

| | Pathologic results | | Total |
|---------------------------|---------------------|---------------------|-------------|
| | Positive for cancer | Negative for cancer | |
| MRI imaging | | | |
| Positive | 9 | 44 | 53 |
| Negative | 5 | 232 | 237 |
| Total | 14 | 276 | 290 |
| Sensitivity | | | 64 (59-70) |
| Specificity | | | 84 (80-88) |
| Positive predictive value | | | 17 (13-62) |
| Negative predictive value | | | 98 (96-100) |
| Accuracy | | | 89 (64-98) |

Table 4. Accuracy of combined MRI/MRSI in voxel-by-core basis (n = 290)

| | Pathologic results | | Total |
|---------------------------|---------------------|---------------------|-------------|
| | Positive for cancer | Negative for cancer | |
| MRI imaging | | | |
| Positive | 9 | 23 | 32 |
| Negative | 5 | 253 | 258 |
| Total | 14 | 276 | 290 |
| Sensitivity | | | 64 (59-70) |
| Specificity | | | 92 (89-95) |
| Positive predictive value | | | 28 (23-33) |
| Negative predictive value | | | 98 (97-100) |
| Accuracy | | | 90 (89-94) |

Table 5. Comparison MRSI by using spectra and additional CC/C interpretation

| Statistics | Spectra interpretation (mean, range) | Additional CC/C interpretation (mean, range) |
|---------------------------|--------------------------------------|--|
| Sensitivity | 79 (74-83) | 80 (75-85) |
| Specificity | 80 (76-100) | 85 (74-97) |
| Positive predictive value | 17 (13-21) | 21 (18-25) |
| Negative predictive value | 98 (97-100) | 99 (98-100) |
| Accuracy | 80 (76-85) | 85 (80-90) |

CC/C: Choline-plus-creatine-to-citrate ratio

were positive for cancer on histology.

On a voxel-by-cores basis, MRI, MRSI and combined MRI/MRSI had 64%, 79% and 64% sensitivity, 84%, 80% and 92% specificity, 17%, 17% and 28% PPV, 98%, 98% and 98% NPV and 89%, 80% and 90% accuracy for predicting prostate cancer detection (Table 3-5).

By using the CC/C ratio interpretation, 52 cores of MRSI revealed suspicious malignancy. 11 of 52 (21%) MRSI labeled suspicious voxels were positive for cancer on histology. There were 80% sensitivity, 85% specificity, 21% PPV, 99% NPV and 85% accuracy for predicting prostate cancer detection. A comparison between the MRSI interpretation by using spectra and additional CC/C interpretation is shown in Table 5.

In addition, the MRSI analysis for CC/CI ratio and Ch/Cr ratio of cancer voxels were 2.02 ± 1.15 and 3.38 ± 1.01 , respectively. On the other hand, non-

malignant voxels were 0.54 ± 0.23 and 1.11 ± 0.38 , respectively.

Examples of true positive, false positive, true negative and false negative are presented in Fig. 2 to 5.

Most patients had transient hematuria after TRUS biopsy but it was self-resolving. There was no case of sepsis or severe bleeding that required in-patient treatment.

Discussion

The present study demonstrated the potential of transferring metabolic data from MRSI and morphologic data from MRI to help TRUS-guided biopsy, and the enabling of effective use the data to sample regions of cancer in men with persistently high PSA levels and negative TRUS-guided biopsy result. The result was similar to the recent preliminary reports by Prado⁽¹⁶⁾ and Yeun⁽¹²⁾.

The sensitivity, specificity, PPV, NPV, and accuracy of MRI and MRSI were calculated by using two bases. The first one was using a patient-by-patient basis for cancer detection. In this circumstance, if there is at least one voxel suspicious of malignancy, that patient will be called as positive for cancer by MR study. This approach was aimed to determine the usefulness of MR study to suggest the possibility of the patient's having prostate cancer. Even though, the specificity was not high, the 100% sensitivity was found contrary to the study of Yeun⁽¹²⁾.

The second was the voxel-by-core basis. This approach compared between each voxel interpretation on MRI, MRSI, or combined data and the histological study in each biopsy core. The result showed high specificity. According to this data, one could predict tumor volume and do treatment planning such as precise localization for intensity-modulated radiotherapy. The sensitivity of combined MRI/ MRSI on voxel-by-voxel basis was 64% in the present study, which was lower than 85% reported by Prado⁽¹⁶⁾. However, there was the same high NPV (98%) similar to that of Prado (97%) and of Yeun (100%) studies^(12,16). Therefore, with this high NPV, negative MRI/ MRSI findings obviate the need for further biopsies.

The false positive voxels (relative increased choline and decreased citrate) were shown to be normal prostatic acini, BPH, and chronic prostatitis in histologic studies. In this regard, Prado et al⁽¹⁶⁾ speculated that the false positive due to high choline level could be from proliferative variation in focal proliferative atrophy.

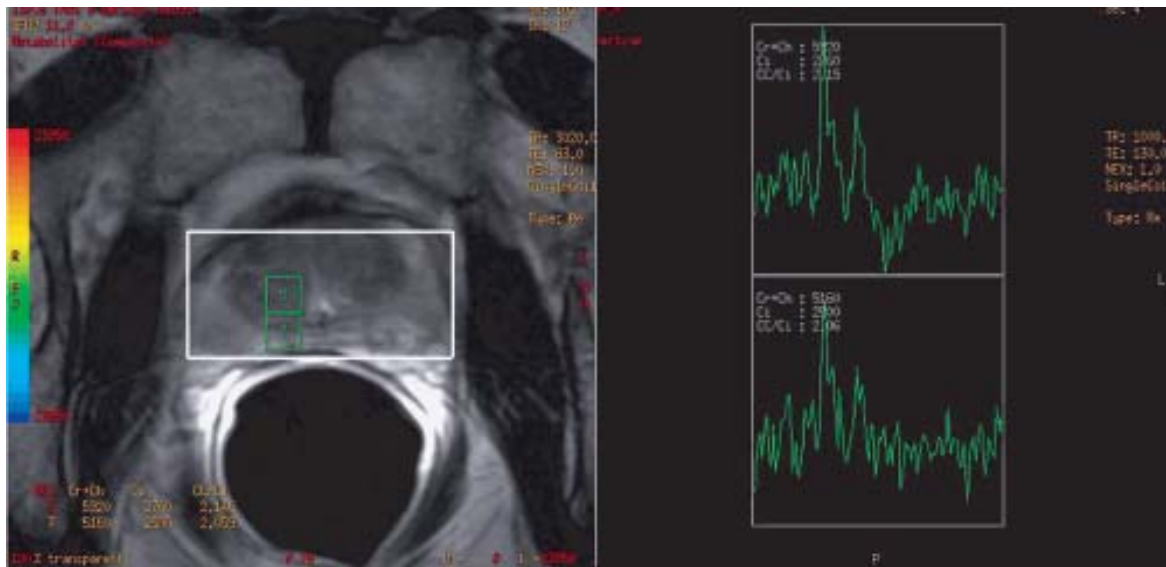


Fig. 2 Spectrum of true positive for malignancy from pathology MRI and MRSI of a 61-year-old male whose two previous TRUS biopsies revealed BPH and had persistently high serum PSA 9.8 ng/mL, showed suspicious voxels (high CC/C ratio) at right paramedian of mid gland of the prostate. Directed biopsy was positive for cancer (Gleason score 3 + 3)

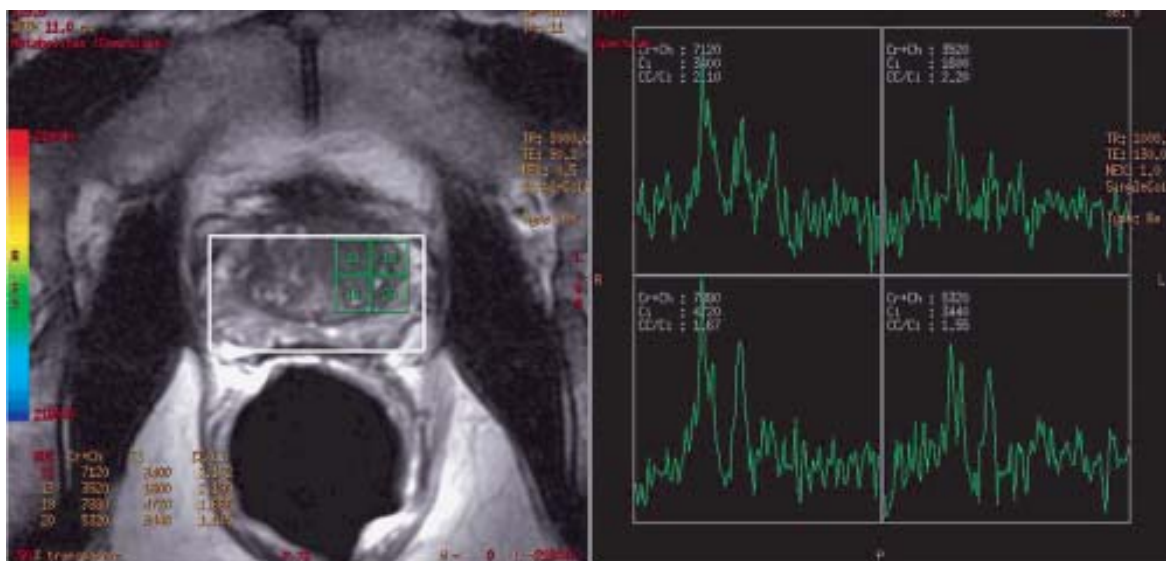


Fig. 3 Spectrum of false positive for malignancy from pathology MRI and MRSI of a 71-year-old male whose two previous TRUS biopsies revealed BPH and had persistently high serum PSA 11.5 ng/mL showed suspicious voxels (high CC/C ratio) at left central gland of the prostate. Directed biopsy was again shown BPH

The false negative voxels (slightly increased choline while citrate still high) were found to be prostate cancer (Gleason 3 + 3). The previous TRUS biopsy of the patient was shown PIN, which is considered pre-

malignant. The MR images of this particular patient showed normal signal intensity of the peripheral zone and had no focal lesion. The authors speculated that tumor volume in each MR voxel was too small.

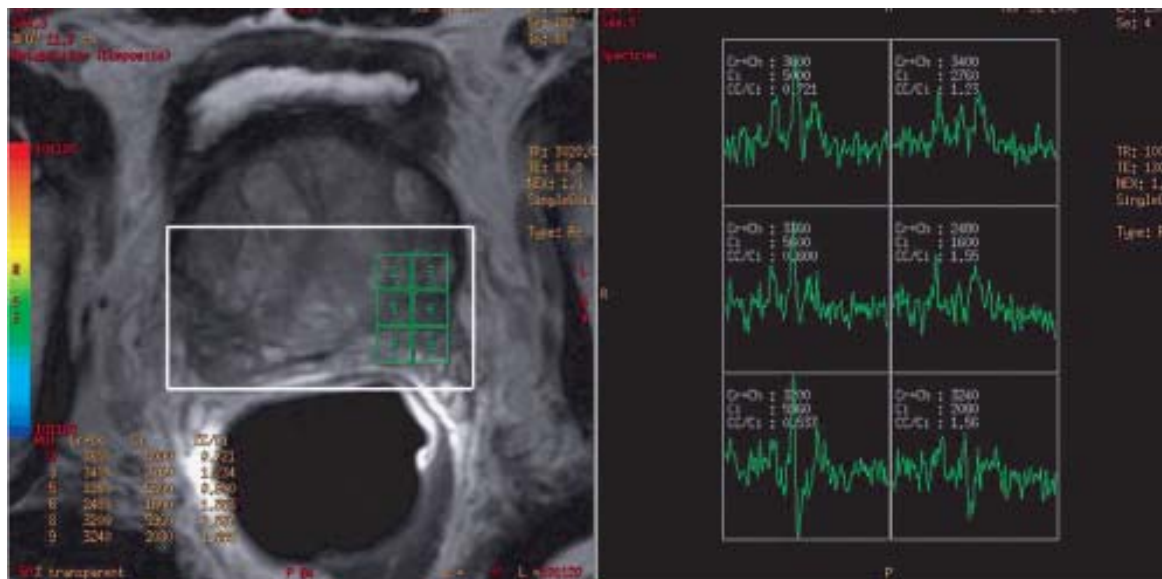


Fig. 4 Spectrum of true negative for malignancy from pathology
MRI and MRSI of a 67-year-old male whose one previous TRUS biopsy revealed BPH and had persistently high serum PSA 9.8 ng/mL showed enlarged central gland and normal spectrum. Directed biopsy showed BPH

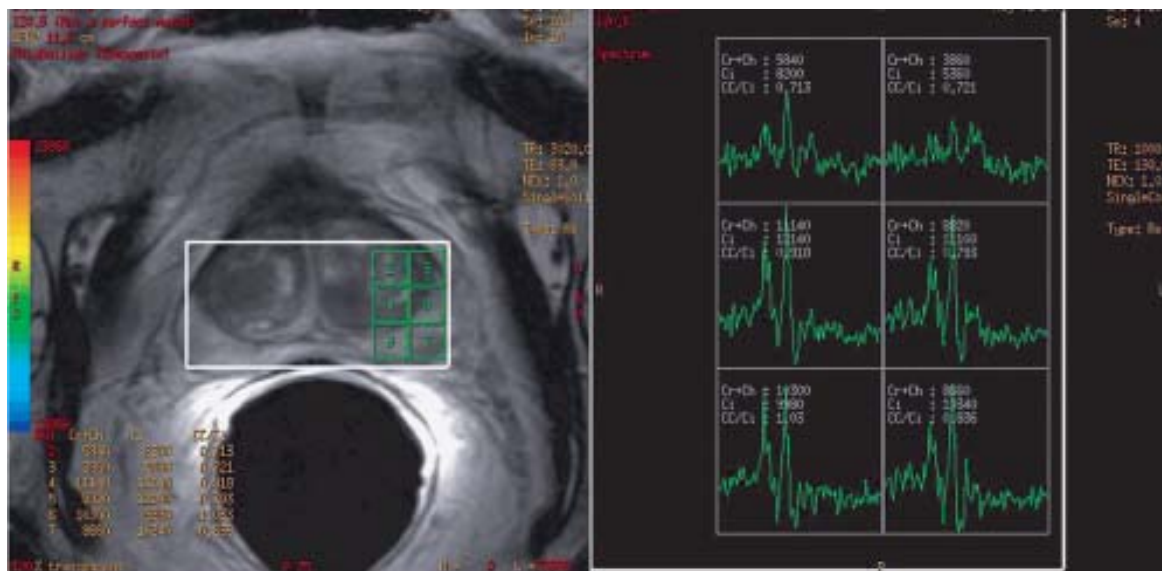


Fig. 5 Spectrum of false negative for malignancy from pathology
MRI and MRSI of a 55-year-old male whose one previous TRUS biopsy revealed PIN and had persistently high serum PSA 23.3 ng/mL showed borderline spectrum. Directed biopsy was positive for cancer (Gleason score 3 + 3)

Therefore, the metabolite change and abnormal signal intensity were not clearly demonstrated on the images.

In the present study, the addition of spectroscopy information to MRI yielded higher specificity,

PPV, NPV and accuracy but no change in sensitivity when compared with MRI alone. This observation suggested that the combined MRI/ MRSI modality was superior to MRI or MRSI alone. It could explain by the

fact that the abnormality hyposignal intensity on T2-weighted images is not specific. It could be either cancer foci or secondary to localized inflammation or fibrosis. With the alteration of metabolites information that is increased choline from cellular proliferation and decreased citrate from normal prostate acini destruction, however, one could be able to better differentiate between these two. However, studies are required to establish the real benefit of either or both modality.

After having MR spectroscopic analysis with spectra interpretation, the final voxel scoring system was obtained from the combined spectra and CC/C ratio interpretation. This adjusted CC/C ratio interpretation yielded better results because baseline fluctuation, which directly influenced on the ratio was corrected. Similar results were observed in study of Jung⁽¹⁵⁾.

Sextant TRUS biopsy may have the unexpected complications, i.e., bleeding and infections. Fortunately, there was no serious complication in the present study.

There were limitations in the present study. The statistical results of the present study should be interpreted with caution due to its small sample size. Further data collection in this type of patient population is still needed. Moreover, there was difficulty in ensuring the correspondence of TRUS biopsy sites to the suspicious MRI/ MRSI areas intended for biopsy. Even though, the authors tried to avoid the mistaken lesion by allocating the specific landmark for TRUS-guided biopsy related with the urethra and apex of the prostate gland. However, the whole-mount specimen of prostatectomy comparison with MRI data is more likely to solve this limitation.

In conclusion, endorectal MRI with MRSI has the potential to guide biopsy to cancer foci in patients with persistently high PSA levels and negative TRUS biopsy results. A high NPV can help to decrease unnecessary biopsies.

Acknowledgements

The authors wish to thank Professor Dr. Amnauy Thithapandha from Division of Academic Affairs, Ramathibodi Hospital for his assistance in editing this paper and Dr. Umaporn Udomsubpayakul from the Clinical Epidemiology Unit, Research center, Ramathibodi Hospital for statistical consultant.

References

1. Cancer in Thailand. Bangkok: Cancer Research Foundation for National Cancer Institute; 1995-1997.

2. Annual report ramathibodi cancer registry. Bangkok: Faculty of Medicine Ramathibodi Hospital Mahidol University; 2004.
3. Colombo T, Schips L, Augustin H, Gruber H, Hebel P, Petritsch PH, et al. Value of transrectal ultrasound in preoperative staging of prostate cancer. *Minerva Urol Nefrol* 1999; 51: 1-4.
4. Stamey TA. Making the most out of six systematic sextant biopsies. *Urology* 1995; 45: 2-12.
5. Ellis WJ, Brawer MK. Repeat prostate needle biopsy: who needs it? *J Urol* 1995; 153: 1496-8.
6. Zackrisson B, Aus G, Bergdahl S, Lilja H, Lodding P, Pihl CG, et al. The risk of finding focal cancer (less than 3 mm) remains high on re-biopsy of patients with persistently increased prostate specific antigen but the clinical significance is questionable. *J Urol* 2004; 171: 1500-3.
7. Prando A, Wallace S. Helical CT of prostate cancer: early clinical experience. *AJR Am J Roentgenol* 2000; 175: 343-6.
8. Perrotti M, Han KR, Epstein RE, Kennedy EC, Rabbani F, Badani K, et al. Prospective evaluation of endorectal magnetic resonance imaging to detect tumor foci in men with prior negative prostatic biopsy: a pilot study. *J Urol* 1999; 162: 1314-7.
9. Beyersdorff D, Taupitz M, Winkelmann B, Fischer T, Lenk S, Loening SA, et al. Patients with a history of elevated prostate-specific antigen levels and negative transrectal US-guided quadrant or sextant biopsy results: value of MR imaging. *Radiology* 2002; 224: 701-6.
10. Scheidler J, Hricak H, Vigneron DB, Yu KK, Sokolov DL, Huang LR, et al. Prostate cancer: localization with three-dimensional proton MR spectroscopic imaging - clinicopathologic study. *Radiology* 1999; 213: 473-80.
11. Kurhanewicz J, Vigneron DB, Hricak H, Narayan P, Carroll P, Nelson SJ. Three-dimensional H-1 MR spectroscopic imaging of the in situ human prostate with high (0.24-0.7-cm³) spatial resolution. *Radiology* 1996; 198: 795-805.
12. Yuen JS, Thng CH, Tan PH, Khin LW, Phee SJ, Xiao D, et al. Endorectal magnetic resonance imaging and spectroscopy for the detection of tumor foci in men with prior negative transrectal ultrasound prostate biopsy. *J Urol* 2004; 171: 1482-6.
13. Amsellem-Ouazana D, Younes P, Conquy S, Peyromaure M, Flam T, Debre B, et al. Negative prostatic biopsies in patients with a high risk of prostate cancer. Is the combination of endorectal

- MRI and magnetic resonance spectroscopy imaging (MRSI) a useful tool? A preliminary study. *Eur Urol* 2005; 47: 582-6.
14. Qayyum A, Coakley FV, Lu Y, Olpin JD, Wu L, Yeh BM, et al. Organ-confined prostate cancer: effect of prior transrectal biopsy on endorectal MRI and MR spectroscopic imaging. *AJR Am J Roentgenol* 2004; 183: 1079-83.
 15. Jung JA, Coakley FV, Vigneron DB, Swanson MG, Qayyum A, Weinberg V, et al. Prostate depiction at endorectal MR spectroscopic imaging: investigation of a standardized evaluation system. *Radiology* 2004; 233: 701-8.
 16. Prando A, Kurhanewicz J, Borges AP, Oliveira EM Jr, Figueiredo E. Prostatic biopsy directed with endorectal MR spectroscopic imaging findings in patients with elevated prostate specific antigen levels and prior negative biopsy findings: early experience. *Radiology* 2005; 236: 903-10.
 17. Males RG, Vigneron DB, Star-Lack J, Falbo SC, Nelson SJ, Hricak H, et al. Clinical application of BASING and spectral/spatial water and lipid suppression pulses for prostate cancer staging and localization by in vivo 3D 1H magnetic resonance spectroscopic imaging. *Magn Reson Med* 2000; 43: 17-22.

ความแม่นยำในการตรวจพิเศษคลื่นแม่เหล็กไฟฟ้าในผู้ป่วยที่มีค่า PSA สูงกว่าปกติอย่างต่อเนื่อง แต่ผลการสุ่มชิ้นเนื้อไม่พบมะเร็งต่อมลูกหมาก

ศัลยศาสตร์ บัณฑิตยา, สิทธิ พงษ์กิจการุณ, เดชาพล บุรณพิทักษ์สันติ, วชิร คชการ, พันัส เฉลิมแสนยากร

วัตถุประสงค์: เพื่อศึกษาความแม่นยำของคลื่นแม่เหล็กไฟฟ้าและการตรวจหาสารประกอบภายในเนื้อเยื่อ ด้วยเทคนิคพิเศษคลื่นแม่เหล็กไฟฟ้า (MRI & MRSI) ในการบอกตำแหน่งเพื่อเจาะชิ้นเนื้อในผู้ป่วยที่เคยได้รับการสุ่มชิ้นเนื้อมาก่อน แต่ไม่พบมะเร็งต่อมลูกหมากแต่ยังมีค่า prostate specific antigen (PSA) สูงอย่างต่อเนื่อง

วัสดุและวิธีการ: ศึกษาผู้ป่วยชายทั้งสิ้น 21 รายที่มารับการตรวจในช่วงเดือน มกราคม ถึงตุลาคม พ.ศ. 2549 และพบว่า มีค่า PSA สูงและผลการสุ่มชิ้นเนื้อในอดีตไม่พบมะเร็งต่อมลูกหมาก โดยผู้ป่วยทุกรายจะได้รับการตรวจ MRI และ MRSI ก่อนทำการสุ่มตรวจชิ้นเนื้ออีกครั้งภายในระยะเวลา 1 เดือน ทั้งนี้ภาพจากการตรวจ MRI และ MRSI จะได้รับการแปลผลตามลักษณะความน่าจะเป็นมะเร็งต่อมลูกหมากในแต่ละรายและต่อตำแหน่งในการเจาะชิ้นเนื้อ

ผลการศึกษา: จากผู้ป่วย 21 ราย พบมะเร็งต่อมลูกหมาก 2 ราย (9.5%) และพบว่าการวินิจฉัยมะเร็งต่อมลูกหมากด้วยวิธี MRI และ MRSI มีความไว ความจำเพาะ และความแม่นยำ ร้อยละ 100, 84 และ 86 ตามลำดับ และความแม่นยำในการบอกตำแหน่งเพื่อเจาะชิ้นเนื้อ ร้อยละ 85

สรุป: การศึกษานี้พบว่า MRI และ MRSI มีประโยชน์สำหรับผู้ป่วยที่มีค่า PSA สูงกว่าปกติอย่างต่อเนื่อง แต่ผลการสุ่มชิ้นเนื้อไม่พบมะเร็งต่อมลูกหมากมาก่อน ช่วยลดการสุ่มตรวจชิ้นเนื้อโดยไม่จำเป็นถ้าการตรวจด้วย MRI และ MRSI ให้ผลลบ และช่วยในการบอกตำแหน่งเพื่อเจาะชิ้นเนื้อ
