

Preliminary Report

Asymptomatic Avascular Osteonecrosis of the Hip in New Patients Diagnosed as Systemic Lupus Erythematosus in Ramathibodi Hospital

Suphaneewan Jaovisidha MD*, Rungwadee Denprechawong MD*,
Parawee Suwannalai MD**, Suchela Janwityanujit MD**

* Division of Diagnostic Imaging, Department of Radiology, Faculty of Medicine,
Ramathibodi Hospital, Mahidol University

** Division of Allergy, Immunology and Rheumatology, Department of Medicine,
Faculty of Medicine, Ramathibodi Hospital, Mahidol University

Objective: To determine asymptomatic avascular osteonecrosis (AVN) of the hip in new patients diagnosed as Systemic Lupus Erythematosus (SLE) in Ramathibodi Hospital.

Material and Method: A prospective descriptive study of new SLE patients with asymptomatic hip at the Rheumatology clinic of Ramathibodi Hospital was conducted from February 2005 to November 2005. The information of steroid and immunosuppressive drug treatment was recorded. Plain film (AP and frog leg views) and MR study of both hips were analyzed.

Results: Twenty-two hips (11 patients) were enrolled in the present study (women 100%; mean age 27.8 years; range 16-50). Four hips (2 patients, 18%) had AVN, without other abnormal imaging findings of the hips and pelvis. Seventeen hips of nine patients had joint effusion; none of them had AVN. No marrow edema, secondary osteoarthritis, collapsed femoral head or pelvic insufficiency fracture in all patients is detected. In the present study, the 2 AVN patients had longest duration of steroid treatment before MR study (105 & 99 days) and rather high cumulative dose of prednisolone or its equivalent dose (4,920 & 4,540 mg), compared to non-AVN patients.

Conclusion: SLE patients without hip pain may have AVN of the hips. Joint effusion and marrow edema do not necessarily associate with early AVN, and the authors found early AVN without joint effusion. Cumulative dose and duration of steroid treatment seem to relate to AVN in the present study. However, a larger number of cases, prospective clinical data, and long-term follow up will help better evaluate the prevalence of asymptomatic AVN of the hips, as well as to evaluate the benefit of MRI as a screening tool for patients at risk of AVN.

Keywords: Avascular necrosis, Steroid, Magnetic resonance imaging (MRI)

J Med Assoc Thai 2007; 90 (7): 1382-90

Full text. e-Journal: <http://www.medassocthai.org/journal>

Avascular osteonecrosis (AVN) is a major morbidity in systemic lupus erythematosus (SLE) with a prevalence ranging from 10-52%⁽¹⁻⁴⁾. The hip (femoral head) is the most common site of AVN in SLE patients, about 95%, and bilateral involvement was present in 72% of patients⁽²⁾. The development of AVN in SLE has been reported to significantly associate with high dose of corticosteroids received^(1,3-6). The earliest time of

AVN occurrence was within the first month of high dose corticosteroid treatment (range 1-5 months)^(1,7).

Many studies have investigated the risk factors of AVN and details of steroid administration. The total treatment period, the highest daily dose, the continuous high dose, the cumulative dose, and the pulse methylprednisolone treatment, has been reported as risk factors of AVN in SLE^(1,5,8). In contrary, some investigations have reported that the association of AVN with pulse methylprednisolone treatment remains a subject of controversy^(3,6).

Correspondence to : Jaovisidha S, Division of Diagnostic Imaging, Department of Radiology, Ramathibodi Hospital, Rama 6 Rd, Bangkok 10400, Thailand.

Many clinicians selected core decompression to treat AVN. Such a decision was primarily based upon stage of disease and lesion size, and does not necessarily depend on whether the patient is symptomatic⁽⁹⁾. If the disease goes on to the later stages with secondary osteoarthritis of the hip, the treatment will end up with total hip arthroplasty⁽¹⁰⁾. When symptomatic, 85% of the femoral head with AVN will collapse within 2 years if untreated, regardless the stage of disease⁽³⁾. Therefore, early diagnosis of AVN of the femoral head prior to the onset of osteoarthritis, and when asymptomatic, is important for initiating early treatment, which is associated with a more favorable outcome^(11,12).

Unfortunately, AVN in SLE patients can be asymptomatic despite involvement of multiple sites, and becomes symptomatic only about 5-10%^(2,6). A high index of suspicion and clinical awareness are essential to make a diagnosis at an early stage, when plain radiographs are frequently normal. Diagnosis at this stage is possible only from a bone scintigram or magnetic resonance imaging (MRI). MRI has been shown to correlate excellently with intra-osseous pathology (sensitivity and specificity approaching 100%⁽¹³⁾). MRI can provide images of equal resolution in any plane, and is helpful in evaluating the extent and location of involvement⁽³⁾. MRI can detect marrow edema that is associated with AVN of any stage. In addition, AVN was reported to associate with pain and joint effusion⁽¹⁴⁾.

The present study evaluated AVN in asymptomatic hip of newly diagnosed SLE patients.

Material and Method

Patients

The authors evaluated new patients diagnosed as SLE in the Rheumatology clinic of Ramathibodi Hospital, or diagnosed from other hospitals not more than 1 month, since February 2005 to November 2005. All patients fulfilled the revised criteria for SLE established by the American Rheumatism Association. These patients had asymptomatic both hips. Patients who were younger than 15 years old were not included, as sedation prior to MR imaging might have been required.

The authors excluded patients with contraindication for MRI study, previous diagnosis of AVN, pregnancy, and alcoholism. The hospital ethics committee approved the present study, and all patients provided written informed consent.

The demographic characteristic (age, sex, weight, underlying disease i.e., DM & HT, smoking); criteria to diagnose SLE; information regarding steroid

administration prior to MRI imaging such as pulsed intravenous methylprednisolone treatment (1 gm IV OD x 3 days), cumulative prednisolone-equivalent doses, average daily prednisolone-equivalent doses, average daily prednisolone-equivalent doses adjusted for weight, maximum daily prednisolone-equivalent doses, duration of steroid treatment prior to MR imaging; and other immunosuppressive drugs, were collected.

Prednisolone-equivalent doses was calculated by adjusting the dexamethasone or methylprednisolone doses to the prednisolone equivalence on the basis of anti-inflammatory potency, using conversion factors of 0.67 and 1.25, respectively.

Imaging Protocol

Radiographs in anteroposterior (AP) and frog leg views of both hips were taken. MR imaging was performed with a 1.5-T unit (General Electric, WI). A modified MR imaging protocol of the hips was used, which was designed specifically for osteonecrosis evaluation. The MR imaging protocol included coronal T1-weighted spin-echo sequence (540/9-14 [repetition time msec/echo time msec]); coronal T2-weighted fat-suppression (3600-3900/81.4-89.0); the section thickness was 3 mm, intersection gap was 0.3-1.0 mm, field of view was 26.4-32.9 cm, and matrix of 320x224-256; Sagittal T1-weighted spin-echo sequence (440-582/9.0-14.0) with a section thickness of 3 mm, intersection gap of 1.0 mm, field of view of 26.0-27.9 cm, and matrix of 320x224-256 on each side of the hip were obtained.

Imaging Interpretation

MR images were evaluated with consensus by a musculoskeletal radiologist and a resident in radiology, who were blinded to clinical detail.

Imaging findings that were associated with AVN and SLE were recorded; which included collapse of femoral head, subchondral cyst, marrow edema, joint effusion, osteoarthritis (narrow joint space, osteophyte formation, deformity), status of sacroiliac (SI) joint, as well as sacral and parasymphseal insufficiency fracture if there was one. Findings of narrow joint space and osteophyte formation were assessed on plain radiographs.

Avascular osteonecrosis (AVN) defined as focal area of homogeneous/inhomogeneous band like low signal intensity on T1-weighted image (T1WI) or detectable "double line sign" change on T2WI. The severity of AVN in the femoral head was graded based on the extent of femoral head involvement. Grade 1: Lesion confined in the epiphyseal region; grade 2:

lesion extends beyond the epiphyseal region, but involves less than half of the rest of the femoral head; grade 3: lesion extends beyond the epiphyseal region, and involves more than half of the rest of the femoral head.

Marrow edema defined as ill-defined area of low signal intensity on T1WI and high signal intensity on T2WI, and its extension was also specified (femoral head, femoral neck, intertrochanteric region, proximal femoral shaft).

The amount of *joint effusion* was based on thickness of fluid signal on lateral aspect of mid femoral neck, and defined as; grade 1: more than a slit-like but < 5 mm, grade 2: 5-10 mm, grade 3: > 10 mm. The *sacroiliac (SI) joint* was divided into synovial and ligamentous parts. Abnormalities were categorized to 1: joint fluid, 2: periarticular erosion, 3: abnormal marrow signal, 4: other. MRI finding that indicated *insufficiency fracture* is seen as band of decreased signal intensity on T1WI and T2WI with/without surrounding marrow edema.

Abnormal MRI findings not described above were also recorded in the category of others.

Statistical analysis

The clinical data, information of steroid treatment, and imaging data were collected. Median and range, or mean and standard deviation, were calculated to characterize continuous variables; and percentages were calculated for categorical variables.

Results

All 11 enrolled patients were women, with a mean age of 27.8 years (range 16-50). The mean weight was 49.6 kilograms (range 38.5-76.0). Underlying hypertension was found in one patient (9.1%). Ten patients (91%) had lupus nephritis, and four patients (36%) had pericarditis and/or pleuritis. There was no history of smoking or underlying diabetes mellitus in all patients.

All patients received steroid treatment prior to MRI study. The mean and median values of treatment parameters are shown in Table 1, and the information of steroid treatment for each patient is in Table 2.

Median duration from starting steroid to date of MRI study was 40 days (range 14-105). The mean cumulative prednisolone-equivalent dose was 3402.7 mg (SD \pm 1435.4). The median average daily prednisolone-equivalent dose was 62.6 mg/day (range 36.6-357.5), and when adjusted for weight was 1.1 mg/kg/day (range 0.57-9.3). Two patients (18%) received pulse intravenous methylprednisolone treatment (1 gm IV OD x 3 days). The maximum daily prednisolone-equivalent dose in the present study was 1250 mg/day, which was used as methylprednisolone treatment. Seven patients (64%) received other immunosuppressive drugs [Cyclophosphamide (n = 2), Azathiopine (n = 1), Hydroxychloroquine (n = 3), Chloroquine (n = 4), Mycophenolate Na (n = 1), Methotrexate (n = 1)].

Result of imaging findings is demonstrated in Table 3 and 4. Four of 22 hips (2 patients, 18%) had AVN. There was no patient having unilateral AVN. Three of these four femoral heads had AVN grade 1, and only one had grade 2 (Fig. 1). In these four AVN hips, there was no evidence of femoral head collapse, marrow edema, hip joint effusion, osteoarthritis, abnormal SI joint, or insufficiency fracture. Mild soft tissue swelling in one of two patients was observed.

Seventeen hips (77%) did not have AVN but having effusion. The amount of joint effusion was defined as grade 1 in nine hips (41%) and grade 2 in eight (36%) (Fig. 2). No grade 3 effusion was identified. Fluid in the synovial part of the SI joint was seen in one patient (9.1%), and in the ligamentous part in three patients (27%) (Fig. 3). Two patients had slightly narrow bilateral hip joint spaces, and one patient had a small subchondral cyst at right acetabulum. No patients had marrow edema, collapsed femoral head, osteophyte formation, joint deformity, or insufficiency fracture. However, plain radiographs of two patients

Table 1. Steroid treatment

Steroid treatment	Result
- Dose of steroid: (milligram of prednisolone or its equivalent)	
• Cumulative dose of steroid (mg)	• 3402.7 \pm 1435.4 (mean \pm SD)
• Average dose per day (mg/day)	• Median 62.6 (range 36.6 - 357.5)
• Average dose per kilogram per day (mg/kg/day)	• Median 1.1 (range 0.57-9.3)
• Maximum dose per day (mg/day)	• Median 134 (range 45-1250)
- Duration of treatment (days)	• Median 40 (range 14-105)

Table 2. Information of medical treatment

No.	Cumulative dose of steroid (mg)	Average daily steroid dose per day (mg/day)	Average daily steroid dose per kg per day (mg/kg/day)	MPPT	Maximum steroid dose per day (mg/day)	Duration from steroid treatment to MRI study (days)	Other immunosuppressive drug treatment
1	5,743.5	143.6	2.56	Yes	1,250	40	No
2	4,540	43.2	0.57	No	100.1	105	Yes
3□	3,370	36.6	0.81	No	60	92	Yes
4□	1,751.5	83.4	1.9	No	134	21	Yes
5	2,713.5	84.8	2.02	No	134	32	No
6	3,014	47.1	0.89	No	134	64	Yes
7□	1,754	62.6	1.1	No	134	28	Yes
8	2,810	41.9	1	No	45	67	Yes
9	4,920	49.7	1.08	No	60	99	No
10	1,809	113.1	2.51	No	134	16	No
11	5,004.5	357.5	9.3	Yes	1,250	14	Yes

□ History of prior steroid treatment from other hospital
 Steroid = prednisolone or its equivalent dose
 MPPT = pulse intravenous methylprednisolone treatment

Table 3. Imaging findings in each patient

N0 Finding	1R/L	2R/L	3R/L	4R/L	5R/L	6R/L	7R/L	8R/L	9R/L	10R/L	11R/L
AVN	0/0	2/1	0/0	0/0	0/0	0/0	0/0	0/0	1/1	0/0	0/0
CF	0/0	0/0	0/0	0/0	0/0	0/0	0/0	0/0	0/0	0/0	0/0
NJ	0/0	0/0	0/0	0/0	0/0	1/1	0/0	X/X	0/0	1/1	X/X
Osteophyte	0/0	0/0	0/0	0/0	0/0	0/0	0/0	X/X	0/0	0/0	X/X
SC	0/0	0/0	0/0	0/0	0/0	0/0	0/0	1/0	0/0	0/0	0/0
Deformity	0/0	0/0	0/0	0/0	0/0	0/0	0/0	0/0	0/0	0/0	0/0
ME	0/0	0/0	0/0	0/0	0/0	0/0	0/0	0/0	0/0	0/0	0/0
Effusion	1/1	0/0	2/1	2/1	2/1	2/1	1/0	1/1	0/0	2/2	2/2
SSI	0/0	0/0	0/0	0/0	1/1	0/0	0/0	0/0	0/0	0/0	0/0
LSI	1/1	0/0	0/0	0/0	1/1	0/0	0/0	0/0	0/0	1/1	0/0
P-IF	0/0	0/0	0/0	0/0	0/0	0/0	0/0	0/0	0/0	0/0	0/0
S-IF	0/0	0/0	0/0	0/0	0/0	0/0	0/0	0/0	0/0	0/0	0/0
Ascites	0	0	0	+	+	+	0	0	0	+	0
Swelling	+	0	0	+	+	+	0	+	+	+	+

AVN: avascular necrosis
 CF: collapsed femoral head
 NJ: narrow hip joint space
 SC: subchondral cyst
 Deformity: deformity of femoral head
 ME: marrow edema
 Effusion: hip joint effusion
 SSI: synovial part of SI joint
 LSI: ligamentous part of SI joint
 P-IF: parasymphyseal insufficiency fracture
 S-IF: sacral insufficiency fracture
 Swelling: soft tissue swelling
 R/L: right side/left side
 0 = absence; + = presence
 Number (1,2) determines its grading that described in the imaging analysis
 X: plain film evaluation were not available

Table 4. Summarized imaging findings

Imaging Findings	Result (number of hip, total = 22)
AVN	4 (18%)
Collapsed femoral head	0
Narrow joint space*	4 (22%)
Osteophyte formation*	0
Subchondral cyst	1 (4.5 %)
Deformity	0
Marrow edema	0
Hip joint effusion	17 (77%)
Grade 1	9 (41%)
Grade 2	8 (36%)
Grade 3	0 (0%)
Fluid in SI joint	
- Synovial part	2 (9.1%)
- Ligamentous part	6 (27%)
Insufficiency fracture	
- Parasymphysis	0
- Sacrum	0
Other	
- Ascites	4 (36%)
- Soft tissue swelling	8 (73%)

* n = 18, plain films were not available in 2 patients

were not available, resulting in limited evaluation of joint space.

Other imaging findings detected were ascites and soft tissue swelling. Ascites was seen in four patients (36%), and soft tissue swelling in eight patients (72%).

Discussion

AVN of bone was a well-recognized complication of SLE⁽⁸⁾. Corticosteroids had long been regarded as a risk factor⁽¹⁵⁾. The exact threshold dose to cause osteonecrosis, however, was not clear⁽¹⁶⁾.

Aranow et al⁽¹⁷⁾, in a study concerning occult AVN of the hip in SLE, stated that risk factors for clinically occult AVN included Afro-American origin, Raynaud's phenomenon, migraine headaches, and a maximal corticosteroid dose of at least 30 mg/day. In Zizic's prospective study⁽¹⁸⁾ of SLE patients reported that the most important parameter regarding steroid dosing was an average dose of at least 25 mg/day. In the present study, all patients received average steroid dose more than 35 mg/day (36-357). The two patients who developed AVN were treated with an average steroid dose of 43.2 & 49.7 mg/day, which ranked ninth

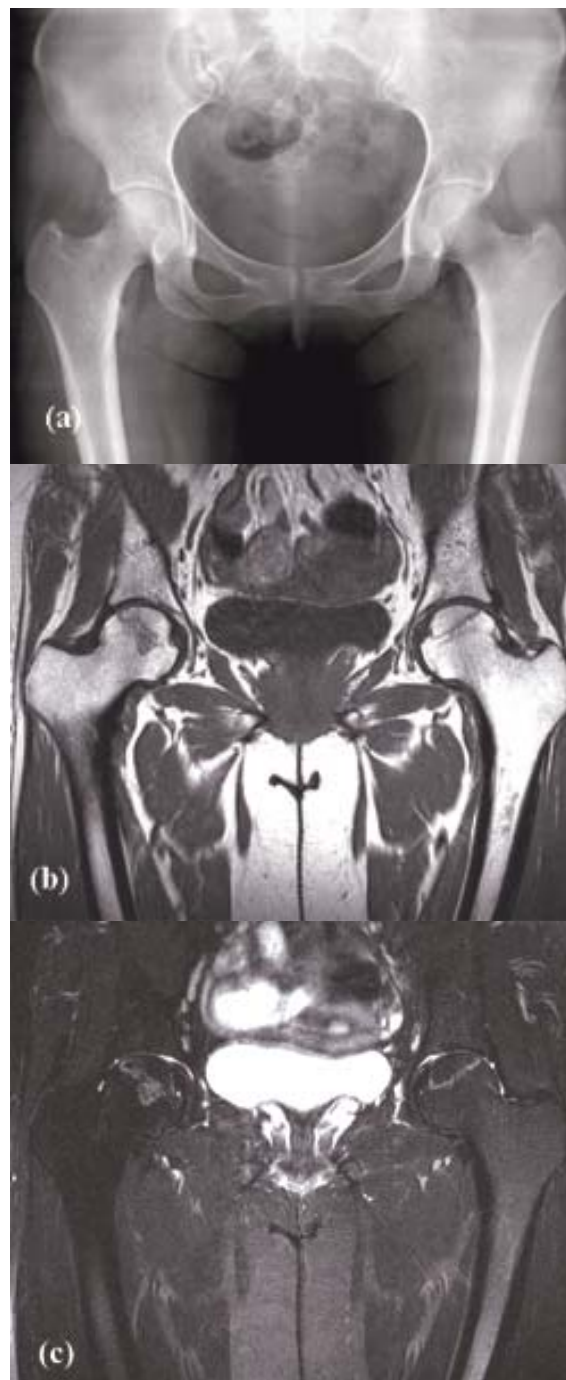


Fig. 1 Patient 2: (a) AP radiograph of the pelvis shows normal appearance of both hips. (b) Coronal T1W and (c) T2WFS images show bilateral AVN. On the right, it was defined as grade 2 by which the lesion extends beyond the epiphyseal region, and involves less than half of the rest of the femoral head. On the left, it was defined as grade 1 due to the lesion confined within the epiphyseal region

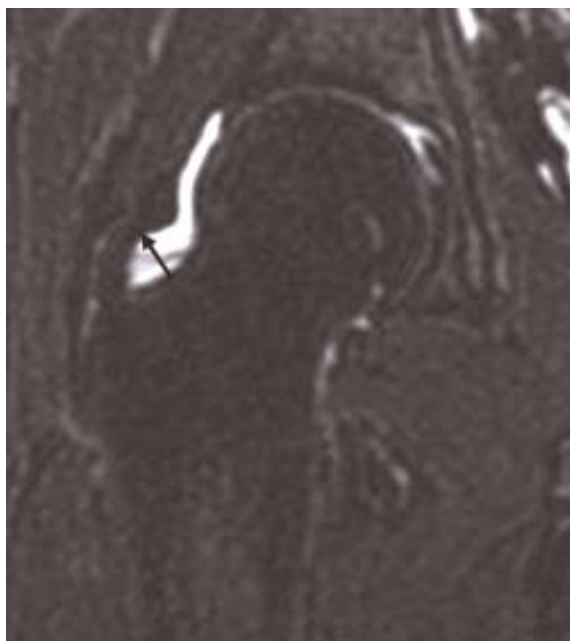


Fig. 2 Patient 3: Coronal T2WFS shows thickness of joint fluid on lateral aspect of mid femoral neck, grade 2 in this case

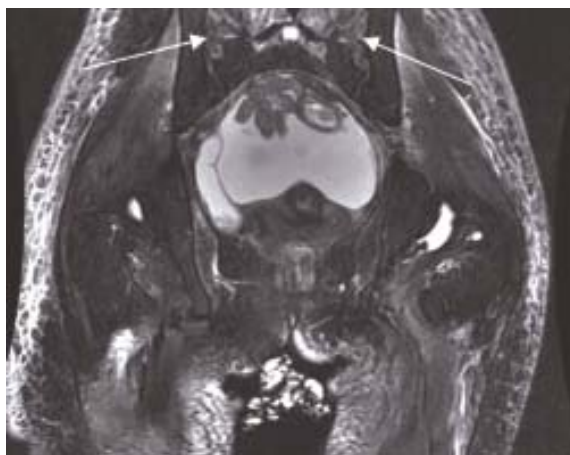


Fig. 3 Patient 5: Coronal T2WFS image show fluid in ligamentous part of both sacroiliac joints (white arrows), with fluid diffusely infiltrates subcutaneous fatty tissue. This patient has lupus nephritis. Effusion is observed in both hip joints

and seventh among all. There are three non-AVN patients who received steroid less than 43 mg/day and other six non-AVN patients received more than 49 mg/day; none of them had AVN.

The duration of steroid treatment prior to MR imaging of the presented two AVN patients (100 and 99 days) were the two longest durations among all (mean 41.6 days, range 14-100). Four patients in the present study, with the highest cumulative dose, received steroid of more than 4,500 mg prednisolone or its equivalent; two of four have AVN. In the present study, the duration of steroid treatment and cumulative steroid doses seemed to be the parameters that related to the development of AVN rather than daily average doses of steroids reported in previous studies. In a meta-analysis of 22 articles, a strong correlation between oral steroid dose and incidence of AVN was found, whereas the bolus dose was not associated with AVN⁽⁶⁾. In accordance with such analysis, the presented AVN patients did not receive pulse methylprednisolone treatment whereas two patients who received this treatment did not develop AVN.

It was well known that the key to successful management of hip osteonecrosis is early treatment, prior to the onset of subchondral fracture and cartilage damage⁽¹¹⁾. MRI is a useful modality in early pre-symptomatic diagnosis of AVN, as it depicts cellular damage prior to fracture, collapse or repair. In the present study, all patients were asymptomatic, and the authors detected AVN in four of 22 hips that did not have AVN on plain radiograph.

Mitchell et al⁽¹⁹⁾ reported that 50% of hips with advanced AVN had enough fluid to distend the recesses of the joint capsule. In contrast, a similarly large effusion was seen in only 5% of hips with lesser degrees of AVN. They proposed that joint effusion in early AVN might be due to impaired venous drainage or local hyperemia associated with the repair process. In advanced stages, degeneration of articular cartilage or collapse of the femoral head surface can irritate the synovium, thus inducing joint effusion. The investigation by Chan et al⁽²⁰⁾ indicated that the amount of joint fluid correlated well with stage of AVN. More fluid was seen in the later stages of AVN. To the contrary, the result of the present study revealed that four hips with mild & moderate grade of AVN did not have joint effusion, but all non-AVN patients developed mild to moderate joint effusion. It might be explained that three of four AVN hips were mild degree (grade 1), which might not impair venous drainage or cause local hyperemia. Because of these results, the authors concluded that joint effusion was not an associated finding of early AVN, and the presence of joint fluid did not indicate AVN.

Koo et al⁽²¹⁾ suggested that combination of

focal AVN of the femoral head and marrow edema of the proximal femur are strongly associated with hip pain in early-stage AVN even prior to collapse. Pain improvement usually parallels the resolution of edema. None of the presented 11 patients had marrow edema or hip pain, which resembled the result of the previous investigation.

Previous studies reported sacroiliitis in SLE patients, and some of them were asymptomatic^(16,22-24). In the present result, abnormal SI joints were demonstrated. Four patients had fluid in the ligamentous part of bilateral SI joints and one of them also had fluid in the synovial part. These findings could be early signs of sacroiliitis, but the patients did not have any symptom at the time of the present study. However, it was important to rule out infective cause of the fluid since SLE patients can develop septic arthritis particularly during steroid treatment⁽²⁴⁾.

Joints, muscles, ligaments, and tendons were the most commonly involved structures in SLE, with these structures affected in 53% to 95% of patients. Two patients in the present study had mildly narrow hip joint spaces with a moderate amount of joint effusion. These findings were likely to be synovitis of the hips, which had been reported by Egol et al in 2001⁽²⁴⁾. However, synovitis about the hips in SLE was rare, compared to other joints. Therefore, any hip or groin pain in a SLE patient should initially be considered osteonecrosis.

Ramsey-Goldman et al⁽²⁵⁾ reported that fractures occurred in 12.3% of lupus patients. There was nearly a 5-fold increase in fracture occurrence in the women with lupus compared with women from the U.S. population. Older age at lupus diagnosis and longer use of corticosteroids, were associated with time from lupus diagnosis to fracture. In the present study, the authors collected data about pelvic insufficiency fracture and found that no patient had these findings. It might be explained that the presented patients were new cases of SLE (short time from diagnosis) and most of them were young, with a mean age of 27.8 years.

Subchondral cyst is referred to as synovial cyst or subarticular pseudocyst. Its etiology may be bone necrosis, which allowed pressure-induced intrusion of synovial fluid into subchondral bone, or in conditions with synovial inflammation. It could be found in many diseases such as osteoarthritis, rheumatoid arthritis, osteonecrosis, or CPPD⁽²⁶⁾. Small subchondral cyst at right acetabulum was found in one patient, who had only minimal joint effusion. It could be due to synovial inflammation, which might coexist SLE.

The present result demonstrated that all patients with ascites and/or generalized soft tissue swelling had lupus nephritis, whereas one patient without lupus nephritis did not have ascites or soft tissue swelling. These results correspond to the results of Weinstein and Noyer's⁽²⁷⁾ who reviewed and stated that ascites in SLE was rarely massive; and either accompanies the typical manifestations of active disease or results from nephrotic syndrome, protein-losing enteropathy, constrictive pericarditis, and conditions unrelated to lupus⁽²¹⁾.

Certain limitations in the present study should be acknowledged. First limitation is the small sample size, therefore the data of steroid treatment and imaging findings cannot be used for statistical analysis or comparison between the AVN and non-AVN groups. Secondly, three patients had prior treatment from other hospitals, which may have resulted in inaccurate records of steroid dosage. Thirdly, plain radiographs of two patients were not available.

The authors concluded that SLE patients without hip pain might have AVN of the hips. Joint effusion and marrow edema do not associate with early AVN, and the authors can find early AVN without joint effusion. Cumulative doses of prednisolone-equivalent steroid treatment and the duration of steroid treatment seems to relate to AVN in the present study. However, larger numbers of cases, prospective clinical data, and long-term follow-up will help better evaluate AVN in SLE patients, as well as evaluate whether MRI has benefit as a screening test for patients at risk of AVN.

References

1. Oinuma K, Harada Y, Nawata Y, Takabayashi K, Abe I, Kamikawa K, et al. Osteonecrosis in patients with systemic lupus erythematosus develops very early after starting high dose corticosteroid treatment. *Ann Rheum Dis* 2001; 60: 1145-8.
2. Houssiau FA, N'Zesusseu TA, Depresseux G, Maldague BE, Malghem J, Devogelaer JP, et al. Magnetic resonance imaging-detected avascular osteonecrosis in systemic lupus erythematosus: lack of correlation with antiphospholipid antibodies. *Br J Rheumatol* 1998; 37: 448-53.
3. Indira D, Snehal S, Rani C. Glucocorticosteroid-induced osteonecrosis: lessons for the dermatologist. *Indian J Dermatol Venereol Leprol* 2000; 66: 173-81.
4. Nagasawa K, Tada Y, Koarada S, Horiuchi T, Tsukamoto H, Murai K, et al. Very early development of steroid-associated osteonecrosis of femo-

- ral head in systemic lupus erythematosus: prospective study by MRI. *Lupus* 2005; 14: 385-90.
5. Miyanishi K, Yamamoto T, Iriya T, Motomura G, Jingushi S, Sueishi K, et al. Effects of different corticosteroids on the development of osteonecrosis in rabbits. *Rheumatology (Oxford)* 2005; 44: 332-6.
 6. Zonana-Nacach A, Barr SG, Magder LS, Petri M. Damage in systemic lupus erythematosus and its association with corticosteroids. *Arthritis Rheum* 2000; 43: 1801-8.
 7. Sakamoto M. A prospective study of steroid-induced osteonecrosis by MRI screening. *Nippon Seikeigeka Gakkai Zasshi* 1994; 68: 367-78.
 8. Mok CC, Lau CS, Wong RW. Risk factors for avascular bone necrosis in systemic lupus erythematosus. *Br J Rheumatol* 1998; 37: 895-900.
 9. Hungerford DS, Jones LC. Asymptomatic osteonecrosis: should it be treated? *Clin Orthop Relat Res* 2004; 429: 124-30.
 10. Tingart M, Bathis H, Perlick L, Lerch K, Luring C, Grifka J. Therapy of femoral head osteonecrosis: results of a national survey. *Z Orthop Ihre Grenzgeb* 2004; 142: 553-8.
 11. Khanna AJ, Yoon TR, Mont MA, Hungerford DS, Bluemke DA. Femoral head osteonecrosis: detection and grading by using a rapid MR imaging protocol. *Radiology* 2000; 217: 188-92.
 12. Theodorou DJ, Malizos KN, Beris AE, Theodorou SJ, Soucacos PN. Multimodal imaging quantitation of the lesion size in osteonecrosis of the femoral head. *Clin Orthop Relat Res* 2001; 54-63.
 13. Saini A, Saifuddin A. MRI of osteonecrosis. *Clin Radiol* 2004; 59: 1079-93.
 14. Huang GS, Chan WP, Chang YC, Chang CY, Chen CY, Yu JS. MR imaging of bone marrow edema and joint effusion in patients with osteonecrosis of the femoral head: relationship to pain. *AJR Am J Roentgenol* 2003; 181: 545-9.
 15. Mok MY, Farewell VT, Isenberg DA. Risk factors for avascular necrosis of bone in patients with systemic lupus erythematosus: is there a role for antiphospholipid antibodies? *Ann Rheum Dis* 2000; 59: 462-7.
 16. Klingenstein G, Levy RN, Kornbluth A, Shah AK, Present DH. Inflammatory bowel disease related osteonecrosis: report of a large series with a review of the literature. *Aliment Pharmacol Ther* 2005; 21: 243-9.
 17. Aranow C, Zelicof S, Leslie D, Solomon S, Barland P, Norman A, et al. Clinically occult avascular necrosis of the hip in systemic lupus erythematosus. *J Rheumatol* 1997; 24: 2318-22.
 18. Zizic TM, Marcoux C, Hungerford DS, Dansereau JV, Stevens MB. Corticosteroid therapy associated with ischemic necrosis of bone in systemic lupus erythematosus. *Am J Med* 1985; 79: 596-604.
 19. Mitchell DG, Rao V, Dalinka M, Spritzer CE, Geftter WB, Axel L, et al. MRI of joint fluid in the normal and ischemic hip. *AJR Am J Roentgenol* 1986; 146: 1215-8.
 20. Chan WP, Liu YJ, Huang GS, Jiang CC, Huang S, Chang YC. MRI of joint fluid in femoral head osteonecrosis. *Skeletal Radiol* 2002; 31: 624-30.
 21. Koo KH, Ahn IO, Kim R, Song HR, Jeong ST, Na JB, et al. Bone marrow edema and associated pain in early stage osteonecrosis of the femoral head: prospective study with serial MR images. *Radiology* 1999; 213: 715-22.
 22. Lo Y, Liou B, Tsaii P. Different causes of sacroiliitis associated with systemic lupus erythematosus: report of two cases. *J Int Med Taiwan* 2001; 12: 36-40.
 23. Kohli M, Bennett RM. Sacroiliitis in systemic lupus erythematosus. *J Rheumatol* 1994; 21: 170-1.
 24. Egol KA, Jazrawi LM, DeWal H, Su E, Leslie MP, Di Cesare PE. Orthopaedic manifestations of systemic lupus erythematosus. *Bull Hosp Jt Dis* 2001; 60: 29-34.
 25. Ramsey-Goldman R, Dunn JE, Huang CF, Dunlop D, Rairie JE, Fitzgerald S, et al. Frequency of fractures in women with systemic lupus erythematosus: comparison with United States population data. *Arthritis Rheum* 1999; 42: 882-90.
 26. Dahnert W. *Radiology review manual*. 5th ed. Philadelphia: Lippincott Williams & Wilkins; 2003: 15.
 27. Weinstein PJ, Noyer CM. Rapid onset of massive ascites as the initial presentation of systemic lupus erythematosus. *Am J Gastroenterol* 2000; 95: 302-3.

ภาวะกระดูกตายจากการขาดเลือดของข้อสะโพกโดยไม่มีอาการ ในผู้ป่วยโรค SLE ที่ได้รับการวินิจฉัยเป็นครั้งแรก

สุภานีวรรณ เชาววิศิษฐ, รุ่งวดี เต็นปรีชาวงศ์, ปารวี สุวรรณาลัย, สุชีลา จันทรวิทยาอุทิศ

ได้ทำการศึกษาแบบไปข้างหน้า เกี่ยวกับภาวะกระดูกตายจากการขาดเลือดของข้อสะโพกโดยไม่มีอาการ ในผู้ป่วยโรค SLE ที่ได้รับการวินิจฉัยเป็นครั้งแรกที่โรงพยาบาลรามธิบดี หรือที่โรงพยาบาลอื่นในเวลาไม่เกิน 1 เดือน ตั้งแต่เดือนกุมภาพันธ์ถึงพฤศจิกายน พ.ศ. 2549 โดยศึกษาเปรียบเทียบกับปริมาณของยาสเตียรอยด์ที่ได้รับ ในแง่ของปริมาณยาทั้งหมดที่ได้รับ, ปริมาณยาต่อวัน, ปริมาณยาต่อน้ำหนักตัวต่อวัน และระยะเวลาที่ได้รับยาก่อน การตรวจข้อสะโพกด้วยคลื่นแม่เหล็กไฟฟ้า (MRI) หากผู้ป่วยได้รับยากลุ่มสเตียรอยด์ตัวอื่นจะทำการเทียบกลับมา เป็นปริมาณของยาเพรดนิโซโลน รวมทั้งได้ถ่ายภาพรังสีของข้อสะโพกเพื่อช่วยในการประเมินภาวะข้อเสื่อมร่วมด้วย พบว่ามีผู้ป่วยรวม 11 ราย (22 ข้อสะโพก) ในการศึกษา ทั้งหมดเป็นหญิง อายุเฉลี่ย 27.8 ปี พบมีภาวะกระดูกตาย 2 ราย (4 ข้อสะโพก) ทั้ง 4 ข้อมีกระดูกตายบริเวณ epiphysis ของกระดูกต้นขา โดยไม่มีการยุบของหัวกระดูก, ไม่มี น้ำในช่องข้อ, ไม่มีไขกระดูกบวม หรือภาวะอื่นใดร่วมด้วย ในขณะที่ 17 ข้อสะโพกที่ไม่มีกระดูกตายกลับพบน้ำใน ช่องข้อปริมาณน้อยถึงปานกลาง ผู้ป่วยทั้ง 2 รายที่มีกระดูกตายเป็นผู้ที่มีระยะเวลาการได้รับยาสเตียรอยด์ นานที่สุดก่อนทำ MRI (105 และ 99 วัน; ค่าเฉลี่ย 40 วัน) และมีปริมาณยาทั้งหมดที่ได้รับสูงสุด (4,920 และ 4,540 มิลลิกรัม-เพรดนิโซโลน; ค่าเฉลี่ย 3,402 มิลลิกรัม-เพรดนิโซโลน) ผลการศึกษาชี้แนะว่า ผู้ป่วย SLE ที่ไม่มีอาการ ปวดข้อสะโพก สามารถมีภาวะกระดูกตาย การมีน้ำในช่องข้อและไขกระดูกบวมไม่จำเป็นต้องพบร่วม หรือ เป็น อาการเริ่มต้นของภาวะกระดูกตาย ระยะเวลาที่นานของการได้รับยาสเตียรอยด์และปริมาณยาทั้งหมดที่มาก พบร่วมกับการมีกระดูกตายในการศึกษานี้ อย่างไรก็ตามการศึกษานี้มีจำนวนผู้ป่วยที่มากกว่านี้ จะสามารถช่วยให้ประเมินภาวะกระดูกตายของข้อสะโพกได้ดีขึ้น รวมทั้งประเมินการใช้ MRI ในการตรวจหา ภาวะนี้ตั้งแต่ยังไม่มีอาการ ซึ่งจะช่วยให้การรักษาและการปรับยาเป็นไปได้ดีขึ้น
