

## Case Report

# Treatment of Femoral Fracture through the Sliding Screw Portal Following Fixation of the Femoral Neck Fracture

Anupong Laohapoonrungsee MD\*, Yuddhasert Sirirungruangsarn MD\*,  
Theerachai Apivatthakakul MD\*, Prasit Wongtreerachtanachai MD\*

\* Department of Orthopaedics, Faculty of Medicine, Chiang Mai University, Chiang Mai

---

*The authors report a case of secondary femoral fracture through the sliding hip screw portal following fixation of the femoral neck fracture. The femoral neck and subtrochanteric fracture was successfully treated by superimposing a trochanteric stabilization plate (TSP) onto the regular sliding hip screw.*

**Keywords:** Femoral neck fracture, Subtrochanteric fracture, Sliding hip screw, Trochanteric stabilizing plate

*J Med Assoc Thai* 2007; 90 (6): 1234-8

**Full text. e-Journal:** <http://www.medassocthai.org/journal>

---

Femoral neck fracture is common in the elderly, with only 2-3% found in patients younger than 50 years<sup>(1,2)</sup>. The primary goal of fracture treatment is to return the patient to the pre-injury level of function, which can be achieved with surgery. Patient age and expectation should be considered in choosing the appropriate procedure to minimize the risk of complication.

For patients older than 65 years, most of them are treated with some form of prosthetic replacement<sup>(3)</sup>. In the younger age group, this injury often results from high-energy trauma leading in fracture comminution and greater disruption of blood supply to the femoral head. Immediate anatomical reduction and internal fixation should be attempted to reduce the risk of avascular necrosis and nonunion. If this is not possible or there is posterior neck comminution, then open reduction and a bone grafting procedure should be considered<sup>(4,5)</sup>. Choice of implants for internal fixation includes sliding hip screw, cannulated screws, and pins. From several studies, the use of an implant with a side-plate or pins shows no advantage or better stabilization over screws<sup>(6,7,8)</sup>. Multiple cannulated screws fixation is said to be the least difficult type of internal

fixation to perform and is preferred by most surgeons<sup>(9)</sup>. However, determination of the optimum number or type of screw is still controversial<sup>(8,10,11)</sup>.

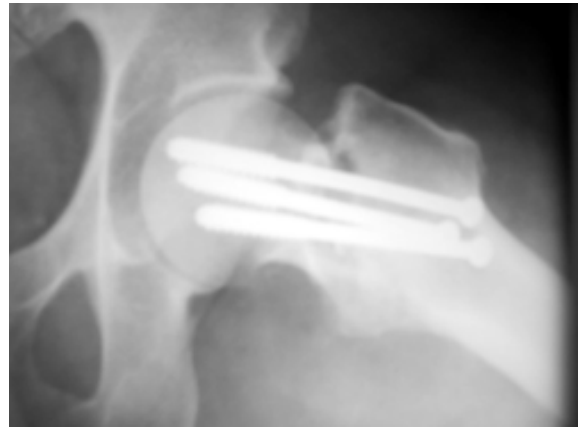
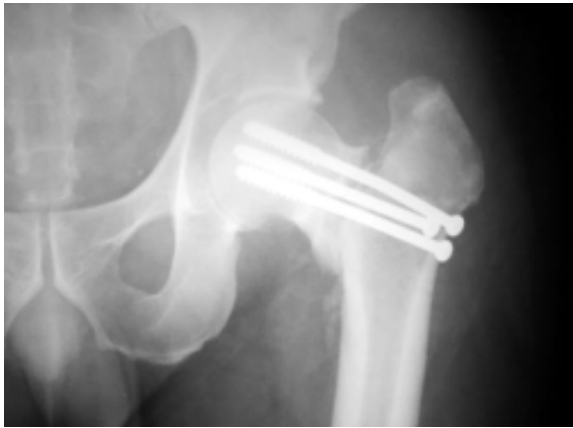Dynamic hip screw (DHS), which is an alternative method of femoral neck fracture fixation, provides good results with respect to fracture healing and a low rate of complications<sup>(8,9)</sup>. This implant is commonly used in intertrochanteric fracture and most of the reported complications have been predominantly associated with cut-out of the lag screw through the femoral head<sup>(12-15)</sup>. In the present study, the authors report an uncommon secondary femoral diaphyseal fracture through the portal of the hip screw following the fixation of the femoral neck fracture

### Case Report

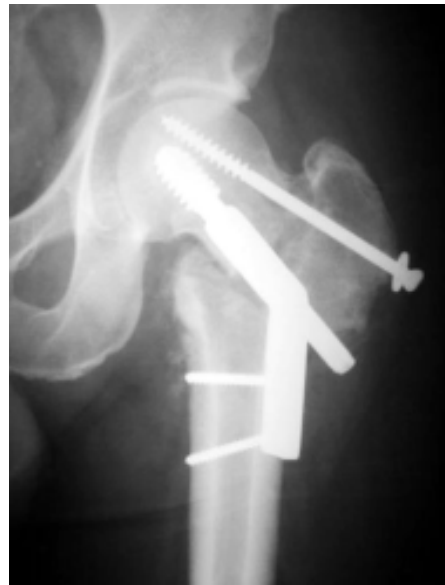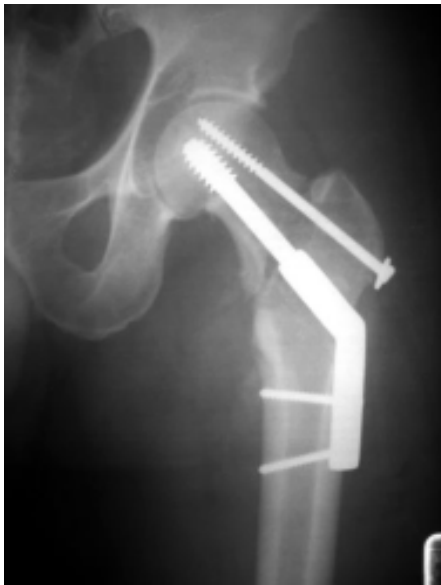A 47 years old male first visited the outpatient clinic with a complaint of limb shortening. He had undergone surgery two weeks before for femoral neck fracture on the day of injury. Radiograph revealed an unacceptable varus angulation and distally displaced femoral head with three cannulated cancellous screws fixing the fracture (Fig. 1). To correct this deformity, the fixation was removed and the fracture was realigned. A two-hole side-plate and an anterotational screw were chosen to avoid the multiple drill holes from the previous operation (Fig. 2). The patient was allowed to ambulate by crutches in toe-touch gait pattern on the second day after the operation.

---

Correspondence to : Laohapoonrungsee A, Department of Orthopaedics, Faculty of Medicine, Chiang Mai University, Chiang Mai 50200, Thailand. Phone: 053-9455-424, Fax: 053-217-144, E-mail: [alaohapo@mail.med.cmu.ac.th](mailto:alaohapo@mail.med.cmu.ac.th)



**Fig. 1** Varus and distal displacement of the femoral head on the first visit

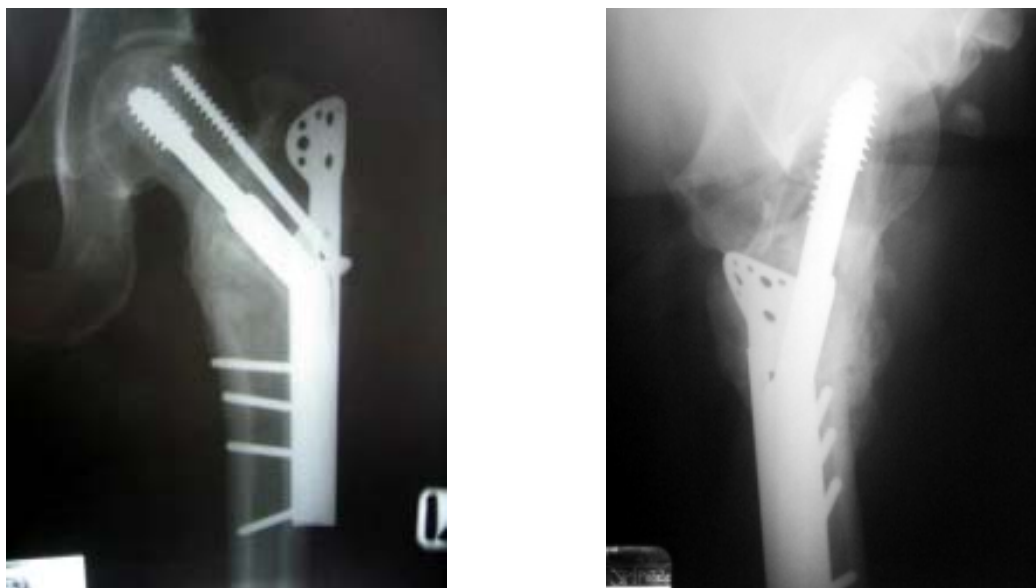


**Fig. 2** After removal of the cannulated screws, the fracture was stabilized with DHS and an anterotational screw

**Fig. 3** Subtrochanteric or reverse obliquity intertrochanteric fracture with medial displacement at 3 weeks after DHS fixation

Three weeks after the revision surgery, the patient experienced marked pain in his left hip and was unable to bear weight on the extremity. Roentgenogram demonstrated femoral fracture through the sliding screw portal with medial displacement (Fig. 3). Choice of an internal fixation device was discussed and the operative procedure was planned. The operation was performed on a fracture table with slight traction of the limb to reduce the secondary subtrochanteric fracture. The femoral neck fracture was temporarily fixed with

multiple Kirschner wires during removal of the anterotational screw and exchange of the DHS side-plate. Then a trochanteric stabilization plate was superimposed onto the new four-hole side-plate and the anterotational screw was reapplied. The medial fracture gap was filled with corticocancellous chip graft. The patient was discharged a few days later. He had been walking with the toe-touch gait pattern, gradually increasing in weight bearing. The bone healing can be observed in the follow up films.



**Fig. 4** At fifteen months follow up, the femoral neck and the reverse obliquity intertrochanteric fractures healed uneventfully

The secondary fracture healed at ten weeks post operation. There was no avascular necrosis or femoral head collapse at fifteen months of follow up (Fig. 4).

#### Discussion

In the treatment of displaced femoral neck fracture, the aim is to obtain a stable bony support of the femoral head on the femoral neck. The fixation increases stability by compressing the fracture and maintaining the reduction by neutralizing forces acting on the hip. In a biomechanic study, Rubin found that the comminution of the femoral neck and poor reduction directly affect the stability of fixation<sup>(16)</sup>. Selvan and Gurusamy demonstrated that the screw positioning in multiple screws fixation plays a major role in preventing femoral head displacement and non-union of the fracture<sup>(17,18)</sup>. Zlowodzki recommended guidelines for femoral neck fixation that include adequate reduction, anterior capsulotomy, use of three cannulated screws, parallel alignment of screws, an inverted triangular screw pattern, and placement of the most inferior screw close to the inferior cortex<sup>(19)</sup>. Schmidt suggested a screws placement guideline as follows: the first distalmost screw shaft should rest on the supporting medial neck, with its thread fixing the inferior femoral head to prevent distal head migration. The second screw should be placed proximally posteriorly

in the midhead level. This screw rests on the posterior cortex of the distal fragment preventing the posterior head migration. The third and fourth screws are placed in an inverted triangular and diamond pattern respectively as recommended<sup>(20)</sup>. On the contrary, Toh showed that the number and position of the screws in the femoral neck did not significantly affect the outcome of an internal fixation. The inadequacy of fracture reduction was directly related to fixation failure<sup>(11)</sup>. In Parker's meta-analysis, there was no clinical evidence that using three or more screws is superior to the use of two<sup>(8)</sup>. Krastman revealed adequate stability of two cannulated screws in fixation of an undisplaced fracture. However, in the displaced group, a more stable implant (e.g. DHS) was recommended to avoid redisplacement of the fracture<sup>(10)</sup>. The failure rate of femoral neck fractures fixed with multiple cannulated screws was reported from 5-10% for undisplaced and 20-40% for displaced fracture<sup>(21)</sup>. In this case, the femoral head migration could have occurred from the poor alignment of reduction and improper screw position. The posterior neck comminution was minimal and did not seem to affect the stability of fracture fixation.

In 1982, Howard and Davies reported subtrochanteric fracture through the lower Garden screw hole after fixation of the femoral neck fracture. In their case, the large screw hole may weaken the bony cortex. The presence of a screw or a nail without a neutralization

plate may produce bending moment around the lateral femoral cortex at the site of insertion. Either or both of the above mechanisms are supposed to be the etiology of this complication<sup>(22)</sup>. Pelvet reviewed 84 femoral neck fractures fixed by three cannulated screws in triangular and inverted triangular pattern. Three subtrochanteric fractures were found only in the triangular pattern. The two inferior screws in this fixation pattern created a stress riser in the subtrochanteric region inducing a fracture in the weakened bone<sup>(23)</sup>. Fracture through the sliding screw portal is rare. Although the tunnel can weaken the bony strength, the bending moment is neutralized by the side-plate. In the present study, the inferior screw hole was included into the sliding screw hole and might not be the stress riser in the proximal femur region. In the authors' opinion, inaccurate angle of the sliding screw in slightly varus or valgus position may produce an abnormal moment following application of the side-plate and result in subtrochanteric fracture in the patient.

This type of fracture can be classified as a reverse obliquity intertrochanteric fracture. This fracture combination is considered as a difficult condition to treat. The presence of femoral neck fracture affects the choice of fixation device. Any method used must be able to maintain the reduction of the femoral neck fracture as well as hold the intertrochanteric fracture. Willoughby showed 11% failure rate of the DHS in management of reverse obliquity intertrochanteric fracture<sup>(24)</sup>. Kyle concluded that a standard sliding hip screw should not be used in fixation of the intertrochanteric fracture with associate femoral neck fracture due to its high failure rate<sup>(25)</sup>. The trochanteric stabilizing plate (TSP), developed for use with the DHS, can reduce the medialization of the distal fragment in unstable intertrochanteric fracture without giving stress to the femoral shaft. It allows the sliding screw to slide freely, thereby allowing controlled fracture impaction<sup>(14)</sup>. Good results with the use of the TSP in unstable intertrochanteric fracture have been supported by several studies<sup>(26-28)</sup>. To the best of the authors' knowledge, there has been no English report about its use to treat such a fracture, as reported in the presented case. Bony union at both sites is achieved uneventfully with this simple implant and technique.

### Conclusion

Femoral fracture occurring through the sliding hip screw portal is a rare complication following DHS fixation for femoral neck fracture. When this complication occurs, the treatment should be concerned about

both fracture sites. The implant must be easily applied to prevent deterioration of the femoral neck fracture reduction, allow fracture impaction and non-interference with hip function, and it should be strong enough to prevent displacement of the femoral shaft. The TSP can serve all these purposes and should be an implant of choice in treatment of this uncommon condition.

### References

1. Berglund-Roden M, Swierstra BA, Wingstrand H, Thorngren KG. Prospective comparison of hip fracture treatment. 856 cases followed for 4 months in The Netherlands and Sweden. *Acta Orthop Scand* 1994; 65: 287-94.
2. Damany DS, Parker MJ, Chojnowski A. Complications after intracapsular hip fractures in young adults. A meta-analysis of 18 published studies involving 564 fractures. *Injury* 2005; 36: 131-41.
3. Robinson CM, Saran D, Annan IH. Intracapsular hip fractures. Results of management adopting a treatment protocol. *Clin Orthop Relat Res* 1994; 83-91.
4. Kofoed H. Femoral neck fractures in young adults. *Injury* 1982; 14: 146-50.
5. Meyers MH, Harvey JP Jr, Moore TM. Treatment of displaced subcapital and transcervical fractures of the femoral neck by muscle-pedicle-bone graft and internal fixation. A preliminary report on one hundred and fifty cases. *J Bone Joint Surg Am* 1973; 55: 257-74.
6. Lindequist S, Malmqvist B, Ullmark G. Fixation of femoral neck fracture. Prospective comparison of von Bahr screws, Gouffon screws, and Hessel pins. *Acta Orthop Scand* 1989; 60: 293-8.
7. Olerud C, Rehnberg L, Hellquist E. Internal fixation of femoral neck fractures. Two methods compared. *J Bone Joint Surg Br* 1991; 73: 16-9.
8. Parker MJ, Blundell C. Choice of implant for internal fixation of femoral neck fractures. Meta-analysis of 25 randomised trials including 4,925 patients. *Acta Orthop Scand* 1998; 69: 138-43.
9. Bhandari M, Devereaux PJ, Swiontkowski MF, Tornetta P 3rd, Obremskey W, Koval KJ, et al. Internal fixation compared with arthroplasty for displaced fractures of the femoral neck. A meta-analysis. *J Bone Joint Surg Am* 2003; 85-A: 1673-81.
10. Krastman P, van den Bent RP, Krijnen P, Schipper IB. Two cannulated hip screws for femoral neck fractures: treatment of choice or asking for trouble? *Arch Orthop Trauma Surg* 2006; 126: 297-303.

11. Toh EM, Sahni V, Acharya A, Denton JS. Management of intracapsular femoral neck fractures in the elderly; is it time to rethink our strategy? *Injury* 2004; 35: 125-9.
12. Clawson DK. Trochanteric fractures treated by the sliding screw plate fixation method. *J Trauma* 1964; 4: 737-52.
13. Davis TR, Sher JL, Horsman A, Simpson M, Porter BB, Checketts RG. Intertrochanteric femoral fractures. Mechanical failure after internal fixation. *J Bone Joint Surg Br* 1990; 72: 26-31.
14. Mainds CC, Newman RJ. Implant failures in patients with proximal fractures of the femur treated with a sliding screw device. *Injury* 1989; 20: 98-100.
15. Yoshimine F, Latta LL, Milne EL. Sliding characteristics of compression hip screws in the intertrochanteric fracture: a clinical study. *J Orthop Trauma* 1993; 7: 348-53.
16. Rubin R, Trent P, Arnold W, Burstein A. Knowles pinning of experimental femoral neck fractures: biomechanical study. *J Trauma* 1981; 21: 1036-9.
17. Selvan VT, Oakley MJ, Rangan A, Al Lami MK. Optimum configuration of cannulated hip screws for the fixation of intracapsular hip fractures: a biomechanical study. *Injury* 2004; 35: 136-41.
18. Gurusamy K, Parker MJ, Rowlands TK. The complications of displaced intracapsular fractures of the hip: the effect of screw positioning and angulation on fracture healing. *J Bone Joint Surg Br* 2005; 87: 632-4.
19. Zlowodzki M, Weening B, Petrisor B, Bhandari M. The value of washers in cannulated screw fixation of femoral neck fractures. *J Trauma* 2005; 59: 969-75.
20. Schmidt AH, Asnis SE, Haidukewych G, Koval KJ, Thorngren KG. Femoral neck fractures. *Instr Course Lect* 2005; 54: 417-45.
21. Lu-Yao GL, Keller RB, Littenberg B, Wennberg JE. Outcomes after displaced fractures of the femoral neck. A meta-analysis of one hundred and six published reports. *J Bone Joint Surg Am* 1994; 76: 15-25.
22. Howard CB, Davies RM. Subtrochanteric fracture after Garden screw fixation of subcapital fractures. *J Bone Joint Surg Br* 1982; 64: 565-7.
23. Pelet S, Leyvraz PF, Garofalo R, Borens O, Mouhsine E. Sub- or intertrochanteric fracture following screw fixation of an intracapsular proximal femoral fracture: true complication or technical error? *Swiss Surg* 2003; 9: 82-6.
24. Willoughby R. Dynamic hip screw in the management of reverse obliquity intertrochanteric neck of femur fractures. *Injury* 2005; 36: 105-9.
25. Kyle RF, Ellis TJ, Templeman DC. Surgical treatment of intertrochanteric hip fractures with associated femoral neck fractures using a sliding hip screw. *J Orthop Trauma* 2005; 19: 1-4.
26. Madsen JE, Naess L, Aune AK, Alho A, Ekeland A, Stromsoe K. Dynamic hip screw with trochanteric stabilizing plate in the treatment of unstable proximal femoral fractures: a comparative study with the Gamma nail and compression hip screw. *J Orthop Trauma* 1998; 12: 241-8.
27. Lee PC, Yu SW, Hsieh PH, Chuang TY, Tai CL, Shih CH. Treatment of early cut-out of a lag screw using a trochanter supporting plate: 11 consecutive patients with unstable intertrochanteric fractures. *Arch Orthop Trauma Surg* 2004; 124: 119-22.
28. Babst R, Renner N, Biedermann M, Rosso R, Heberer M, Harder F, et al. Clinical results using the trochanter stabilizing plate (TSP): the modular extension of the dynamic hip screw (DHS) for internal fixation of selected unstable intertrochanteric fractures. *J Orthop Trauma* 1998; 12: 392-9.

---

การรักษาระดุกต้นขาที่หักผ่านรูสกรูที่ใช้ในการยึดตรึงกระดูกต้นขาส่วนคอรายงานผู้ป่วย 1 ราย

อนุพงษ์ เลหาพูนรังษี, ยุทธเสริฐ ศิริรุ่งเรืองสาร, ธีรชัย อภิวรรณกุล, ประสิทธิ์ วงศ์ตรีรัตนชัย

กระดูกพีเมอร์ส่วนต้นหักผ่านช่องสกรูของ dynamic hip screw ภายหลังการยึดตรึงกระดูกสะโพกส่วนคอหักเป็นปัญหาแทรกซ้อนที่พบได้ไม่บ่อย การรักษาคงต้องคำนึงถึงกระดูกสะโพกส่วนคอที่หัก รวมทั้งส่วนที่หักใหม่ การศึกษานี้เป็นการรายงานปัญหาแทรกซ้อนและการผ่าตัดรักษาภาวะดังกล่าวในผู้ป่วย 1 ราย