

Case Report

Primary Pigmented Nodular Adrenocortical Disease with Synaptophysin Immunoreactivity in Two Thai Children

Narumon Patarakijvanich MD*,
Kanita Kayasut MD**, Winyou Mitarnun MD**,
Sakda Pathrapinyokul MD***, Surasak Sangkhathat Na Ayudya MD***

This paper was originally an oral presentation at The Second Biennial Scientific Meeting of the Asia Pacific Pediatric Endocrine Society, 11-13 November 2002, Cairns, Australia

* Department of Pediatrics, Faculty of Medicine, Prince of Songkla University, Hat Yai, Songkhla

** Department of Pathology, Faculty of Medicine, Prince of Songkla University, Hat Yai, Songkhla

*** Department of Surgery, Faculty of Medicine, Prince of Songkla University, Hat Yai, Songkhla

This paper reports the cases of two Thai children diagnosed with primary pigmented nodular adrenocortical disease (PPNAD). The first was a thirteen and a half year old male who presented with Cushing syndrome for three years and severe osteoporosis. He had hypercortisolemia, a non-suppressible dexamethasone suppression test, and low serum ACTH. A CT scan showed slight enlargement of both adrenal glands. A bilateral adrenalectomy was performed. The second case was a thirteen-year old female who presented with mild Cushing syndrome for one year with paradoxical response to high-dose dexamethasone suppression test. An MRI revealed suspected microadenoma of the left adrenal gland. Blood sampling showed a higher cortisol level from the left adrenal vein than from the right. A left adrenalectomy was performed, followed by a right adrenalectomy four months later. The pathologies were compatible with PPNAD.

Immunostaining for synaptophysin was done in both patients. The cells in the adrenocortical micronodules of both cases were stained intensely with antiserum for synaptophysin, whereas the surrounding adrenal cortex did not.

Keywords: PPNAD, Cushing syndrome, Thai children, Synaptophysin immunoreactivity

J Med Assoc Thai 2007; 90 (6): 1208-13

Full text. e-Journal: <http://www.medassocthai.org/journal>

Primary pigmented nodular adrenocortical disease, or PPNAD, is a rare form of Cushing syndrome in children. It occurs sporadically or as a component of Carney complex, an autosomal dominant neoplasia syndrome. PPNAD is characterized by lipofuscin-containing, autonomously functioning, cortisol-producing nodules in the adrenal cortex of the bilateral adrenal glands. The pathogenesis of PPNAD is not well established. The genetic aspect of the disease and the subsequent cellular functions are currently under investigation. As PPNAD is an exceedingly rare disease, there have only been scattered reports of individual cases or small series of patients from various countries over

the last 50 years⁽¹⁻¹²⁾. Through the present study the authors are adding to the record two cases of children with PPNAD from Thailand along with their clinical characteristics, pathological and microscopic findings, and immunostaining for synaptophysin.

Case Report

Case one

A thirteen and a half year old male, who had been growing increasingly obese for three years and had abdominal red striae for one year. He presented with epigastric and back pain for five months prior to admission. There was no family history of Carney complex. He was 121 cm tall and 36 kg in weight. He had a cushingoid appearance, moon face, truncal obesity, a prominent buffalo hump and supraclavicular fat pads. His blood pressure was 170/140 mmHg. His eye grounds

Correspondence to : Patarakijvanich N, Department of Pediatrics, Faculty of Medicine, Prince of Songkla University, Hat Yai, Songkhla 90110, Thailand. Phone: 074-451-250, Fax: 074-212-912, E-mail: pnarumon@medicine.psu.ac.th

were normal. The thyroid gland was not enlarged. Abdominal examination showed a fatty abdomen with multiple reddish striae. He had pubic hair stage 3, genital development stage 1 and testicular volume of 3 mL. His skin was normal without spotty pigmentation or skin myxoma. There were no other signs of Carney complex.

The laboratory investigations were Hb 15.1 g/dL, Hct 45%, WBC 13,600 cells/mm³, PMN 71%, lymphocytes 16%, monocytes 13%, platelets 370,000 cells/mm³, serum potassium level 2.5 mmol/L, and random blood sugar level 5.2 mmol/L (94 mg/dL).

A Roentgenography of the thoracic vertebrae showed severe osteoporosis and collapse of vertebrae. The bone age was 11 years.

Endocrine testing showed serum cortisol level of 33.9 mg/dL (normal 5-25), serum testosterone 1.08 ng/mL (normal 3.6-9.9), and serum ACTH 9.6 pg/mL (normal 6-56.7). A dexamethasone suppression test was performed with dexamethasone 20 µg/kg/day for two days followed by 80 µg/kg/day for two days. A twenty-four hour urine level of 17 OHCS, 17 KGS, and 17 KS at the baseline, and following low and high doses dexamethasone was measured, and showed no suppression.

Computed tomographic scanning of the adrenal glands without contrast enhancement revealed slight enlargement of both the adrenal glands without focal mass. The enhanced thin slice CT scanning at the adrenal region performed one month later showed a focal nodular enlargement of the anterior limb of both adrenal glands, with the left gland larger than the right. The left adrenal nodule was 0.8 x 2.4 x 2.4 cm in size, and the right adrenal nodule 0.5 x 1.2 x 1.2 cm. The enhanced adrenal nodule showed an internal low density; higher in density than water and less than the surrounding adrenal tissue.

The results of the investigation, with the lack of dexamethasone suppression and low serum ACTH, led to a diagnosis of autonomous bilateral adrenal adenomas or bilateral adrenal hyperplasia, with PPAD as one possible etiology. A bilateral adrenalectomy was performed. On macroscopic examination, the left adrenal gland's lean weight was 7gm and the right adrenal gland's lean weight was 5 gm. Both showed a dark red color with a fine nodular surface but no definite gross nodules were detected. Microscopic examination revealed multiple small unencapsulated nodules within the cortex surrounded by mostly atrophic adrenocortical tissue (Fig. 1). The cells within the nodules were uniform with mild nuclear pleomorphism and abundant eosinophilic cytoplasm with focally dark brown pig-

ment (Fig. 2). There was a moderate amount of lymphocytic infiltration. After surgery, the patient improved, with amelioration of the clinical symptoms of Cushing syndrome. He was placed on prednisolone for glucocorticoid replacement therapy.

Case two

A 13 year-old female, who presented with rapid weight gain and no height increase for one year. There was no history of Carney complex in the family. She was 140 cm tall and weighed 40 kg. She had a very mild cushingoid appearance, round face, small buffalo hump, and mild red striae at the left buttock. Her blood pressure was normal. Pubertally, she was breast stage 3 and pubic hair stage 3. She had no signs of Carney complex.

The laboratory investigations were Hb 14.8 gm/dL, Hct 45%, WBC 7,800 cells/mm³, PMN 55%, band

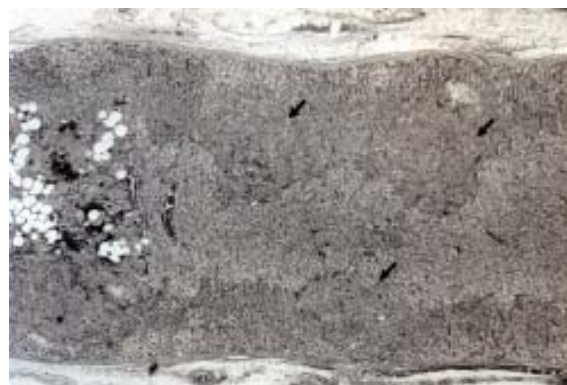

Fig. 1 Micronodules (arrow) are present at the adrenal cortex

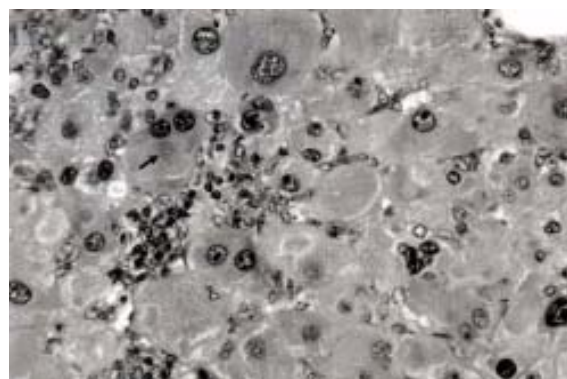


Fig. 2 The nodules contain cells with compact, eosinophilic cytoplasm with focally dark brown pigment (arrow) Focal lymphocytic infiltration can also be identified

2%, lymphocytes 34%, monocytes 8%, atypical lymphocyte 1%, platelets 346,000 cells/mm³, normal serum electrolytes, and normal fasting blood glucose.

Endocrine testing showed serum cortisol levels of 19.34 mg/dL and 14.70 mg/dL for the eight a.m. and eight p.m. samples respectively (normal for eight a.m. 5-25), 24-hour urine 17 OHCS was 22.60 mg/day (normal 3-10), 24 hour urine 17-KS was 7.7 mg/day (normal for age 13-16 year = 5-12). A dexamethasone suppression test was performed with dexamethasone 1.5 mg/day for two days followed by 4.5 mg/day for two days. The morning and midnight serum cortisol at baseline, and following 1.5 mg/day and 4.5 mg/day dexamethasone were determined. The morning serum cortisol levels at days one, four and six were 13.9, 21.38, 22.27 mg/dL respectively and the midnight serum cortisol levels were 12.18, 9.74, 17.57 mg/dL respectively. The results of the tests showed no suppression, and revealed paradoxical stimulation of cortisol secretion 60.22% over the morning baseline values.

An MRI study of the adrenal glands revealed relative focal enlargement of the medial limb of the left adrenal gland compared to the lateral limb and the right adrenal gland; the medial limb of the left adrenal gland was about 5 x 8 x 12 mm. Microadenoma of the left adrenal gland was considered. A venous blood sample of the adrenal vein via the right femoral vein using a simple angiographic technique was taken. The left adrenal venous blood cortisol was 119.3 mg/dL, and the right adrenal venous blood cortisol was 24.7 mg/dL, confirming the diagnosis of microadenoma of the left adrenal gland. A left adrenalectomy was performed.

Macroscopic examination revealed a dark brown triangular shaped adrenal gland with a lean weight of 5 gm. The cut surfaces were dark red and dark brown. No grossly definite nodule was identified. Microscopic examination revealed multiple small round unencapsulated nodules, composed of uniform cells with abundant eosinophilic cytoplasm and dark brown intracytoplasmic pigment within the cortex. Atrophic change of the perinodular adrenocortical tissue was noted. The adrenal medulla was normal.

As the diagnosis was PPNAD and the follow-up serum cortisol (62.11 mg/dL) was still abnormally high, a right adrenalectomy was performed four months later. The lean weight of the right adrenal gland was 5 gm. The cut surfaces showed multiple dark brown micronodules, varying from 0.1-0.3 cm in diameter. The microscopic findings were similar to the left adrenal gland.

A study of the neuroendocrine properties was performed in both cases, using immunostaining for

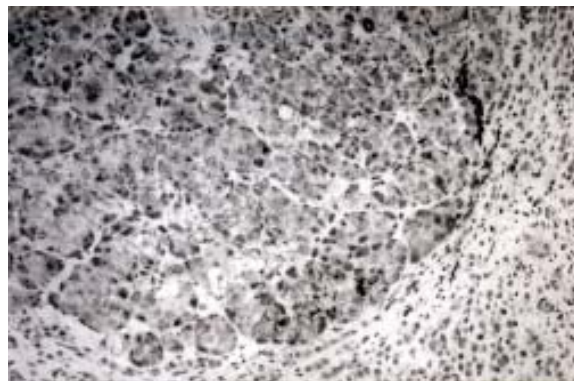


Fig. 3 Immunostaining for synaptophysin shows positivity in the cells in micronodules

synaptophysin and chromogranin. The results showed that the cells in the micronodules of both adrenal glands had immunoreactivity for synaptophysin (Fig. 3) but not with chromogranin whereas the extranodular cells were not stained with either synaptophysin or chromogranin.

Discussion

PPNAD is an exceedingly rare ACTH-independent adrenal cause of Cushing syndrome. It was first reported more than fifty years ago by Chute AL *et al* in 1949. Since then there have been reports of cases that have occurred in America⁽¹⁻⁶⁾, Europe⁽⁷⁻¹⁰⁾ and Asia^(11,12). The two patients reported here are the first two cases with PPNAD reported from Thailand.

The patients described in this report were sporadic cases of PPNAD, as there was no family history or other clinical manifestations of Carney complex. The onset was in early adolescence, and both had the general clinical characteristics of Cushing syndrome. The first case had a history of progressive disease for three years with hypertension and osteoporosis. Osteoporosis is a common manifestation resulting from prolongation of hypercortisolism. Of thirty cases reviewed by Larsen JL *et al*⁽⁶⁾, osteoporosis was present in 16 of the 18 cases in which the condition was commented on. Ruder HJ *et al*⁽¹⁾ reported on two patients with micronodular adrenal disease presenting with osteopenia with minimal signs of Cushing syndrome.

Concerning endocrinologic testing, the presented patients showed the same results as previous reviews^(1,2,6). The first case had low serum ACTH and both the patients had non-suppressible high dose dexamethasone suppression test. All the previously

reported cases with PPNAD showed non-suppressible response to high dose dexamethasone suppression test. The dexamethasone suppression test of the second patient showed a paradoxical response with a 60.22% elevated cortisol level at the end of the test. This paradoxical increase in cortisol excretion during the high-dose dexamethasone suppression test was previously noted and commented on by Stratakis CA *et al*⁽¹³⁾, in their retrospective study of 21 patients with PPNAD and 25 with other primary adrenal disorders, wherein they found that most PPNAD patients had urinary 17-hydroxycorticosteroid or urinary free cortisol in the sixth day rising more than 50% from the baseline. This feature occurred as statistically significant in most PPNAD patients when compared to other primary adrenal diseases. The molecular cause of the dexamethasone-related increase of glucocorticoid levels in PPNAD is unknown, but the substantial differences of cellular functions in the diseased adrenal cortex from a normal adrenal cortex may be responsible. Stratakis concluded that this feature was a useful marker to distinguish PPNAD patients from those who have Cushing syndrome caused by other primary adrenal disorders.

The pathology of the adrenal glands in PPNAD is highly characterized, and the adrenal glands of both presented patients were typical of PPNAD. Both adrenal glands were involved and were slightly enlarged with each gland weighing from five to seven grams, slightly heavier than normal adrenal gland. The upper limit of the normal surgically resected adrenal gland is four grams with an SD of 0.80 grams⁽¹⁴⁾. The average weights of eight PPNAD adrenal glands as reported by Travis WD *et al*⁽¹⁵⁾ were 5.6 grams for the left gland and 3.8 grams for the right gland. The color of the glands of the presented patients was also unique, with a dark red color in the first patient and dark red and dark brown coloring in the second. The histological findings revealed multiple small unencapsulated nodules within the cortex surrounded by mostly atrophic adrenocortical tissue and normal adrenomedulla tissue. The cells in the nodules were uniform with mild nuclear pleomorphism and abundant eosinophilic cytoplasm with focally dark brown pigment. Moderate lymphocytic infiltration was also noted. These features were similar to most cases reported by Larsen JL *et al*⁽⁶⁾ and Travis WD *et al*⁽¹⁵⁾.

Sasano-H *et al*⁽¹¹⁾ had studied eight cases of PPNAD adrenals by examining the immunohistochemistry of all steroidogenic enzymes involved in cortisol biosynthesis and also by performing *in situ* hybridi-

zation of P-45017 alpha in severe cases. Their study indicated that almost all of the cells in the nodules had abundant enzymatic activities and had a high ability to produce cortisol, which can explain the presence of hypercortisolism despite normal or slightly enlarged adrenal gland size. They found that the small cluster of cortical cells with abundant eosinophilic cytoplasm located at the zona reticularis may support the abnormal development of the zona reticularis and be a possible pathogenesis of this disorder.

Immunostaining for synaptophysin in both Thai patients led to a very interesting finding. The synaptophysin selectively stained the cells in the micronodules but not the extranodular cortex and clearly distinguished the PPNAD nodules from the surrounding adrenocortical tissue. Synaptophysin, a membrane glycoprotein of presynaptic vesicles, is a specific and sensitive marker for neurons and neuroendocrine tissues and tumors⁽¹⁶⁾. The adrenal cortex is not considered part of the diffuse neuroendocrine system and thus the presence of neuroendocrine markers was unexpected. Stratakis CA *et al*⁽¹⁷⁾ demonstrated an immunoreactivity to synaptophysin in eight PPNAD Carney complex specimens. In his study, PPNAD cells and myxomatous cell were intensely stained with antisera for synaptophysin. This study, as well as the EM study showed that vesicular mitochondria and smooth endoplasmic reticulum were prominent in the PPNAD cells, with liposomes, lysosomes, and filopodia present. Some dense core vesicle-like structures could be detected along the cell membranes, and a rough endoplasmic reticulum was prominent. These findings suggested that PPNAD cells had neuroendocrine properties. The demonstration of synaptophysin immuno-reactivity in the PPNAD nodules of both presented patients, was evidence that the sporadic PPNAD tissue of the presented patients also demonstrated similar neuroendocrine properties to the reports by Stratakis CA *et al*⁽¹⁷⁾. The interesting question is, "how did the PPNAD tissue gain these properties?" Stratakis CA *et al*⁽¹⁷⁾ postulated in 1999 that the adrenocortical PPNAD and myxomatous cells in his study, which were of mesodermal origin, must have assumed some neuroendocrine properties because of altered genetic regulation. Later on Groussin L *et al*^(18,19) sequenced the PRKAR1A gene (a gene coding for the type 1a regulatory subunit of protein kinase A) from patients with sporadic PPNAD and from the kin of the patients with PPNAD or Carney complex and demonstrated an alteration of the PRKAR1A function leading to tumorigenesis in tissues affected by Carney complex. Further molecular

studies may lead to a better understanding of the molecular mechanism involved in the pathogenesis of PPNAD and its modification of the cellular functions.

Summary: The authors have presented the clinical manifestations, pathological findings, microscopic findings, and immunostaining for synaptophysin in two Thai children with PPNAD.

Acknowledgement

The authors would like to thank Kanittar Srisook from the Department of Pathology, Faculty of Medicine, Siriraj Hospital, Mahidol University for performing paraffin section immuno-histochemistry for synaptophysin.

References

1. Ruder HJ, Loriaux DL, Lipsett MB. Severe osteopenia in young adults associated with Cushing's syndrome due to micronodular adrenal disease. *J Clin Endocrinol Metab* 1974; 39: 1138-47.
2. Meador CK, Bowdoin B, Owen WC Jr, Former TA Jr. Primary adrenocortical nodular dysplasia: a rare cause of Cushing's syndrome. *J Clin Endocrinol Metab* 1967; 27: 1255-63.
3. Young WF Jr, Carney JA, Musa BU, Wulffraat NM, Lens JW, Drexhage HA. Familial Cushing's syndrome due to primary pigmented nodular adrenocortical disease. Reinvestigation 50 years later. *N Engl J Med* 1989; 321: 1659-64.
4. Doppman JL, Travis WD, Nieman L, Miller DL, Chrousos GP, Gomez MT, et al. Cushing syndrome due to primary pigmented nodular adrenocortical disease: findings at CT and MR imaging. *Radiology* 1989; 172: 415-20.
5. Carney JA, Gordon H, Carpenter PC, Shenoy BV, Go VL. The complex of myxomas, spotty pigmentation, and endocrine overactivity. *Medicine (Baltimore)* 1985; 64: 270-83.
6. Larsen JL, Cathey WJ, Odell WD. Primary adrenocortical nodular dysplasia, a distinct subtype of Cushing's syndrome. Case report and review of the literature. *Am J Med* 1986; 80: 976-84.
7. Schweizer-Cagianut M, Froesch ER, Hedinger C. Familial Cushing's syndrome with primary adrenocortical microadenomatosis (primary adrenocortical nodular dysplasia). *Acta Endocrinol (Copenh)* 1980; 94: 529-35.
8. Donaldson MD, Grant DB, O'Hare MJ, Shackleton CH. Familial congenital Cushing's syndrome due to bilateral nodular adrenal hyperplasia. *Clin Endocrinol (Oxf)* 1981; 14: 519-26.
9. Teding vB, Crougths RJ, Kater L, Schuurman HJ, Gmelig Meyling FJ, Kooyman CD, et al. Familial Cushing's syndrome due to nodular adrenocortical dysplasia. A putative receptor-antibody disease? *Clin Endocrinol (Oxf)* 1986; 24: 299-310.
10. Sofat N, Turner J, Khoo B, Sohail M, Krausz T, Evans P, et al. An unusual cause of Cushing's syndrome: primary pigmented nodular adrenal dysplasia. *Int J Clin Pract* 2000; 54: 269-71.
11. Sasano H, Miyazaki S, Sawai T, Sasano N, Nagura H, Funahashi H, et al. Primary pigmented nodular adrenocortical disease (PPNAD): immunohistochemical and in situ hybridization analysis of steroidogenic enzymes in eight cases. *Mod Pathol* 1992; 5: 23-9.
12. Choi KM, Seu JH, Kim YH, Lee EJ, Kim SJ, Baik SH, et al. Cushing's syndrome due to primary pigmented nodular adrenocortical disease - a case report reviews of the literature. *Korean J Intern Med* 1995; 10: 68-72.
13. Stratakis CA, Sarlis N, Kirschner LS, Carney JA, Doppman JL, Nieman LK, et al. Paradoxical response to dexamethasone in the diagnosis of primary pigmented nodular adrenocortical disease. *Ann Intern Med* 1999; 131: 585-91.
14. Studzinski GP, Hay DC, Symington T. Observations on the weight of the human adrenal gland and the effect of preparations of corticotropin of different purity on the weight and morphology of the human adrenal gland. *J Clin Endocrinol Metab* 1963; 23: 248-54.
15. Travis WD, Tsokos M, Doppman JL, Nieman L, Chrousos GP, Cutler GB Jr, et al. Primary pigmented nodular adrenocortical disease. A light and electron microscopic study of eight cases. *Am J Surg Pathol* 1989; 13: 921-30.
16. Miettinen M. Synaptophysin and neurofilament proteins as markers for neuroendocrine tumors. *Arch Pathol Lab Med* 1987; 111: 813-8.
17. Stratakis CA, Carney JA, Kirschner LS, Willenberg HS, Brauer S, Ehrhart-Bornstein M, et al. Synaptophysin immunoreactivity in primary pigmented nodular adrenocortical disease: neuroendocrine properties of tumors associated with Carney complex. *J Clin Endocrinol Metab* 1999; 84: 1122-8.
18. Groussin L, Jullian E, Perlemoine K, Louvel A, Leheup B, Luton JP, et al. Mutations of the PRKAR1A gene in Cushing's syndrome due to sporadic primary pigmented nodular adrenocortical disease. *J Clin Endocrinol Metab* 2002; 87: 4324-9.

19. Groussin L, Kirschner LS, Vincent-Dejean C, Perlemoine K, Jullian E, Delemer B, et al. Molecular analysis of the cyclic AMP-dependent protein kinase A (PKA) regulatory subunit 1A (PRKAR1A) gene in patients with Carney complex and primary

pigmented nodular adrenocortical disease (PPNAD) reveals novel mutations and clues for pathophysiology: augmented PKA signaling is associated with adrenal tumorigenesis in PPNAD. *Am J Hum Genet* 2002; 71: 1433-42.

รายงานผู้ป่วยเด็กไทย 2 รายที่ป่วยด้วยโรค *primary pigmented nodular adrenocortical disease* และมีผลบวกต่อการตรวจด้วย *synaptophysin*

นฤมล ภัทรกิจวานิช, คณิตา กายะสุด, วิญญู มิตรานันท์, ศักดา ภัทรภิญโญกุล, สุรศักดิ์ สังขทัต ณ อยุธยา

Primary pigmented nodular adrenocortical disease หรือ PPNAD เป็นสาเหตุที่พบน้อยมากที่ก่อให้เกิด Cushing syndrome ผู้ศึกษาได้รายงานผู้ป่วยเด็กไทยสองรายที่ป่วยด้วยโรค PPNAD ผู้ป่วยทั้งสองมีอาการ Cushing syndrome ผลเลือดมีภาวะ hypercortisolemia การทดสอบด้วย high dose dexamethasone suppression test ให้ผล nonsuppressible ในผู้ป่วยรายแรกและให้ผล paradoxical response ในผู้ป่วยรายที่สอง ผู้ป่วยทั้งสองได้รับการผ่าตัด ตัดต่อมหมวกไตออกทั้งสองข้าง ผลการตรวจทางพยาธิวิทยาพบว่าต่อมหมวกไตมีสีแดงคล้ำ และมีลักษณะทางจุลกายวิภาคที่เข้าได้กับโรค PPNAD ผู้ป่วยทั้งสองมีเนื้อเยื่อต่อมหมวกไตบริเวณที่มีพยาธิสภาพให้ผลบวกต่อการตรวจด้วย *synaptophysin*