

# Effectiveness of Activated Hydrogen Ions in Neutralizing Paraquat Intoxication in Rats

Sawang Saenghirunvattana MD\*, Piboon Laohathai MD\*,  
Sompol Sangguanrungrasirikul MD\*\*, Surapon Worapongpaiboon MD, FCAP\*,  
Narumol Masakul MBA\*, Kasem Saenghirunvattana\*\*\*

*Supported by Prasert Prasatthongosot Foundation*

*\* Samitivej Hospital, \*\* Chulalongkorn University Hospital, \*\*\* Siriraj Hospital*

---

**Objective:** Investigate the effectiveness of  $H_4O$  in preventing the paraquat's effect in rats.

**Material and Method:** Disease-free male sprague Dawley rats were used in the experiment. They were divided into two groups of 5, as the control group and the experiment group. All rats were poisoned with paraquat. The control group was fed water ( $H_2O$ ) while the experiment group was fed activated hydrogen ions ( $H_4O$ ).

**Results:** The mortality of rats was equal (40%) in both groups. The control group died earlier than the experimental group (48 hours, 96 hours). In the rats that could survive till 1 month, the pathology of the lungs in the experimental group revealed less severity than the control group.

**Conclusion:** This may reflect the protective effects of activated hydrogen ions in the lungs, which are abundant in oxygen, and may offer fruitful results in humans.

**Keywords:** Activated hydrogen ions, Paraquat, Interstitial hemorrhage

*J Med Assoc Thai 2007; 90 (6): 1097-9*

**Full text. e-Journal:** <http://www.medassocthai.org/journal>

---

Paraquat poisoning is one of the leading fatal agrochemical intoxication problems in many agricultural countries including Thailand. The toxic compound accumulates in lung tissues where free radicals are formed, lipid peroxidation is induced, and nicotinamide adenine dinucleotide phosphate (NADPH) is depleted. This produces diffuse alveolitis followed by extensive pulmonary fibrosis, jaundice, renal failure, and death. Oxygen supplementation is prohibited in intoxicated patients due to reactivation of the active form of paraquat.

Many treatment modalities such as Fuller's earth, activated charcoal or resin remain ineffective; Hemodialysis, hemoperfusion, and peritoneal dialysis have been attempted with unsatisfactory survival rates<sup>(1-14)</sup>.

Recently, a combination of deoxidizing hydrogen molecules with an atom of oxygen has been created via electricity. This is  $H_4O$  (activated hydrogen ion). When active hydrogen combines with active oxygen, it neutralizes the active oxygen into  $H_2O$ . This

reaction may prevent tissue damage especially in paraquat poisoned patients. The authors then planned to investigate the effectiveness of  $H_4O$  in preventing the paraquat's effect in rats.

## Material and Method

Ten disease-free male sprague Dawley rats, obtained from the National Laboratory Animal Center, Thailand, weighing 250-300 grams were used in the experiment. They were divided into two groups of 25, as the control group and the experiment group.

On day 1, all rats were injected intraperitoneally with a 10 mg/ml paraquat solution (Zeneca Agrochemicals, UK) at a dose of 24 mg/kg. Rats in the experiment group received activated hydrogen water as a source of water while the control group received drinking water. Both groups were fed by a regular diet as needed.

During the present study, the lungs, kidneys and livers of rats that died before day 30, were dissected and kept in formalin solution.

On day 30, all the remaining rats were sacrificed. Pathology of the lungs, kidneys, and livers were

*Correspondence to : Saenghirunvattana S, Samitivej Sukumvit Hospital, Bangkok 10110, Thailand.*

compared between the experiment group and the control group. The pathologist was given only the code number of each rat to prevent any bias.

### Results

There were no statistical differences in the body weight between the control group ( $326 \pm 16$  grams) and the experiment group ( $322 \pm 17$  grams).

Forty percent of the control group died in 48 hours. Forty percent of the experiment group also died but in 96 hours. The rest of the two groups developed mild rapid breathing in the first week and survived. They were all sacrificed after the thirty days. The body weight of the control group increased 16%, while the experiment group increased 12%.

### Pathological results

#### Lungs

For those who died early, in both groups, the lungs revealed the same, moderate to marked interstitial hemorrhage and moderate vascular congestion (3+). In the experimental group, there was also mild focal intra-alveolar hemorrhage.

For those who survived for 1 month, lesions in both groups revealed mild interstitial hemorrhage (1+). The control groups also developed moderate pulmonary vein congestion and moderate perivascular lymphocytic cuffing, mild focal consolidation with an increase in the alveolar macrophages. This did not appear in the experimental group (Fig. 1 and 2).

#### Heart

There was no abnormal pathology in both groups.

#### Liver

There was mild sinusoidal congestion and moderate vascular congestion among those who died early. There was no significant difference between the two groups.

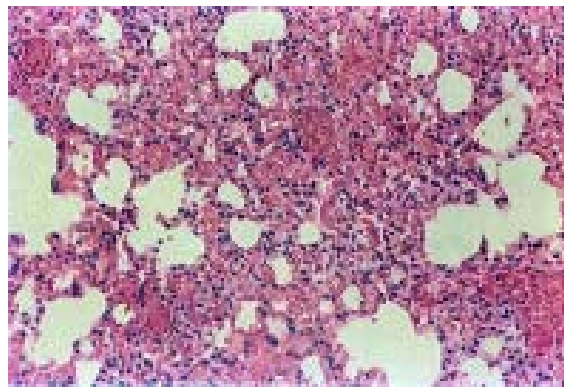
Among those who survived till 30 days, the liver was normal in both groups.

#### Kidneys

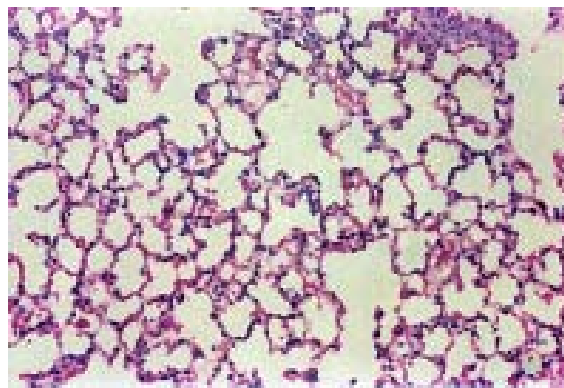
There were mild congestion and minimal intramedullary hemorrhage in all rats in both groups.

### Discussion

In the present experiments, there were no different effects between the two groups, in terms of mortality rate (40%), and pathological lesions in the



**Fig. 1** Paraquat intoxicated rat fed with H<sub>2</sub>O, pathology of the lung revealed moderate pulmonary vein congestion, moderate perivascular lymphocytic cuffing, mild focal consolidation with an increase in the alveolar macrophage



**Fig. 2** Paraquat intoxicated rat fed with H<sub>2</sub>O, pathology of the lung revealed only mild interstitial hemorrhage

liver, kidneys, and heart.

The effects of activated hydrogen ions may decrease the pathology in the lungs among those who could survive till 1 month. There was no pulmonary vein congestion and no perivascular lymphatic cuffing. This may reflect the protective effects of activated hydrogen ions on the lungs, which were abundant in oxygen and may offer fruitful results in humans.

### References

1. Kaojarern S, Ongphiphadhanakul B. Predicting outcomes in paraquat poisonings. *Vet Hum Toxicol* 1991;33: 115-8.
2. Selman M, Montano M, Ramos C, Barrios R, Perez-Tamayo R. Experimental pulmonary fibrosis in-

- duced by paraquat plus oxygen in rats: a morphologic and biochemical sequential study. *Exp Mol Pathol* 1989; 50: 147-66.
3. Bismuth C, Garnier R, Baud FJ, Muszynski J, Keyes C. Paraquat poisoning. An overview of the current status. *Drug Saf* 1990; 5: 243-51.
  4. Im JG, Lee KS, Han MC, Kim SJ, Kim IO. Paraquat poisoning: findings on chest radiography and CT in 42 patients. *AJR Am J Roentgenol* 1991; 157: 697-701.
  5. Greeberg BD, Last JA. Collagen biosynthesis by lung slices from rats administered paraquat, a fibrotic agent. *Chest* 1977; 72: 400.
  6. Reiser KM, Last JA. Pulmonary fibrosis in experimental acute respiratory disease. *Am Rev Respir Dis* 1981; 123: 58-63.
  7. Granot I, Bartov I, Plavnik I, Wax E, Hurwitz S, Pines M. Increased skin tearing in broilers and reduced collagen synthesis in skin in vivo and in vitro in response to the cocciostat halofuginone. *Poult Sci* 1991; 70: 1559-63.
  8. Nagler A, Firman N, Feferman R, Cotev S, Pines M, Shoshan S. Reduction in pulmonary fibrosis in vivo by halofuginone. *Am J Respir Crit Care Med* 1996; 154: 1082-6.
  9. Nagler A, Rivkind AI, Raphael J, Levi-Schaffer F, Genina O, Lavelin I, et al. Halofuginone - an inhibitor of collagen type I synthesis - prevents post-operative formation of abdominal adhesions. *Ann Surg* 1998; 227: 575-82.
  10. Levi-Schaffer F, Nagler A, Slavin S, Knopov V, Pines M. Inhibition of collagen synthesis and changes in skin morphology in murine graft-versus-host disease and tight skin mice: effect of halofuginone. *J Invest Dermatol* 1996; 106: 84-8.
  11. Choi ET, Callow AD, Sehgal NL, Brown DM, Ryan US. Halofuginone, a specific collagen type I inhibitor, reduces anastomotic intimal hyperplasia. *Arch Surg* 1995; 130: 257-61.
  12. Granot I, Halevy O, Hurwitz S, Pines M. Halofuginone: an inhibitor of collagen type I synthesis. *Biochim Biophys Acta* 1993; 1156: 107-12.
  13. Matthew H, Logan A, Woodruff MF, Heard B. Paraquat poisoning - lung transplantation. *Br Med J* 1968; 3: 759-63.
  14. Saenghirunvattana S, Sermswan A, Piratchvej V, Rochanawutanon M, Kaojarern S, Rattananyanya T. Effect of lung irradiation on mice following paraquat intoxication. *Chest* 1992; 101: 833-5.

---

### ผลของแอกติเวต ไฮโดรเจน ไฮออน ต่อหนูที่ได้รับสารพาราควอท

สว่าง แสงหิรัญวัฒนา, พิบูลย์ เลหาทัย, สมพันธ์ สงวนรังศิริกุล, สุรพล วรพงศ์ไพบูลย์, นฤมล มาสกุล, เกษม แสงหิรัญวัฒนา

ได้นำแอกติเวต ไฮโดรเจน ไฮออน ( $H_4O$ ) มาทดลองในหนู 10 ตัวที่ได้รับสารพาราควอท เทียบกับกลุ่มควบคุมที่ดื่ม น้ำ  $H_2O$  ผลพบว่า อัตราตาย 40% เท่ากันในทั้ง 2 กลุ่ม แต่กลุ่มที่ได้  $H_4O$  ตายช้ากว่ากลุ่ม ควบคุม (96 ชั่วโมง, 48 ชั่วโมง) ในหนูที่รอดถึง 1 เดือน พบว่า พยาธิสภาพในปอด ของกลุ่มที่ได้รับ  $H_4O$  รุนแรงน้อยกว่า กลุ่มควบคุมที่ได้รับ  $H_2O$