

# Preliminary Report

## Nerve-Sparing Laparoscopic Radical Prostatectomy at Siriraj Hospital

Sittiporn Srinualnad MD, FRCS (Glasgow)\*,  
Chaiyong Nualyong MD\*

\* Division of Urology, Department of Surgery, Faculty of Medicine Siriraj Hospital, Mahidol University

**Background:** Quality of life after laparoscopic radical prostatectomy has been a discussed issue among patients. Nerve-sparing radical prostatectomy has been shown to be superior to non-nerve-sparing radical prostatectomy in terms of potency and continence. The authors have reported their experience of laparoscopic radical prostatectomy and now developed our technique of nerve-sparing laparoscopic radical prostatectomy.

**Objective:** To evaluate the feasibility of nerve-sparing laparoscopic radical prostatectomy done at our institute.

**Material and Method:** From December 2005 to August 2006, 28 patients with localized prostate cancer underwent a nerve-sparing laparoscopic radical prostatectomy. Perioperative data was compared to those 34 patients who underwent non-nerve-sparing laparoscopic radical prostatectomy during the same period. All patients had PSA of less than 10 and pre-operative Gleason Score of 7 or less. Quality of life including incontinence and impotency rates was analyzed during three months post-operation.

**Results:** Patients' demographic data, except ages, was similar in the two groups. Operating time was not different (217 vs. 212 minutes in favor of nerve-sparing). Blood loss was significantly high in nerve-sparing laparoscopic radical prostatectomy (814 mls vs. 543 mls,  $p = 0.01$ ). Tumor control was not different within both groups. Three months after surgery incontinent rates of both groups were not different. 43.75% of patients with nerve-sparing technique had experienced erection at three months after surgery.

**Conclusion:** The authors' early experience has shown that nerve-sparing laparoscopic radical prostatectomy does not compromise cancer control, although blood loss is higher. This operation should be encouraged in cancer-localized patients as the patients may gain benefit of better quality of life.

**Keywords:** Nerve sparing laparoscopic radical prostatectomy, Prostate cancer, Laparoscopy, impotency

*J Med Assoc Thai* 2007; 90 (4): 730-6

**Full text. e-Journal:** <http://www.medassocthai.org/journal>

Open radical prostatectomy has been accepted as one of the standard treatments in clinically localized prostate cancer for many decades<sup>(1)</sup>. In 2006, the authors reported 56 cases of transperitoneal laparoscopic radical prostatectomy<sup>(2)</sup>. Since then the number of laparoscopic radical prostatectomy has increased dramatically at the institute. Subsequently, the authors have changed the approach to extra-peritoneal laparoscopic radical prostatectomy. Extra-peritoneal laparoscopic radical prostatectomy is as good as open retro-

pubic radical prostatectomy at the institute<sup>(3)</sup>. Since 1984, nerve-sparing radical prostatectomy has been reported<sup>(4)</sup>. The procedure has been popular among potent patients suffering from prostate cancer. Since the authors have experience in laparoscopic radical prostatectomy, the authors therefore started the program of nerve-sparing laparoscopic radical prostatectomy. The authors' early experience of nerve-sparing laparoscopic radical prostatectomy has been analyzed and reported here.

### Material and Method

From December 2005 to August 2006, 28 patients with localized prostate cancer underwent nerve-sparing laparoscopic radical prostatectomy

Correspondence to : Srinualnad S, Division of Urology, Department of Surgery, Faculty of Medicine, Siriraj Hospital, Bangkok 10700, Thailand. Phone: 0-2419-8010, Fax: 0-2411-2011, E-mail: [sisri@mahidol.ac.th](mailto:sisri@mahidol.ac.th)

(NSLRP) at the Urological Division, Department of Surgery, Faculty of Medicine Siriraj Hospital. All patients were histologically proven as having adenocarcinoma of the prostate from biopsy. Potent-patients with Gleason Score of 7 or less and Prostate Specific Antigen (PSA) of less than 10 were invited to undergo the procedure. All patients were given an informed consent for the procedure. Patients' data was collected and compared to those 34 patients who underwent non-nerve sparing laparoscopic radical prostatectomy (non NSLRP) during the same period for clinically localized and transrectal ultrasound biopsy proved prostate cancer. All 62 patients had Gleason Score of 7 or less and PSA of less than 10 with clinically localized disease. They had the same post-operative protocol of care.

***Operative technique is described here:***

Laparoscopic radical prostatectomy is usually performed with the patient under general anesthesia. Patients are placed in a dorsal supine position with 10-15° head down tilt.

The first step in the procedure is to create a preperitoneal space and the placement of the first trocar. A paraumbilical incision and incision of the anterior rectus sheath is followed by a blunt dissection of the rectus muscle and "finger dissection" of the preperitoneal space. A balloon catheter is introduced along the posterior rectus sheath and insufflated. Next, the balloon catheter is exchanged for an optical trocar (Hassan type). The authors then placed the 2<sup>nd</sup> 5 mm working trocar 2-3 fingers left lateral to the midline. This position avoids interaction between the instruments inserted into this trocar and the optical system. In addition, it is more comfortable for the surgeon because he does not have to lean over the patient and stands in a more relaxed position. The 3<sup>rd</sup> 5 mm working trocar is placed in the right iliac fossa two fingers medially to the anterosuperior iliac spine. The 4<sup>th</sup> 5 mm assisting trocar is placed at the right pararectal region. Finally, the 5<sup>th</sup> trocar, 12 mm in size, is placed in the left iliac fossa three fingers medially to the anterosuperior iliac spine.

The first step in the procedure is the dissection of the space of Retzius. The anterior surface of the bladder neck, the anterior surface of the prostate and the endopelvic fascia are exposed and the fatty tissue overlying these structures is gently swept away. Often, a superficial branch of the deep dorsal vein complex runs along the anterior aspect of the prostate and divides at the bladder neck into two branches. This vein

is fulgurated with bipolar forceps and divided. Then, the endopelvic fascia is incised on both sides exposing the fibers of the levator ani muscle.

The bladder neck can be identified after the removal of all of the prevesicular fatty tissue. It overlaps the prostate in the shape of a triangle. The dissection starts at a 12 o'clock position at the tip of this triangle. Palpation with the forceps can help to identify the border between the mobile bladder neck and the solid prostate in difficult cases. The incision of the bladder neck is enlarged from the 10 to the 2 o'clock position, and the urethra is developed. The urethra is incised and the deflated balloon-catheter is pulled up into the retropubic space by the assistant under continuous tension. The dissection is now continued in the lateral direction, in the plane between the bladder neck and prostate.

Once, the bladder neck is completely dissected, care is taken to carry down the dissection in the correct plane between the prostate and the bladder neck in order to avoid any intraprostatic penetration. This pitfall may occur in the case of a penetration directed too caudally. The bladder neck is first completely divided between the 5-7 o'clock position; this is then extended bilaterally by blunt and sharp dissection. After this step, the anatomical landmarks of the ampullae and the seminal vesicles are visualized.

After complete dissection of the bladder neck, the prostate is elevated anteriorly by the assistant. The seminal vesicles are easily identified and completely dissected. However, the tips of the seminal vesicles can be left in place in order to avoid damage to the neurovascular bundles that run in close proximity to them. After dissection of the seminal vesicles, the assistant holds the right ampulla and the right seminal vesicle, the surgeon the left ampulla and the left seminal vesicle in a craniolateral direction. With this maneuver, a "window" is developed which reaches from the dorsal aspect of the prostate to the prostatic pedicles. Between these structures, the posterior layer of Denonvillier's fascia is incised and the pre-rectal fatty tissue visualized. The posterior dissection is continued as far as possible towards the apex of the prostate.

(If nerve sparing laparoscopic radical prostatectomy is performed, the lateral prostatic fascia is incised at the anterolateral surface of the prostate gland prior to the posterior dissection. During the posterior dissection care must be taken not to injure the neuron-vascular bundles by avoid using heat of any kind and staying in the middle with medial to lateral dissection. Using this principle the neurovascular

bundles should be easily retracted from the prostate gland and urethra distally.)

Puboprostatic ligaments are divided sharply. After this step, the urethra and the dorsal vein complex can be easily visualized at the level of the prostatic apex. The prostate is now retracted caudally by the assistant for good access to the Santorini plexus. The Santorini plexus is ligated with 0 Vicryl by selective passage of the needle underneath the plexus from left to right.

The urethra is sharply divided at the apex. Coagulation of the urethral stump is to be avoided in order to prevent damage to the external striated sphincter. In case of minor bleeding in this area, the CO<sub>2</sub>-pressure can be increased temporarily to 16-18 mmHG.

For creation of the urethrovesical anastomosis, the authors use a needle holder (right hand of the surgeon) and a forceps (left hand of the surgeon) and 2-0 Vicryl with a UR-6 needle. The first stitch starts at the 8 o'clock position (backhand-backhand) followed by stitches at the 7, 6, and 5 o'clock positions (forehand at the bladder neck, backhand at the urethra). Starting at the bladder neck (outside-in), the assistant pulls up the catheter anteriorly. The anastomotic stitches are then completed at the urethra inside-out. Between the two stitches, the needle has to be rotated 180°. After each urethral stitch, the catheter needs to be pulled back in order to rule out fixation by the anastomotic suture. During the posterior stitches, care is taken to avoid any injury to the preserved neurovascular bundles (in cases of nerve-sparing laparoscopic radical prostatectomy). The 4 o'clock stitch is then done forehand (bladder neck)-forehand (urethra). After the dorsal circumference has been completed, the catheter is placed into the bladder and the anastomosis is completed anterolaterally and ventrally. On the left side, the stitches are thrown backhand-backhand and on the right side forehand-forehand. All ties are thrown intracorporally.

If a bladder neck preserving technique cannot be applied, a bladder neck reconstruction ("tennis-racket" reconstruction) is performed at a 12 o'clock position.

The magnification of the laparoscope allows good visibility throughout the creation of the anastomosis, allowing the anastomosis to be performed correctly, watertight and safely. The water-tightness of the anastomosis is finally checked by filling the bladder with 200 ml sterile water. At the end of the procedure, a Jackson drainage catheter is placed into the retropubic space.

Cystography is performed on post-operative day 7, 10, 14 and the urethral catheter is removed if there is no leak of contrast media from urethrovesicle anastomosis.

### **Statistical analysis**

Continuous variables were expressed as mean or median  $\pm$  standard deviation (SD) and categorical data were expressed as number and percent.

Perioperative data, operative results, clinical outcomes, and complication were analyzed between the two groups using Chi-Square test or student unpaired t test where appropriated. A p-value of less than 0.05 is considered as statistically significant difference.

### **Results**

The mean age of the patients were  $67.2 \pm 5.5$  years and  $61.6 \pm 6.6$  years in non-nerve sparing laparoscopic radical prostatectomy (non-NSLRP) group and nerve sparing laparoscopic radical prostatectomy (NSLRP) group, respectively. Mean PSA was  $5.8 \pm 2.4$  ng/ml and  $6.3 \pm 2.8$  ng/ml in non-NSLRP and NSLRP groups, respectively. Mean operative time was approximately equal in both groups. In the NSLRP group the average operative blood loss was significantly higher than in the non-NSLRP group ( $814.3 \pm 443.7$  mls vs.  $548.5 \pm 317.5$  mls,  $p = 0.011$ ). Mean catheterization time was shorter in the NSLRP group ( $7.2 \pm 1.1$  days vs.  $8.6 \pm 3.8$  days,  $p = 0.053$ ). Mean hospital stay was not different between the two groups at  $8.3 \pm 2.7$  days and  $8.7 \pm 2.4$  days in the non-NSLRP and NSLRP groups, respectively. Mean prostatic weight was slightly higher in the non-NSLRP than in the NSLRP groups, but it did not reach statistically significant level ( $43.3 \pm 21$  gm in non-NSLRP and  $35.7 \pm 15.9$  gm in NSLRP). All data is shown in Table 1.

Organ confined disease was not different between the 2 groups with 93% and 94% in NSLRP and non-NSLRP, respectively. In pathological T2 (pT2), surgical margin was positive at the rate of 12% in the NSLRP group but was slightly higher in the non-NSLRP at the rate of 16%. This was not significantly different using Chi-Square test. ( $p = 0.47$ ), as shown in Table 2.

Table 3 shows the early result of continence rate at three months (completely dry with no pad). There was no difference between the two groups (54% vs. 50%,  $p = 0.5$ , in non-NSLRP and NSLRP, respectively).

43.75% (7/16) of patients who underwent NSLRP operation reported themselves of having an erection at three months post-operation. Of these

**Table 1.** Shows mean  $\pm$  SD of Age, Blood loss, Prostatic weight, PSA, OR time, Catheter time, Hospital stay in both groups

	Non-NSLRP (n = 34)	NSLRP (n = 28)	p-value
Age (years)	67.15 $\pm$ 65.5	61.57 $\pm$ 6.6	0.001
Blood loss (mls)	548.53 $\pm$ 317.54	814.29 $\pm$ 443.65	0.011
Prostatic weight (gram)	43.34 $\pm$ 20.86	35.66 $\pm$ 15.93	0.116
PSA (ng/ml)	5.79 $\pm$ 2.37	6.34 $\pm$ 2.76	0.395
OR time (minutes)	217.06 $\pm$ 54.83	212.67 $\pm$ 44.46	0.735
Catheter removal time (days)	8.59 $\pm$ 3.8	7.22 $\pm$ 1.08	0.076
Hospital stay (days)	8.29 $\pm$ 2.72	8.67 $\pm$ 2.40	0.582

Note: p-value by unpaired t test

**Table 2.** Shows pathological results in both groups

	Non-NSLRP (n = 34)	NSLRP (n = 28)	p-value
Surgical Margin positive	16%	12%	0.720
Non-Extraprostatic disease	94%	93%	0.617

Note: p-value by Chi-square test

**Table 3.** Shows continence and potency rates at 3 months in both groups

	Non-NSLRP (n = 24)	NSLRP (n = 22)	p-value
Continence (%)	13/24 (54%)	11/22 (50%)	0.505
Potency (%)	NS	7/16 (43.75%)	-

Note: p-value by Chi-square test

**Table 4.** Shows peri-operative and immediated post-operative complications

	Non-NSLRP (n = 34)	NSLRP (n = 28)
Cerebral infraction	0	1
Pneumonia	0	1
Prolong drainage	2	0
Retention of Urine	0	1
Prolapsed hemorrhoid	0	1

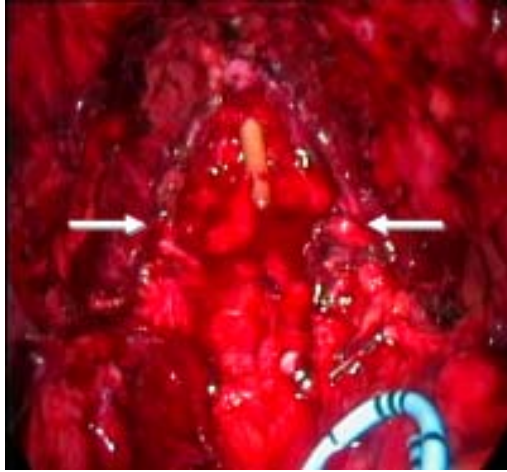
seven potent patients, two patients experienced full erection without medication, four patients with partial erection, and one patient with oral PDE-5 inhibitor.

There were two cases of prolonged urinary leakage from the anastomotic site more than one week in the non-NSLRP group. They were treated success-

fully with conservative measures. In the NSLRP group there were four complications including one patient with postoperative stroke, one patient with pneumonia developed on postoperative day 3, one patient with urinary retention and one with prolapsed external hemorrhoid.

### Discussion

Two major complications of radical prostatectomy for localized prostate cancer patients are impotency and incontinence. These complications discourage patients from undergoing the operation. Some patients seek other alternatives including radiation and brachytherapy. However, using meticulous surgical technique that preserves the branches of the pelvic plexus that innervate the corpora cavernosa employed during radical retropubic prostatectomy in men can preserve sexual function in 86% by 1 year after the operation<sup>(4)</sup>.



**Fig. 1** Intra-operative picture of Bilateral Nerve Sparing with Arrows pointing at neuro-vascular bundles of both sides

The prospective study of 536 patients who underwent open radical retropubic prostatectomy with attempted bilateral, unilateral or no nerve sparing was conducted by Burkhard *et al*<sup>(5)</sup>. One year after surgery 505 of 536 patients (94.2%) were continent, 27 (5%) had grade I stress incontinence and four (0.8%) had grade II stress incontinence. Incontinence was found in 1 of 75 (1.3%), 11 of 322 (3.4%) and 19 of 139 patients (13.7%) with attempted bilateral, attempted unilateral and without attempted nerve sparing, respectively. The proportional differences were highly significant, favoring a nerve sparing technique ( $p < 0.0001$ ). On multiple logistic regression analysis attempted nerve sparing was the only statistically significant factor influencing urinary continence after open radical retropubic prostatectomy (OR 4.77, 95% CI 2.18 to 10.44,  $p = 0.0001$ ). The authors suggest that nerve-sparing should be attempted in all patients if the principles of oncological surgery are not compromised.

In the large cohort study looking at 723 patients who underwent nerve-sparing radical prostatectomy compared to 620 patients with non-nerve sparing radical prostatectomy, nerve-sparing radical prostatectomy is an oncologically safe procedure and there is no evidence that adequacy of tumor excision is compromised by the nerve sparing procedure<sup>(6)</sup>.

Another large cohort study of the impact of surgical approach (nerve bundle preservation versus wide local excision) on surgical margins and biochemical recurrence following radical prostatectomy has shown that nerve-sparing radical prostatectomy is not

an independent adverse risk factor for positive surgical margins or progression-free survival. The authors suggest that all patients with organ confined prostate cancer should be considered candidates for a nerve sparing operation<sup>(7)</sup>. Overall positive surgical margin of pathological T2 (pT2) in the present study was 14% (8/58). Patients who underwent NSLRP had a positive surgical margin of 12% (3/26) which is slightly higher than those reported in the literature between 8.4-10.2%<sup>(8,9)</sup>. Obviously, this can be improved as our experience increases.

Nerve-sparing laparoscopic radical prostatectomy was first reported in 2001 using the robotic assisted technique<sup>(6)</sup>. Katz *et al* reported the first series of nerve-sparing laparoscopic radical prostatectomy<sup>(8)</sup>. The overall rate of patients who had erections pre-operatively and maintained erections by one year after surgery (53.8%) is comparable to the results for open surgery. Patients with bilateral preservation did better than those with unilateral preservation and nerve preservation did not increase the incidence of positive margins<sup>(8,10)</sup>. In this present study, NSLRP was feasible, although intra-operative blood loss was significantly higher than those non-NSLRP counterparts. The amount of average blood loss was equal to the early series reported by Pasticier *et al*<sup>(6)</sup>. The reason for increasing blood loss was due to the authors' technique of cold dissection without using any heat at all during our bundles sparing. In the present study, there was one case of serious complication of multiple area of cerebral infraction, which developed immediately post-operation. This was probably due to intra-operative hypotension, which was not related to the authors' NSLRP technique. Obviously, the operation (NSLRP) should be preserved for patients who are clinically fit.

Su LM *et al*<sup>(11)</sup> described a technique of minimizing the potential for cavernous nerve damage from electrical energy or heat. Early functional outcomes appear comparable to the results obtained with open radical prostatectomy performed at their institution. On the basis of their early experience, 76% of patients engaging in sexual intercourse pre-operatively who underwent bilateral nerve preservation ( $n = 21$ ) reported the ability to engage in sexual intercourse 1 year after NSLRP al.

In the present study, 43.75% of patients who underwent NSLRP reported to have erection at three months after surgery, which is similar to the previous study<sup>(10)</sup>. Continence rate is as good as those of Non-NSLRP counterpart. Overall, potency rates by one year after the operation of NSLRP were reported at between

58.5-87.5% and continence rates reported at 93.4-95%<sup>(10,12,13)</sup>. However, Robotic Assisted LRP has reported slightly better outcomes in terms of quality of life one year after surgery with continence rates of 97% and potency rates of 96%<sup>(14)</sup>. This is probably due to a better preservation of neurovascular bundles during the Veil of Aphrodite technique applied during Robotic Assisted LRP reported by Menon<sup>(15)</sup>. However, it remains to be seen if these bundles have something to do with potency and continence mechanism.

Patient's age may be effected on the functional outcomes of NSLRP. A recent report has shown that younger men treated with nerve-sparing laparoscopic radical prostatectomy regain urinary control and potency earlier than older men<sup>(16)</sup>. In the present study, younger patients were offered NSLRP as the patients might gain benefit of better quality of life including early recovery of erection.

### Conclusion

In the present study, nerve-sparing laparoscopic radical prostatectomy is feasible. Patients undergoing nerve-sparing laparoscopic radical prostatectomy may encounter significantly higher intra-operative blood loss than those having non-nerve-sparing laparoscopic radical prostatectomy. Surgical margin status is not compromised by using nerve-sparing laparoscopic radical prostatectomy. With promising early postoperative results, young and low risk patients with localized prostate cancer should be offered nerve-sparing laparoscopic radical prostatectomy. A long-term study comparing nerve-sparing laparoscopic radical prostatectomy to robotic assisted laparoscopic radical prostatectomy is required to access quality of life after radical prostatectomy.

### References

- Walsh PC. The status of radical prostatectomy in the United States in 1993: where do we go from here? *J Urol* 1994; 152: 1816.
- Nualyong C, Srinualnad S, Taweemonkongsap T, Amornvesukit T. Laparoscopic radical prostatectomy: preliminary result of Thailand series. *J Med Assoc Thai* 2006; 89: 1440-6.
- Srinualnad S, Nualyong C, Udompunterak S, Kongsuwan W. Endoscopic extraperitoneal radical prostatectomy (EERPE): a new approach for treatment of localized prostate cancer. *J Med Assoc Thai* 2006; 89: 1601-8.
- Walsh PC, Mostwin JL. Radical prostatectomy and cystoprostatectomy with preservation of potency. Results using a new nerve-sparing technique. *Br J Urol* 1984; 56: 694-7.
- Burkhard FC, Kessler TM, Fleischmann A, Thalmann GN, Schumacher M, Studer UE. Nerve sparing open radical retropubic prostatectomy - does it have an impact on urinary continence? *J Urol* 2006; 176: 189-95.
- Pasticier G, Rietbergen JB, Guillonneau B, Fromont G, Menon M, Vallancien G. Robotically assisted laparoscopic radical prostatectomy: feasibility study in men. *Eur Urol* 2001; 40: 70-4.
- Ward JF, Zincke H, Bergstralh EJ, Slezak JM, Myers RP, Blute ML. The impact of surgical approach (nerve bundle preservation versus wide local excision) on surgical margins and biochemical recurrence following radical prostatectomy. *J Urol* 2004; 172: 1328-32.
- Katz R, Salomon L, Hoznek A, de la TA, Antiphon P, Abbou CC. Positive surgical margins in laparoscopic radical prostatectomy: the impact of apical dissection, bladder neck remodeling and nerve preservation. *J Urol* 2003; 169: 2049-52.
- Palisaar RJ, Noldus J, Graefen M, Erbersdobler A, Haese A, Huland H. Influence of nerve-sparing (NS) procedure during radical prostatectomy (RP) on margin status and biochemical failure. *Eur Urol* 2005; 47: 176-84.
- Katz R, Salomon L, Hoznek A, de la TA, Vordos D, Cicco A, et al. Patient reported sexual function following laparoscopic radical prostatectomy. *J Urol* 2002; 168: 2078-82.
- Su LM, Link RE, Bhayani SB, Sullivan W, Pavlovich CP. Nerve-sparing laparoscopic radical prostatectomy: replicating the open surgical technique. *Urology* 2004; 64: 123-7.
- Link RE, Su LM, Sullivan W, Bhayani SB, Pavlovich CP. Health related quality of life before and after laparoscopic radical prostatectomy. *J Urol* 2005; 173: 175-9.
- Curto F, Benijts J, Pansadoro A, Barmoshe S, Hoepffner JL, Mugnier C, et al. Nerve sparing laparoscopic radical prostatectomy: our technique. *Eur Urol* 2006; 49: 344-52.
- Kaul S, Savera A, Badani K, Fumo M, Bhandari A, Menon M. Functional outcomes and oncological efficacy of Vattikuti Institute prostatectomy with Veil of Aphrodite nerve-sparing: an analysis of 154 consecutive patients. *BJU Int* 2006; 97: 467-72.
- Savera AT, Kaul S, Badani K, Stark AT, Shah NL, Menon M. Robotic radical prostatectomy with the "Veil of Aphrodite" technique: histologic evidence

of enhanced nerve sparing. Eur Urol 2006; 49: 1065-73.  
16. Rogers CG, Su LM, Link RE, Sullivan W, Wagner

A, Pavlovich CP. Age stratified functional outcomes after laparoscopic radical prostatectomy. J Urol 2006; 176: 2448-52.

---

## การผ่าตัดส่องกล้องเพื่อรักษามะเร็งต่อมลูกหมากแบบเก็บเส้นประสาทควบคุมการแข็งตัวขององคชาติที่โรงพยาบาลศิริราช: รายงานผลการผ่าตัดระยะเริ่มแรก

สิทธิพร ศรีนวลนัด, ไชยรงค์ นวลยง

**ภูมิหลัง:** คุณภาพชีวิตหลังการผ่าตัดมะเร็งต่อมลูกหมากแบบส่องกล้องเป็นเรื่องที่อยู่ในความสนใจของผู้ป่วยโรคมะเร็งต่อมลูกหมากเป็นอย่างยิ่ง การผ่าตัดเพื่อเอาต่อมลูกหมากออกโดยการเก็บเส้นประสาทที่ควบคุมการแข็งตัวขององคชาติไว้สามารถทำให้ผู้ป่วยมีคุณภาพชีวิตที่ดีขึ้นโดยเฉพาะอย่างยิ่งการแข็งตัวขององคชาติ และการควบคุมการปัสสาวะหลังการผ่าตัดได้ดีกว่าเมื่อเทียบกับผู้ป่วยที่ได้รับการผ่าตัดเพื่อเอามะเร็งต่อมลูกหมากออกโดยไม่ได้เก็บเส้นประสาทที่เลี้ยงองคชาติเอาไว้ ผู้เขียนได้รายงานทางการศึกษาของการผ่าตัดมะเร็งต่อมลูกหมากแบบส่องกล้องไปแล้ว และปัจจุบันได้พัฒนาวิธีการผ่าตัดมะเร็งต่อมลูกหมากแบบส่องกล้องโดยสามารถเก็บเส้นประสาทที่เลี้ยงองคชาติที่ควบคุมการแข็งตัวขององคชาติได้

**วัตถุประสงค์:** ศึกษาถึงความเหมาะสม และผลการผ่าตัดมะเร็งต่อมลูกหมากโดยการส่องกล้องแบบเก็บเส้นประสาทที่เลี้ยงองคชาติเพื่อควบคุมการแข็งตัวของอวัยวะเพศ

**วัสดุและวิธีการ:** ระหว่างเดือนธันวาคม พ.ศ. 2548 – เดือนสิงหาคม พ.ศ. 2549 ผู้ป่วยมะเร็งต่อมลูกหมากระยะเริ่มต้นจำนวน 28 คน เข้ารับการผ่าตัดมะเร็งต่อมลูกหมากโดยการส่องกล้องแบบเก็บเส้นประสาทที่ควบคุมการแข็งตัวขององคชาติ ผลของการผ่าตัดได้นำมาศึกษาเปรียบเทียบกับผู้ป่วยมะเร็งต่อมลูกหมากระยะเริ่มต้น จำนวน 34 คน ซึ่งเข้ารับการผ่าตัดมะเร็งต่อมลูกหมากโดยใช้กล้องแบบไม่เก็บเส้นประสาทที่ควบคุมการแข็งตัวขององคชาติ โดยผู้ป่วยทั้งหมดมีค่า PSA < 10 และมีค่า gleason score  $\leq 7$  นอกจากนี้ การศึกษายังรวมถึงคุณภาพชีวิตของการกลั่นปัสสาวะและการแข็งตัวขององคชาติภายในระยะเวลาหลังจากการผ่าตัดใหม่ร่วมด้วย

**ผลการศึกษา:** ข้อมูลพื้นฐานของผู้ป่วยไม่มีความแตกต่างกันในผู้ป่วยทั้งสองกลุ่ม ยกเว้นอายุ ระยะเวลาของการผ่าตัดใกล้เคียงกัน (คนละ 217 นาที และ 212 นาที) โดยที่ผู้ป่วยที่ทำการผ่าตัดแบบเก็บเส้นประสาทมีระยะเวลาการผ่าตัดสั้นกว่าเล็กน้อย, พบว่ามีจำนวนของเลือดที่สูญเสียระหว่างการผ่าตัดในปริมาณมากกว่า (814 ซีซี เทียบกับ 543 ซีซี, ค่า p อยู่ที่ 0.01) การควบคุมการเอามะเร็งออกจากผู้ป่วยทั้งสองกลุ่มใกล้เคียงกัน ที่ระยะเวลา 3 เดือนหลังผ่าตัดการกลั่นปัสสาวะในผู้ป่วยทั้งสองกลุ่มมีอัตราเสี่ยงไม่แตกต่างกัน พบว่าจำนวน 43.75% ของผู้ป่วยที่ได้รับการผ่าตัดแบบเก็บเส้นประสาทสามารถมีการแข็งตัวของอวัยวะเพศได้ใน 3 เดือนหลังจากการผ่าตัด

**สรุป:** ผลจากการศึกษาบ่งชี้ว่าการผ่าตัดมะเร็งต่อมลูกหมากโดยการส่องกล้องแบบเก็บเส้นประสาทนั้น ไม่ได้มีผลกระทบต่อการเอามะเร็งออกจากร่างกายผู้ป่วยแต่อย่างใด ถึงแม้ว่าผู้ป่วยจะมีการสูญเสียเลือดมากกว่าก็ตาม และการผ่าตัดดังกล่าวควรได้รับการส่งเสริมในผู้ป่วยที่พบมะเร็งต่อมลูกหมากในระยะเริ่มต้น ทั้งนี้เพราะผู้ป่วยสามารถได้รับประโยชน์ ของการผ่าตัดดังกล่าวโดยคุณภาพชีวิตหลังการผ่าตัดดีขึ้นกว่าผู้ป่วยที่ได้รับการผ่าตัดโดยการไม่เก็บเส้นประสาท